

anatomy hand-out

# NEUROANATOMY

(GROSS MORPHOLOGY & TRACTOLOGY)

BY

DR. SAMEH DOSS (Ph.D)

PROFESSOR OF ANATOMY

FACULTY OF MEDICINE, CAIRO UNIVERSITY

NATIONAL LIBRARY LEGAL DEPOSIT

No. 8048 / 1991

I.S.B.N. 977-00-2207-1



# Index of Contents

## \* Morphology of the C.N.S:

(1) Spinal Cord	1-5
(2) Morphological subdivisions of the brain	6
(3) Medulla oblongata	7-8
(4) PONS	8-9
(5) Midbrain	9-11
(6) Interpeduncular fossa	11-12
(7) Ant. & post. perforated substances	12
(8) Fourth Ventricle	13-14
(9) Cerebellum	15-17
(10) Cerebrum	18-31
(11) Basal ganglia	32-33
(12) Lateral Ventricle	34-36
(13) Diencephalon	37-40
(14) Third Ventricle	41-42
(15) Superficial attachment of the cranial nerves	43-44
(16) Arterial Supply of the brain	45-52
(17) Venous drainage of the brain	53-54
(18) Meninges of the brain	55-56
(19) Cerebro-spinal fluid	57

## \* Internal Structure & Tractology:

(1) Internal structure of spinal cord, tracts, afferent & efferent pathways	58-71
(2) Internal structure of the medulla	72-73
(3) Internal structure of the pons & the 4 lemnisci	74-76
(4) Internal structure of the midbrain & the med. longitudinal bundle	77-82
(5) Reticular formation of the brain stem	82
(6) Internal structure of the cerebellum & cerebellar peduncles	83-85
(7) Internal structure of the cerebral hemisphere & types of its fibres	86-93
(8) Internal Capsule	94-95
(9) Internal structure of the basal ganglia & the limbic system	96-97
(10) Internal structure of the diencephalon	98-100

- 1) Tract: is a group of nerve fibres inside the C.N.S having the same origin, the same course, the same termination and the same function.
- 2) Bundle or fasciculus: a group of nerve fibres inside the C.N.S having the different origins, terminations & functions.
- 3) Peduncle: a thick bundle supporting part of the brain (e.g cerebral peduncles & cerebellar peduncles).
- 4) Nucleus: a group of nerve cells inside the C.N.S lying very close to each other and having the same function (e.g nuclei of cranial nerves).
- 5) Ganglion: a group of nerve cells outside the C.N.S, in relation to sensory or autonomic nerves, (e.g sensory ganglia of the cranial nerves, dorsal root ganglia of the spinal nerves, sympathetic & parasymp. gang).
- 6) Synapse or relay: is the region of contact of the axon of one neurone & the dendrites or the cell body of another neurone.
- 7) Pathway: a series of neurones transmitting impulses inside or outside the C.N.S.
- 8) Commissure: a band of grey matter or white matter connecting a part of the C.N.S on one side with the same part on the opposite side.
- 9) Decussation: the criss-crossing of 2 fellow tracts in the middle line.
- Lemniscus: a band of ascending sensory fibres in the brain stem. It begins from a decussation below, & ascends to end in the thalamus above.
- Exteroceptive sensation: sensations from the skin (pain, touch & temperature).
- Proprioceptive sensation: sensations from muscles, ligaments, joints & fascia (sense of position, passive movements & vibrations).
- Ipsilateral: of the same side of the body.
- Contra-lateral: of the opposite side of the body.



# The Spinal Cord

It is the part of the C.N.S enclosed inside the vertebral column.

\* Shape: Compressed cylindrical column.

\* site & extent: it occupies the upper part of the vertebral canal being 25 cm shorter than the length of the v. column in the adult.

\* Length: about 45 cm in the adult.

\* Beginning: at the F. magnum as a downward continuation of the medulla oblongata

\* Termination:

(1) at the 3rd month of intrauterine life: the spinal cord fills the whole vertebral canal.

(2) at birth: it ends at the level of L3

(3) in the adult: it ends at the level of lower border of L1. Below this level, the vertebral canal contains

the lumbar, sacral & coccygeal nerves which form a bundle called Cauda Equina.

N.B: the lower end of the spinal cord shows a tapering conical extremity called Conus Medullaris.

\* Enlargements: the spinal cord presents 2 enlargements:

(1) Cervical enlargement: opposite the lower cervical vertebrae (Corresponding to the region from which the brachial plexus arises).

(2) Lumbar enlargement: opposite the lower thoracic vertebrae (Corresponding to the region from which the lumbar & sacral plexuses arise).

\* Coverings of the Spinal cord:

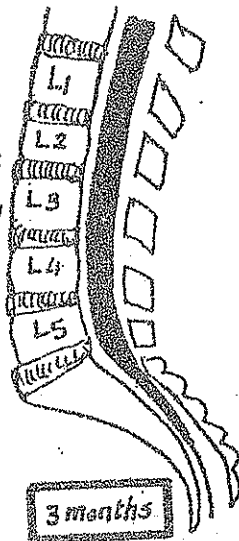
the spinal cord is covered by 3 membranes (meninges), from inside

outwards they are:

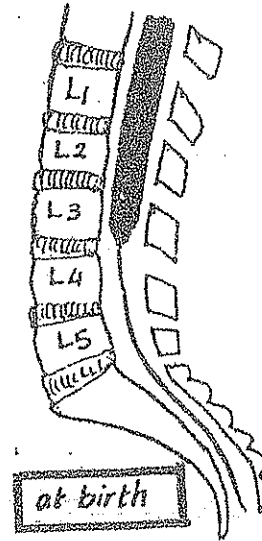
- (1) pia mater.
- (2) arachnoid mater.
- (3) dura mater.

(1) The Pia mater:

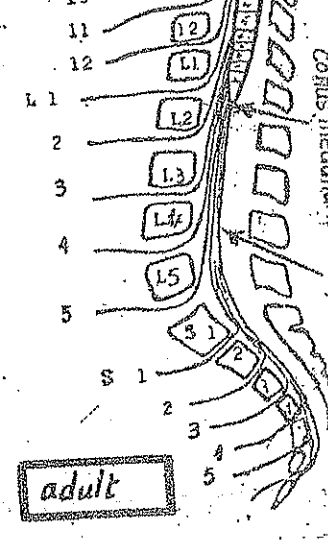
- it is closely adherent to the spinal cord.



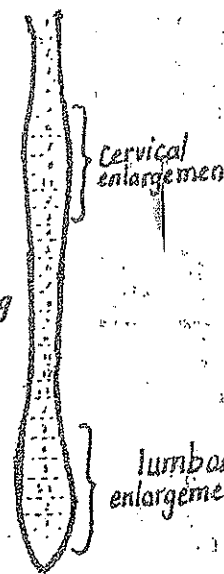
3 months



at birth

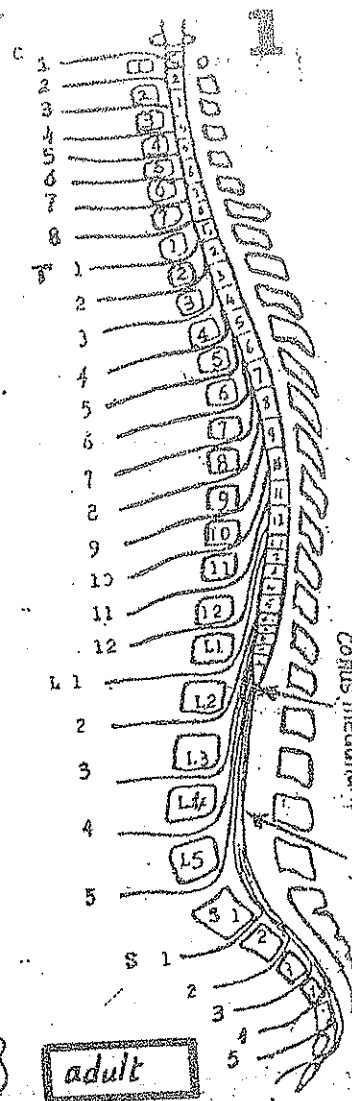


adult

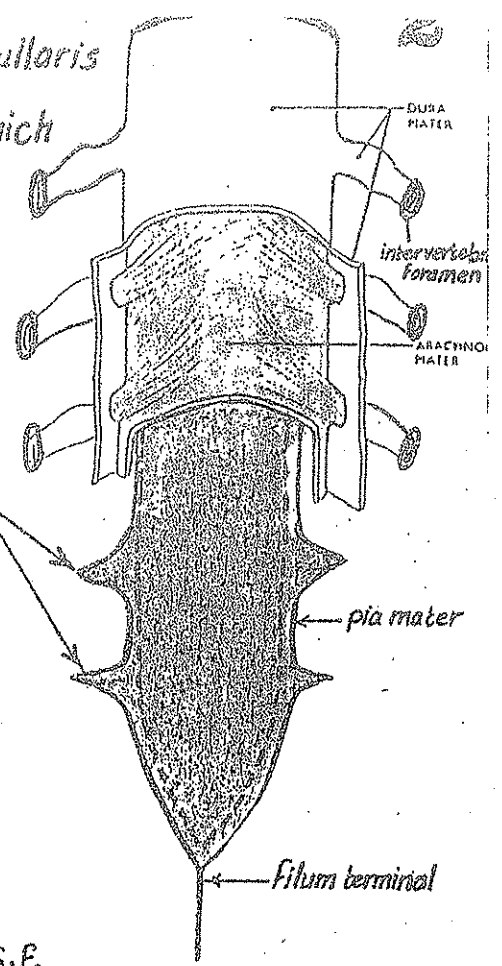


Cervical enlargement

lumbar enlargement



- the pia mater ends below, at the apex of the Conus medullaris by forming a glistening thread called the Filum terminal which descends among the nerves of the Cauda equina, pierces the arachnoid & dura at the level of S<sub>2</sub> vertebra then emerges from the sacral hiatus to be attached to the back of the Coccyx. The pia mater is thickened on either side to form serrated lat. extensions called the denticulate ligaments which pass laterally to attach the spinal cord to the dura mater.

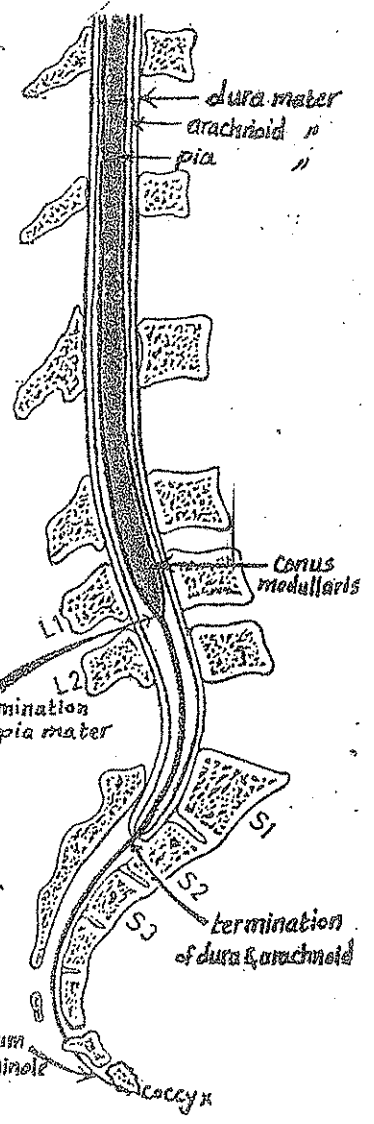


## 2) The Arachnoid mater:

- Continuous above with the arachnoid mater of the brain
- ends below at the level of S<sub>2</sub> Vertebra.
- it lines the inner surface of the dura mater & is separated from the pia mater by the Subarachnoid space containing C.S.F.

## (3) The Dura mater:

- Continuous above with the dura of the Cranial cavity & is attached to the margins of the foramen magnum.
- It ends below at the level of S<sub>2</sub> vertebra (like the arachnoid mater).
- it lines the vertebral canal & is attached on either side to the margins of the intervertebral foramina.



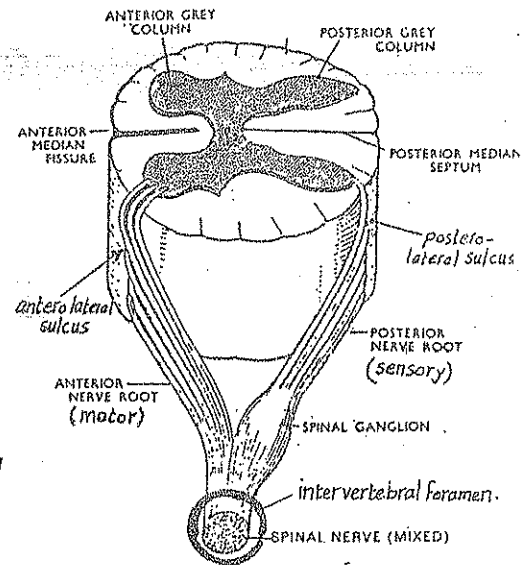
\* Fixation of the Spinal Cord: the spinal cord is fixed inside the vertebral canal by the following:

- 1) the Filum terminal which is attached to the back of Coccyx.
- 2) the denticulate ligaments of the pia mater which are attached to the dura mater. They lie between the ventral & dorsal roots of spinal nerves.
- 3) the dura mater which is attached above to the margins of the foramen magnum & on either side is attached to the intervertebral foramina & posteriorly it is attached to the post. longitudinal lig.

## \* External features of the Spinal Cord:

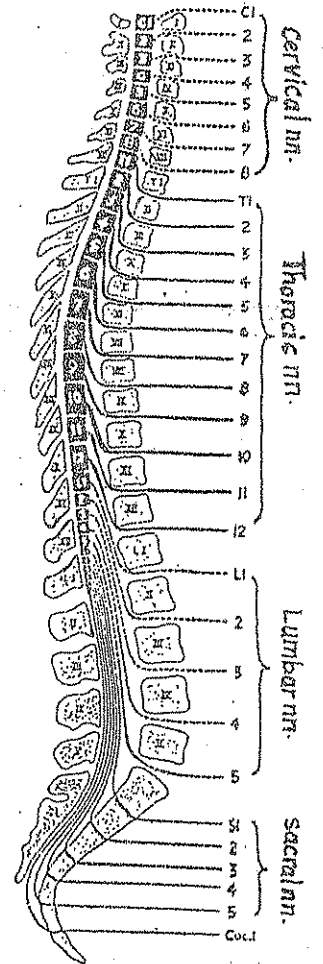
the outer surface of the S. cord shows the following :

- (1) an anterior median fissure or sulcus : a deep groove
- (2) posterior median septum : a thin neuroglial septum extending forwards from the pia mater covering the post. aspect of the spinal cord.
- (3) 2 posterolateral sulci (one on each side) : at the line of attachment (entrance) of the post. sensory roots of the spinal nerves to the spinal cord.
- (4) 2 anterolateral sulci (one on each side) along the line of emergence of the ant. motor roots of the spinal nerves from the spinal cord.



## \* The Spinal nerves:

- 31 pairs of spinal nerves are attached to the spinal cord :  
8 cervical , 12 thoracic , 5 lumbar , 5 sacral & one coccygeal nerve.
- Each spinal nerve is attached to the spinal cord by 2 roots :
  - (a) a dorsal root containing sensory fibres & carrying a spinal (sensory) ganglion.
  - (b) a ventral root containing motor fibres.
- The 2 roots unite at the intervertebral foramen to form the spinal nerve ( mixed sensory & motor).
- Each spinal nerve emerges from the intervertebral foramen.
- Immediately after leaving the inter vertebral foramen, each spinal nerve divides into anterior & posterior 1<sup>st</sup> rami, each of them is mixed (contains motor & sensory fibres). The ant. & post. 1<sup>st</sup> rami supply the ant. & post. aspects of the body respectively.



\* Internal Structure of the Spinal Cord : see page 58.

# Blood Supply of Spinal cord

## (A) Arterial Supply :

### (1) ant. spinal artery :

- formed inside the cranial cavity by the union of Rt. & Lt. ant. spinal arteries arising from the Rt & Lt. vertebral aa.
- It descends in front of the ant. median fissure of the spinal cord extending from the medulla above to the filum terminal below.

N.B : the ant. spinal a. is the longest artery in the body.

### (2) post. spinal arteries (Rt. & Lt.):

- each artery arises inside the cranial cavity from one vertebral artery.
- each artery divides into 2 branches which descend in front & behind the dorsal roots of the spinal nerves.

### (3) Radicular arteries :

- they enter the vertebral canal through the intervertebral foramina to supply the spinal cord segmentally.
- their origin differs according to the region as follows :

(a) in the cervical region: they arise from vertebral arteries

↑ ascending cervical a. ?  
(1+2) → sup. intercostal A

(b) " " thoracic region: they arise from the post. intercostal & subcostal

(3-11) → descending thoracic aorta

(c) " " lumbar region: " " " lumbar arteries.

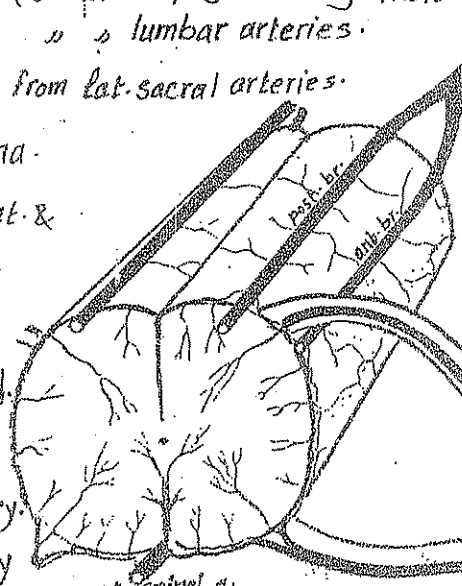
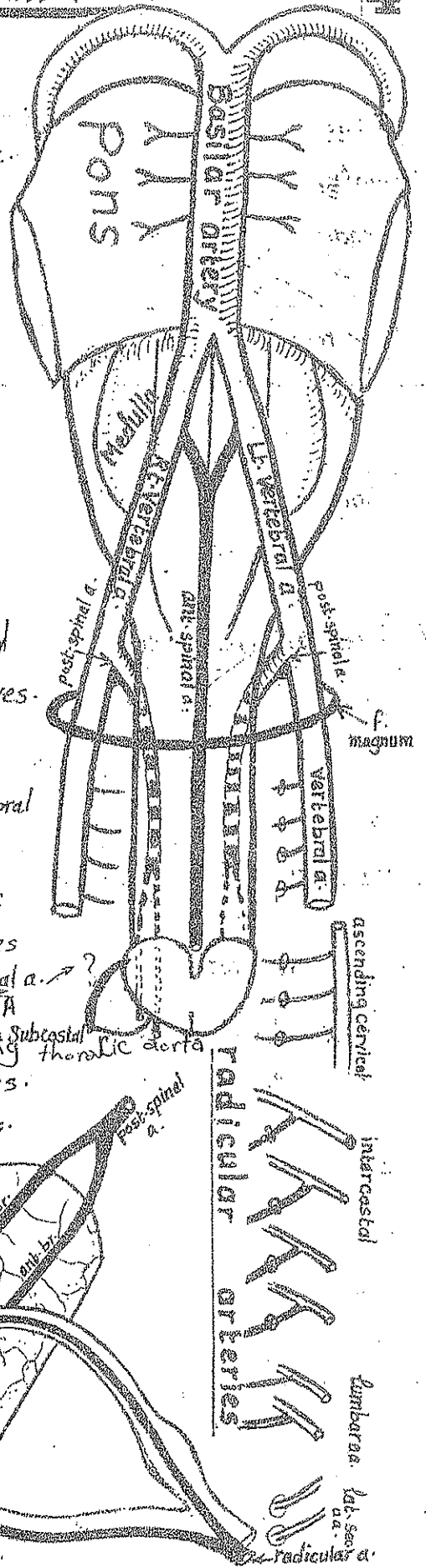
(d) " " Sacral " : " " from lat. sacral arteries.

and supply the cauda equina.

- each radicular a. divides into ant. & post. branches that accompany the ant. & post. roots of the spinal n. to reach the spinal cord.

### N.B Arteria Radicularis Magna :

- it arises from the 2<sup>nd</sup> lumbar artery.
- it is the largest radicular artery (as it supplies the lumbar enlargement of S. cord).



## (B) Venous drainage of the Spinal Cord:

\* the spinal cord is supplied by 6 longitudinal Veins:

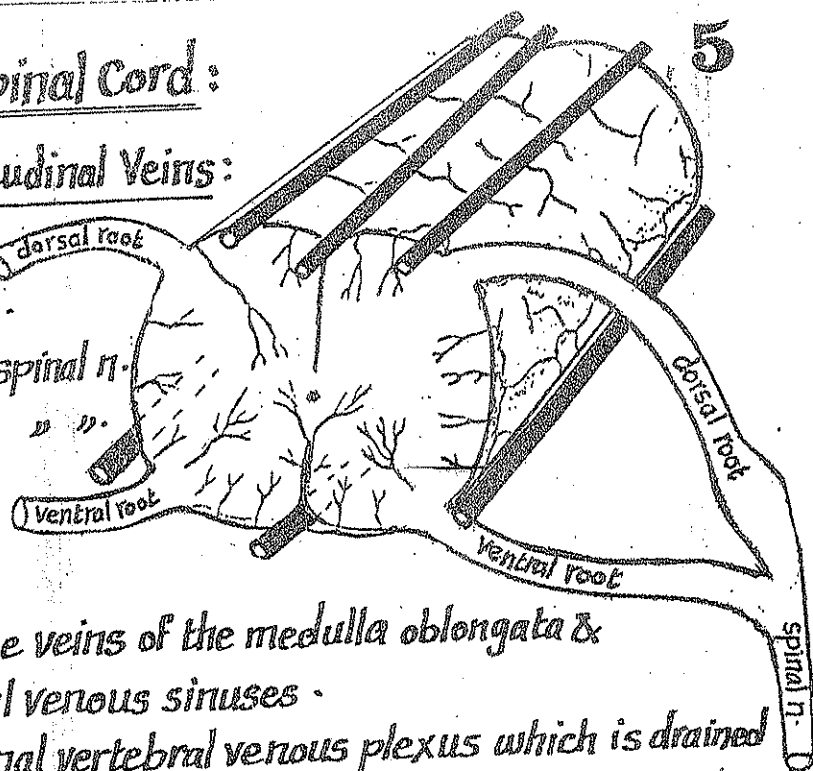
- one vein in the median plane anteriorly
- " " " " " " " " posteriorly.
- 2 veins, one behind each ventral root of spinal n.
- 2 " " " " " " " " dorsal " " " "

\* These 6 longitudinal veins are drained as follows:

(a) above: they are continuous with the veins of the medulla oblongata & communicate with the dural venous sinuses.

(b) laterally: they open into the internal vertebral venous plexus which is drained by intervertebral veins that emerge from the intervertebral foramina to end in:

- (1) the vertebral veins (in the neck).
- (2) the intercostal veins (in the thorax).
- (3) the lumbar veins (in the abdomen).
- (4) the lat. sacral veins (in the pelvis).



## Meningeal Spaces of the Spinal cord

(1) Extradural (Epidural) space:

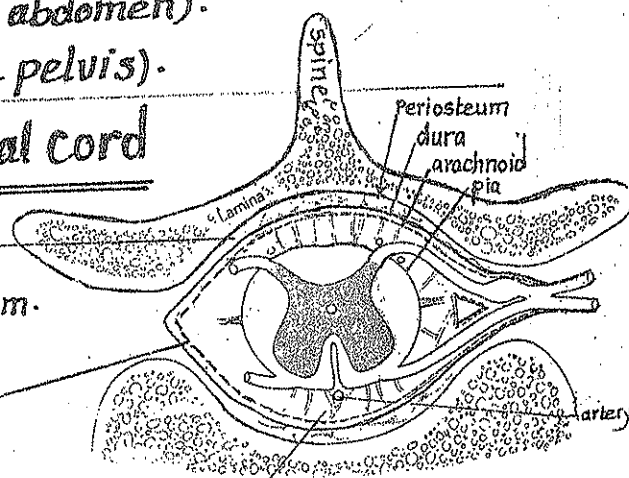
- it lies between the dura & the vertebral periosteum.
- it contains loose areolar tissue & the internal vertebral venous plexus.

(2) Subdural Space:

- it lies between the dura mater & the arachnoid mater.
- it contains thin film of fluid.

(3) subarachnoid Space:

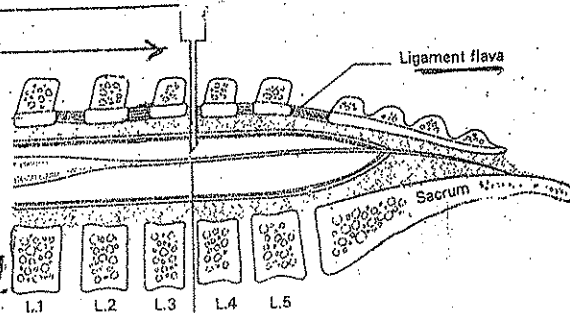
- it lies between the arachnoid mater & pia mater
- it contains: (a) cerebrospinal fluid (C-S-F) (b) the vessels of the spinal cord (c) roots of spinal nerves (d) fibrous tissue trabeculae.



## Lumbar puncture

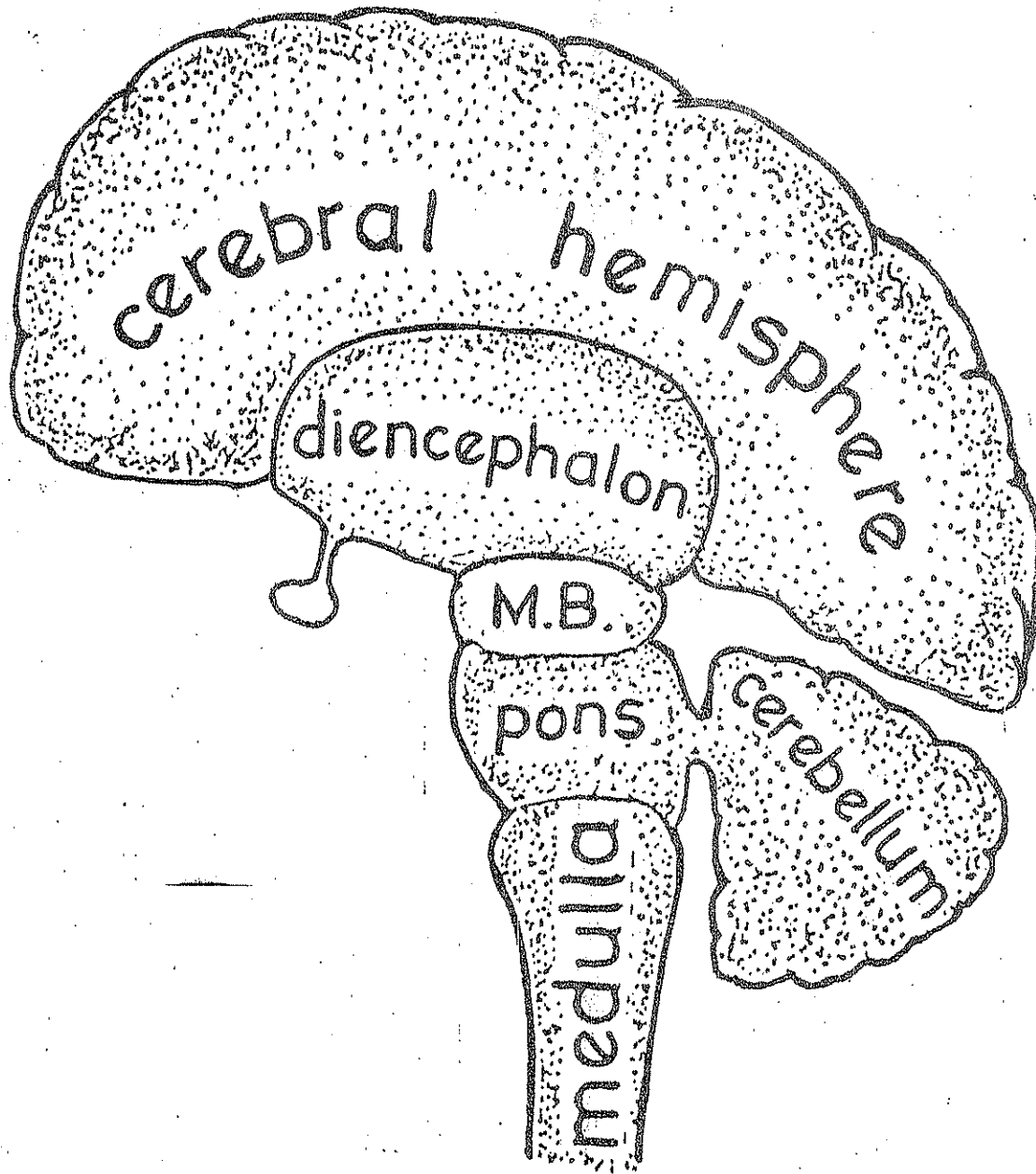
\* it is the process of introduction of a special needle into the subarachnoid space to get sample of C-SF or to make spinal anaesthesia.

\* site: between L3 & L4 to avoid injury of the spinal cord.



# The Brain

\* It is the part of the C.N.S enclosed inside the skull.



## Morphological Subdivisions

- (1) The cerebrum: the Rt. & Lt. Cerebral hemispheres.
- (2) The Cerebellum: below the post. part of the Cerebrum.
- (3) The brain stem: formed of the following parts (from below upwards):
  - (a) medulla oblongata
  - (b) pons
  - (c) Midbrain
  - (d) Diencephalon: (thalamus & related structures) lying inbetween the 2 Cerebral hemispheres.



# Medulla Oblongata

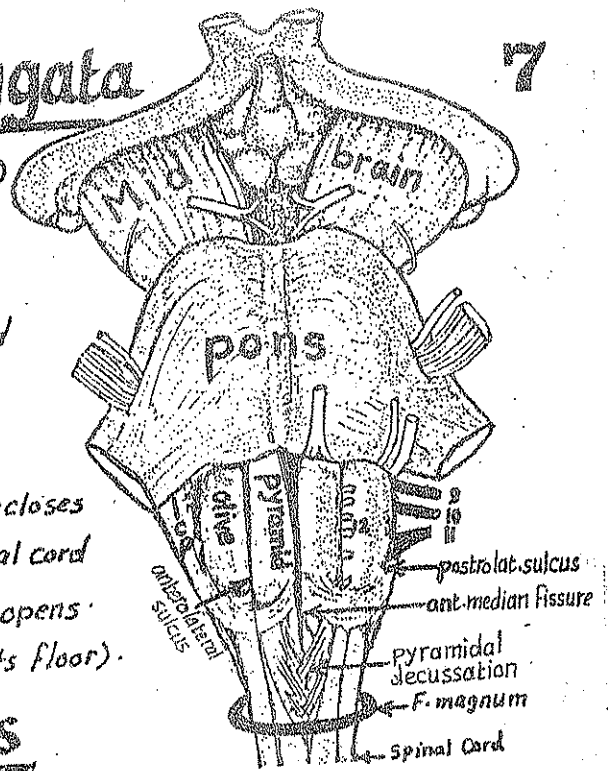
\* it is the lowest part of the brain stem (3cm)

## \* Extent:

- above: it is continuous with the pons
- below: " " " " the spinal cord at the foramen magnum.

## \* Parts:

- a - its lower 1/2 is called closed medulla as it encloses a central canal continuous with that of the spinal cord
- b - its upper 1/2 is called the open medulla as it opens into the 4th ventricle (forming the lower part of its floor).



## External features

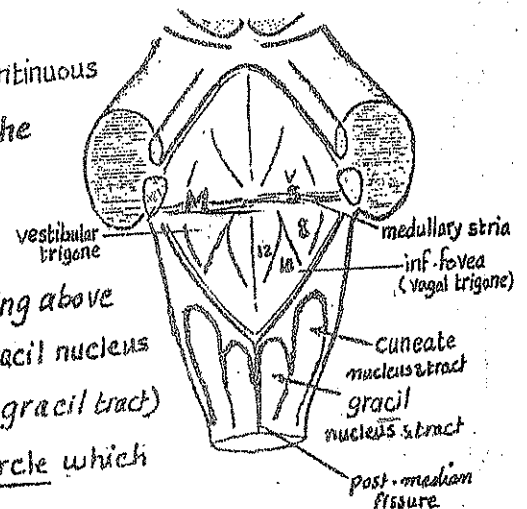
(A) Anterolateral Surface: presents the following features from medial to lateral:

- (1) Anterior median fissure: in the middle line. Its lower part is obliterated by the pyramidal (motor) decussation.
- (2) the Pyramid: an elongated elevation formed by the pyramidal (Corticospinal) tract.
- (3) the Olive: an oval elevation formed by the inferior olivary nucleus.
- (4) the anterolateral sulcus: a groove between the pyramid & olive giving exit to the rootlets of hypoglossal n.
- (5) the posterolateral sulcus: a groove between the olive & the inf. cerebellar peduncle giving exit to the glossopharyngeal, vagus & cranial accessory n. from above down wards.
- (6) the inferior cerebellar peduncle (I.C.P.): a rope-like bundle connecting the medulla with the cerebellum passing upwards & laterally.

## (B) the Posterior surface:

(1) the post. surface of the lower 1/2 (Closed medulla): is continuous with the post. surface of the spinal cord & presents the following features from medial to lateral:

- (a) Posterior median fissure:
- (b) Gracile tract: forming a longitudinal elevation ending above by an oval swelling called gracil tubercle (overlies gracil nucleus)
- (c) Cuneate tract: a longitudinal elevation (lat. to the gracil tract) ending above by oval swelling called cuneate tubercle which overlies the cuneate nucleus.



## (2) the post. surface of the upper 1/2 (open medulla):

8

\* forms the lower part of the floor of 4th ventricle & separated from the post. surface of the pons by transverse fibres called medullary stria.

\* It presents the following features from medial to lateral:

- (1) a median longitudinal fissure
- (2) an inverted V-shaped depression called the inferior fovea. the area between the 2 limbs of the V is called vagal trigone (overlies the dorsal nucleus of vagus)
- (3) hypoglossal trigone: medial to the inf. fovea (overlies hypoglossal nucleus)
- (4) vestibular " " " " " " " " ( " " inf. vestibular nucleus)

\* Blood Supply of medulla: branches from the vertebral a. directly & from its post. inf. cerebellar branch.

\* Internal structure: see page 72

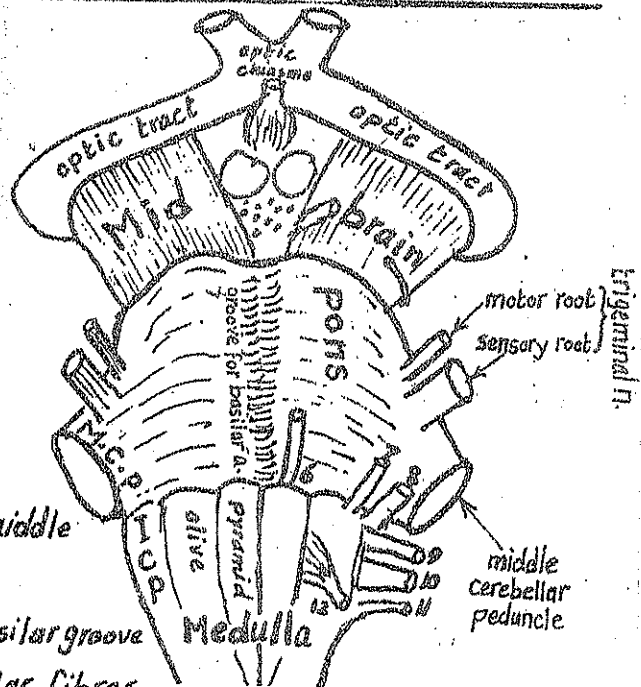
## II- Pons

\* Extent: It extends from the medulla oblongata below to the midbrain above & lies in front of the cerebellum.

### External Features

(A) Anterior surface: presents:

- (1) Basilar groove: longitudinal groove in the middle line for basilar a.
- (2) Transverse streaks: on each side of the basilar groove & produced by the transverse ponto cerebellar fibres that collect on either side to form the middle cerebellar peduncle
- (3) Trigeminal n.: arise by large sensory root & small motor root from the lat. part of the ant. surface of the pons (at its junction with the middle cerebellar peduncle).
- (4) Middle cerebellar peduncle (M.C.P.): a thick bundle formed of ponto-cerebellar fibres which collect at the lat. part of the pons. It turns backwards to sink into the corresponding cerebellar hemisphere.
- (5) the Abducent nerve: emerges from the lower border of the pons near the middle line (between the pons & the pyramid of the medulla).





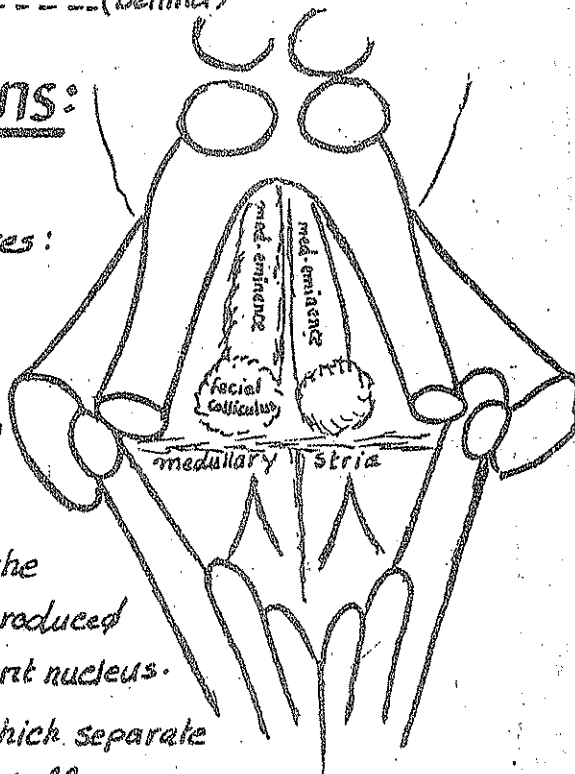
6) The facial (7) & Vestibulo-Cochlear(8) nerves emerge from the ponto-

cerebellar angle which is a triangular space between :

- (a) the lower border of the M. C. P. -----(above)
- (b) the upper border of medulla -----(below)
- (c) the Cerebellum -----(behind)

### (B) Posterior Surface of the Pons:

forms the upper part of the floor of 4<sup>th</sup> ventricle & presents the following features:



(1) Median longitudinal Sulcus: in the middle line.

(2) Medial eminence: a longitudinal elevation on either side of the median sulcus, produced by the abducent n. nucleus.

(3) Facial Colliculus: a rounded swelling on the lower part of the medial eminence. It is produced by the facial n. which encircles the abducent nucleus.

(4) Medullary Stria: transverse nerve fibres which separate the post. surface of pons from that of medulla.

\* Blood Supply of pons: pontine branches of basilar artery.

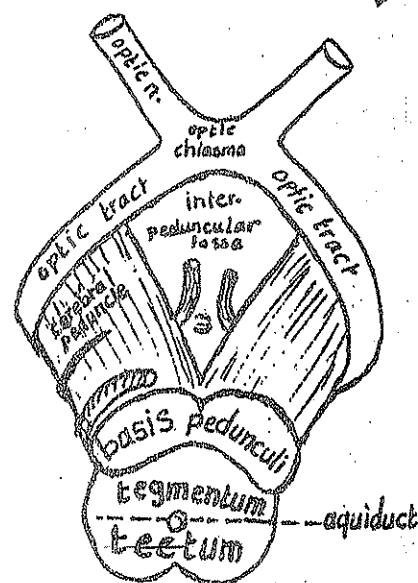
\* Internal Structure: see page 74

## III- Midbrain

\* Extent: it extends between the pons (below) and the diencephalon (above). It is the shortest part of the brain stem.

\* Site: it occupies the tentorial notch & is largely hidden by the lower parts of the cerebral hemispheres.

\* Connections: it connects the pons & cerebellum to the subthalamic region of the diencephalon.



\* Parts: in transverse section, the midbrain is formed of:

(1) tectum: posteriorly, behind the aqueduct of Sylvius.

(2) tegmentum: in the middle, in front of the » » »

(3) basis pedunculi: most anteriorly in front of the tegmentum.

# External features of the midbrain

10

The Midbrain has 4 surfaces : an anterior, a posterior & 2 lateral surfaces

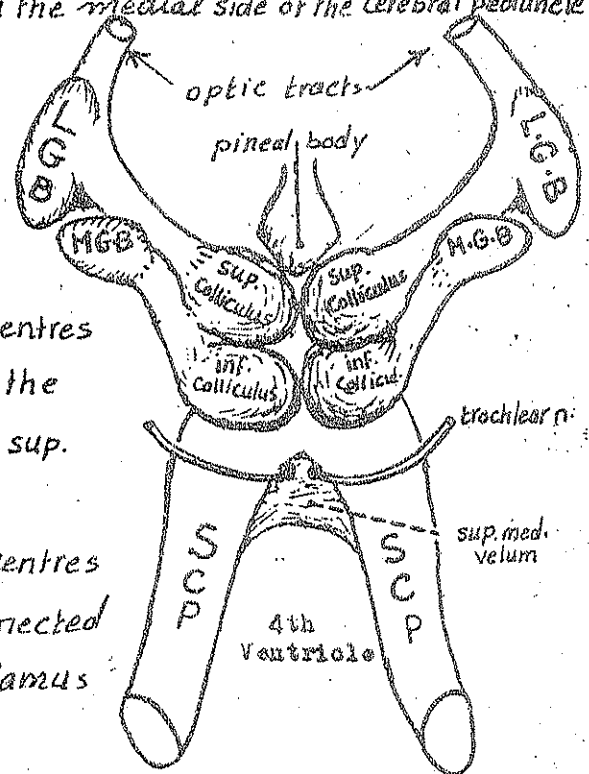
## (A) The anterior surface:

- (1) 2 Cerebral peduncles : 2 large rope-like bundles that emerge directly from the upper surface of the pons (below), ascend upwards diverging from each other (separated by the inter peduncular fossa) to disappear in the substance of the cerebral hemisphere (above). Each cerebral peduncle consists of 3 parts:
- (a) basis pedunculi anteriorly (formed by the fibres of the pyramidal tract).
  - (b) Substantia nigra in the middle (one of the extra-pyramidal nuclei).
  - (c) tegmentum posteriorly (contains nuclei & tracts of the mid brain).

(2) Oculomotor n.: emerging from the groove on the medial side of the cerebral peduncle.

## (B) The posterior surface: presents:

- (1) 4 rounded elevations or Colliculi (Corpora quadrigemina) which include:
- (a) 2 superior Colliculi : (above) : which are centres of visual reflexes. Each is connected to the lat. geniculate body (L.G.B) of thalamus by sup. brachium.
  - (b) 2 inferior Colliculi (below) : which are centres of auditory reflexes. Each of them is connected to the med. geniculate body (M.G.B) of thalamus by means of inferior brachium.



(2) the 4 colliculi are separated from each other by a cruciform sulcus.

(3) 2 sup. cerebellar peduncles (S.C.P) emerge from the post. surface of the midbrain & run downwards, backwards & laterally along the sides of the upper part of the 4<sup>th</sup> ventricle to enter the cerebellar hemispheres

(4) a membrane called sup. medullary velum stretches between the 2 sup. cerebellar peduncles.

(5) the trochlear n. emerges from the post. surface of the midbrain immediately below the inf. Colliculus piercing the sup. medullary velum to curve forwards around the lat. side of midbrain.

## C - The lateral surface of the midbrain: presents:

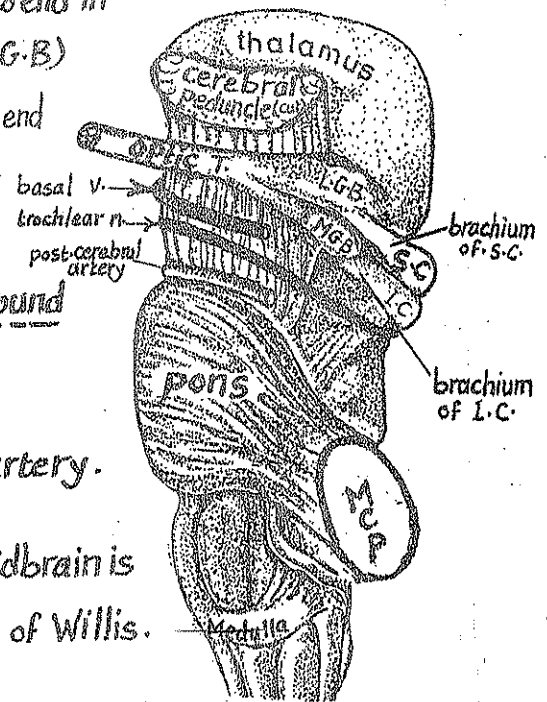
11

(1) brachium of sup. colliculus: passing upwards & forwards to end in the lat. geniculate body (L.G.B)

(2) brachium of inf. Colliculus: passing upwards & forwards to end in the med. geniculate body (M.G.B)

(3) In addition, the lat. surface of the midbrain is crossed by the following 4 structures which wind around the cerebral peduncle:

- |                      |                                |
|----------------------|--------------------------------|
| (a) the optic tract. | (b) the basal vein.            |
| (c) the trochlear n. | (d) the post. cerebral artery. |



\* Blood Supply of the midbrain: the midbrain is supplied by branches from the arteries forming the circle of Willis.

\* Internal Structure of the midbrain: see page 77.

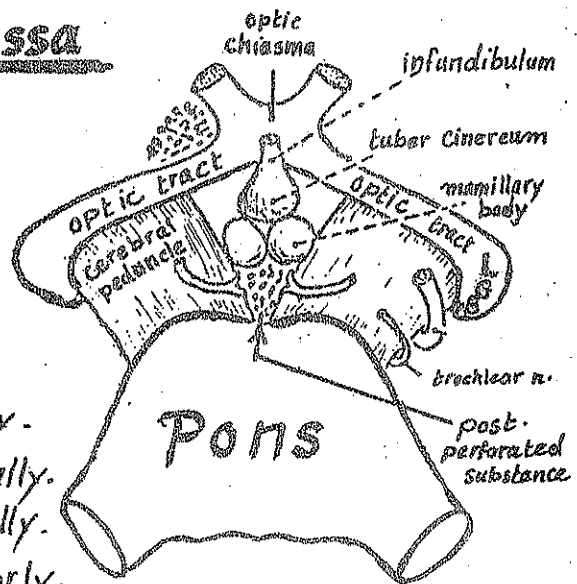
## Interpeduncular fossa

### \* Shape & site:

It is a rhomboidal-shaped space lying at the central region of the base of the brain.

### \* Boundaries:

- Optic chiasma ----- anteriorly.
- Optic tracts ----- antero-laterally.
- Cerebral peduncles ----- postero-laterally.
- Upper border of pons ----- Posteriorly.



### \* Contents:

- The tuber cinereum: an elevated area in the ant. part of the fossa Just behind the optic chiasma.
- The Infundibulum: a stalk connecting the tuber cinereum with the pituitary gland (below).
- 2 mamillary bodies: (2 small rounded elevations):

- \* they lie one on each side of the middle line in the post. part of the fossa.
- \* they receive afferent fibres via the columns of the fornix.
- \* they send efferent to the thalamus (mammillo-thalamic tract).

and to the tegmentum of the midbrain (mamillo-tegmental tract).

\* they form part of the hypothalamus & are probably concerned with the visceral sensations.

### (4) The posterior perforated substance:

\* It lies in the post. part of the interpeduncular fossa behind the 2 mamillary bodies in the angle between the 2 cerebral peduncles.

\* It is perforated by the central branches of the post. cerebral artery which supply the thalamus.

\* the post. perforated substance constitute a part of the hypothalamus.

### (5) The Oculomotor nerves: emerge from the post. part of the interpeduncular fossa.

Each nerve is attached to the groove just medial to the cerebral peduncle.

N.B: the tuber cinereum, infundibulum, mamillary bodies & post. perforated substance are parts of the hypothalamus.

### \* Relations of the interpeduncular fossa:

(1) The circle of Willis overlies the fossa.

(2) The 3rd ventricle lies above it.

(3) The pituitary gland lies below it.

(4) The anterior perforated substance lies anterolateral to it.

### Anterior perforated substance

\* Definition: it is an area in the base of each cerebral hemisphere which is perforated by the central branches of the anterior & middle cerebral arteries.

\* site: it lies behind the olfactory trigone & the diverging med. & lat. olfactory stria.

#### \* Relations:

- anteriorly: olfactory trigone & the 2 olfactory stria.

- posteriorly: uncus of the temporal lobe

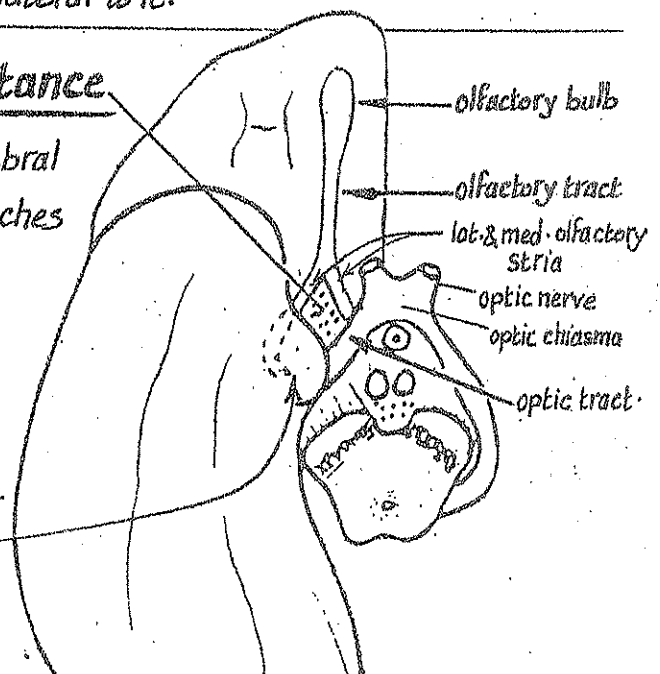
- medially: optic tract & optic chiasma.

- laterally: stem of the lat. sulcus

- above: it is continuous with the grey matter of the corpus striatum (head of caudate nucleus).

- below: it is related to the termination of the internal carotid artery & the beginning of the ant. & middle cerebral arteries.

\* Function: it constitutes a part of the limbic system (see tractology).



# The Fourth Ventricle

- It is the Cavity of the hind brain.

\* Position : It lies between:

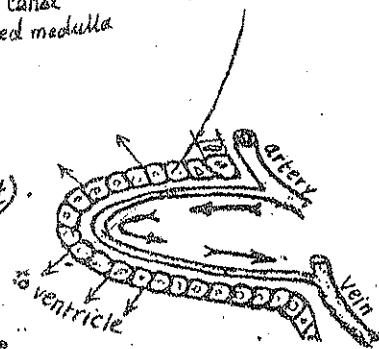
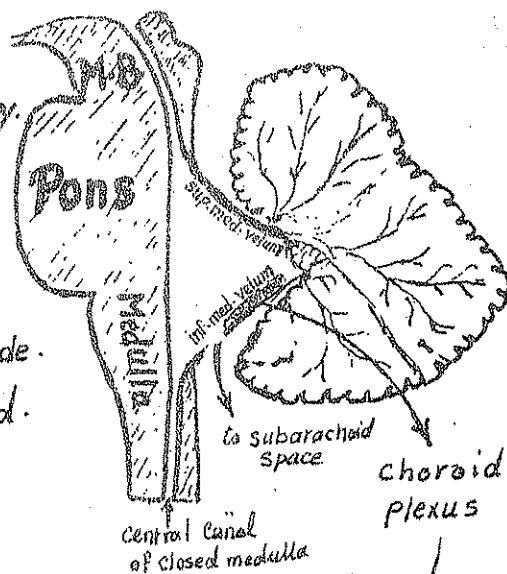
- (a) the pons & upper part of medulla anteriorly.
- & (b) the Cerebellum posteriorly.

\* Shape:

- \* It is tent-shaped when seen from the side.
- & \* diamond-shaped when seen from behind.

\* It has:

- \* A Floor (anteriorly).
- \* A Roof (posteriorly).
- \* 4 lateral boundaries (Where the roof & the floor meet).
- \* 4 angles (sup., inf., & 2 lat. angles).



## I- Boundaries of the 4th Ventricle:

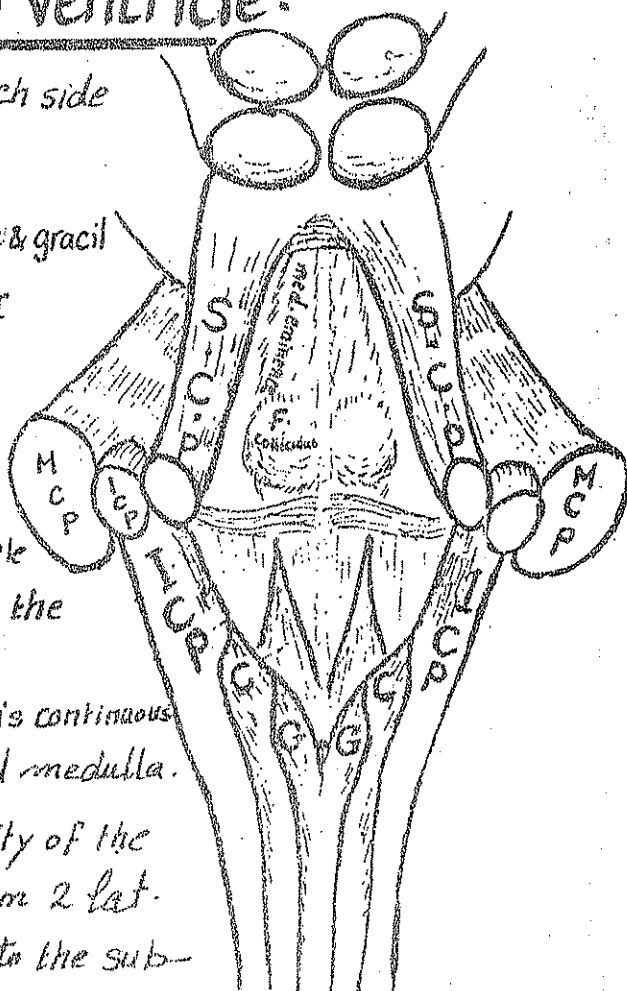
- (1) the sup. cerebellar peduncle on each side forms the upper lat boundary.
- (2) the inf. cerebellar peduncle, Cuneate & gracil tubercles (on each side) form the lower lateral boundary.

## II- Angles of the Ventricle:

superior angle where the 4th ventricle is continuous with the aqueduct of the midbrain.

Inferior angle: where the 4th vent. is continuous with the central canal of the closed medulla.

Two lateral angles where the cavity of the ventricle is pulled laterally to form 2 lat. recesses. Each lat. recess opens into the subarachnoid space.



### III The Floor of the 4<sup>th</sup> Ventricle:

14

- \* It is diamond shaped in outline.
- \* It is formed above by the post. surface of the pons & below by the post. surface of the upper part of medulla (open medulla).
- \* the floor is subdivided into Rt & Lt. identical halves by the median sulcus
- \* It is crossed in the middle by transverse fibres called medullary stria which divide the floor of the ventricle into:  
(a) an upper (pontine) part (b) a lower (medullary) part.

#### (A) the upper pontine part presents:

- (1) median sulcus
  - (2) medial eminence
  - (3) Facial colliculus
  - (4) Superior fovea
- } describe in detail as in Page ..... 9

#### (B) the lower medullary part presents:

- (1) median sulcus.
  - (2) the inferior fovea (Vagal trigone).
  - (3) vestibular trigone.
  - (4) hypoglossal trigone.
- } describe in detail as in Page 7

### IV - The Roof of the 4<sup>th</sup> Ventricle:

- (1) Its upper part is formed by the medial borders of the 2 superior cerebellar peduncles & the sup. medullary velum (a sheet of white matter stretching between the 2 sup. cerebellar peduncles).
- (2) Its middle part is formed by the inf. vermis of the cerebellum.
- (3) its lower part is formed by the inf. medullary velum connecting the 2 inf. cerebellar peduncles & is invaginated by choroid plexus (secreting C.S.F.)

#### \* Openings of the 4<sup>th</sup> Ventricle:

- (1) Median aperture (foramen of Magendi) in the lower part of the inferior medullary velum.
  - (2) 2 Lateral apertures (foramina of Luschka): one in each lat. recess.
- N.B.: through these 3 apertures, the C.S.F. leaves the 4<sup>th</sup> ventricle to the subarachnoid space.



# The Cerebellum

15

\* Embryological origin: it is the largest part of the hindbrain.

\* Site: occupies most of the post. cranial

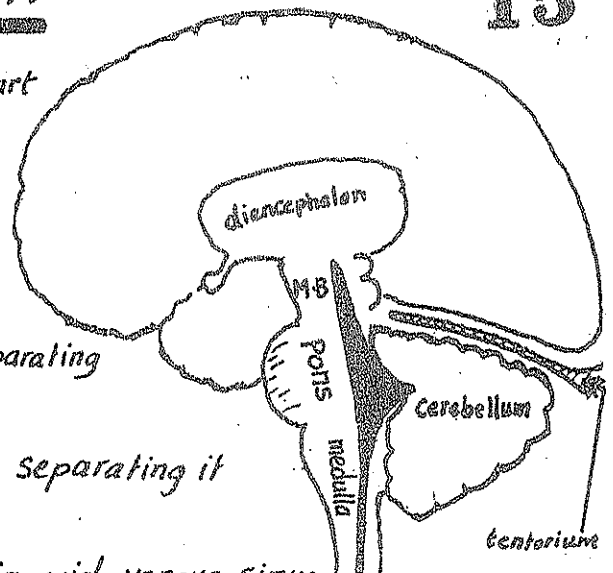
Fossa

\* Relations:

(1) superiorly: the tentorium cerebelli, separating it from the cerebral hemispheres.

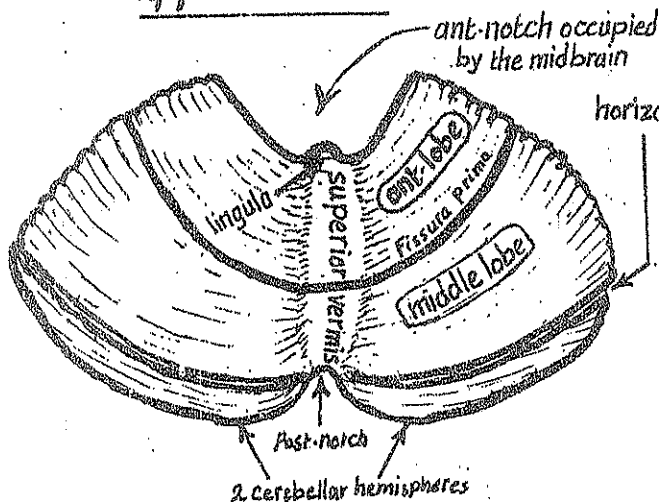
(2) anteriorly: the cavity of 4<sup>th</sup> ventricle separating it from pons & medulla.

(3) on each side: it is related to the sigmoid venous sinus, mastoid antrum & mastoid air cells.

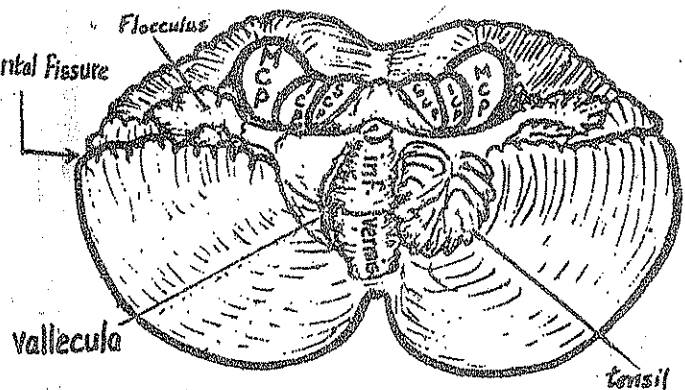


\* Shape, Surfaces & Parts:

upper surface



lower surface



\* The cerebellum is globular in shape & formed of 2 cerebellar hemispheres connected by a median vermis. The cerebellum has:

(1) post. notch: occupied by the falx cerebelli.

(2) ant. notch: wider, & lodging the midbrain, pons & medulla.

(3) upper surface: flattened, lies under the tentorium cerebelli & presents:

(a) sup. vermis: indistinct & sloping into the hemispheres.

(b) lingula: prolonged from the sup. vermis on sup. medullary velum.

(c) fissura prima: the main fissure between the ant. & middle lobes

(4) lower surface: rounded on each side & presents:

(a) vallecula: a deep groove between the 2 hemispheres occupied by the inf. vermis.

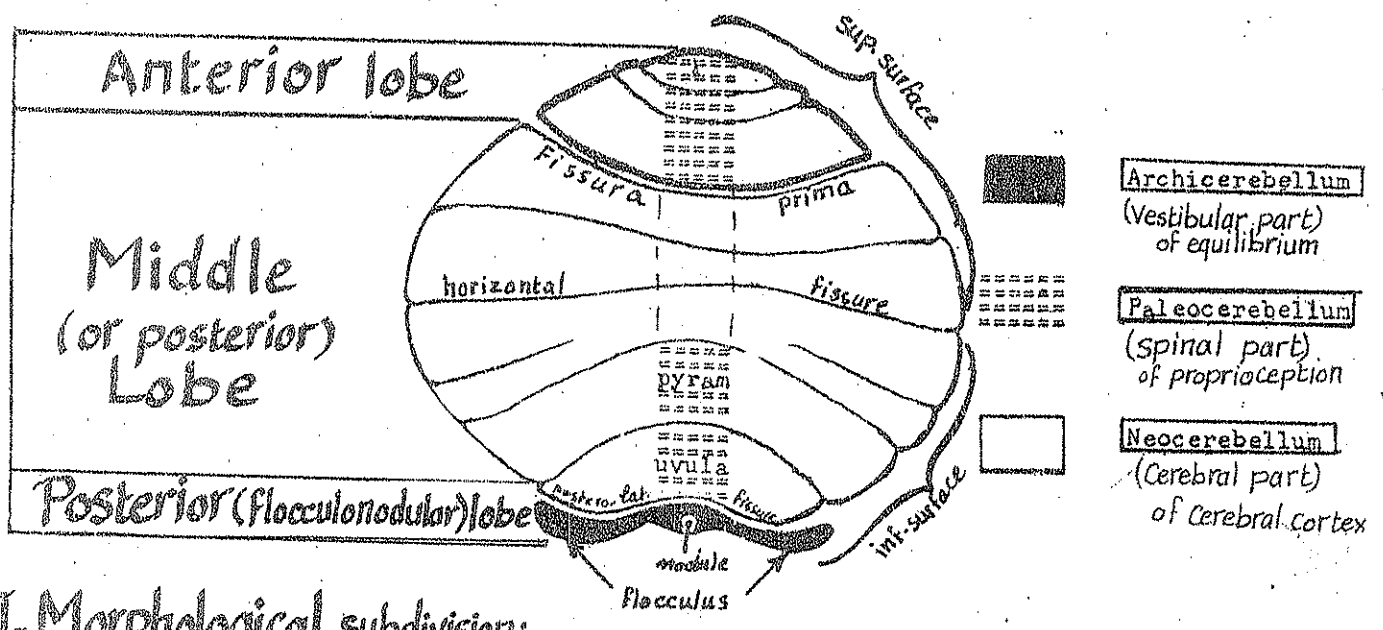
(b) inf. vermis : well distinct worm-like structure between the 2 cerebellar hemispheres in the bottom of the vallecula.

(c) tonsil : one on either side of the inf. vermis.

(d) flocculus & para flocculus : behind the middle cerebellar peduncle.

(e) horizontal fissure : separates the inf. & post. surfaces & extending from the ant. to the post. notch.

**\* Subdivisions of the Cerebellum:**



I- Morphological subdivision: 2 cerebellar hemispheres connected by median vermis.

II- True anatomical subdivision:

- (1) ant lobe : in front of the fissura prima.
- (2) middle (or posterior) lobe : the major part of the cerebellum, from the fissura prima to the posterolat. sulcus.
- (3) posterior (or flocculonodular) lobe formed of 2 flocculi (one on each side) & a nodule in the middle.

III- Functional Subdivision:

(A) Vestibular part or archicerebellum:

- \* it is formed of the flocculonodular lobe.
- \* developmentally, it is the oldest part of the cerebellum.
- \* It receives afferent impulses from the vestibular apparatus of the internal ear (utricle, saccule & semicircular canals) via the direct & indirect vestibulo-cerebellar tracts.
- \* It is concerned with equilibrium.



## (B) Spinal Part or Paleocerebellum (Cerebellum of proprioception) 17

- \* It is formed of : the vermis of the ant. lobe + the uvula & pyramid which are the ant. parts of the inf. vermis.
- \* It receives afferent proprioceptive impulses from muscles & tendons via the spino-cerebellar tracts (dorsal & ventral) mainly & also by dorsal & ventral external arcuate fibres.
- \* It is concerned with muscle tone.

## (C) Cerebral part or neo-cerebellum (Cerebellum of cerebral cortex):

- \* it is the remaining largest part of the cerebellum.
- \* it includes the 2 cerebellar hemispheres + the middle part of the vermis.
- \* It receives afferent impulses from the cerebral cortex via ponto cerebellar tracts (Cerebro-ponto-cerebellar pathway).

\* Internal structure of cerebellum : see page 83.

\* Cerebellar connections (Peduncles) : see page 83.

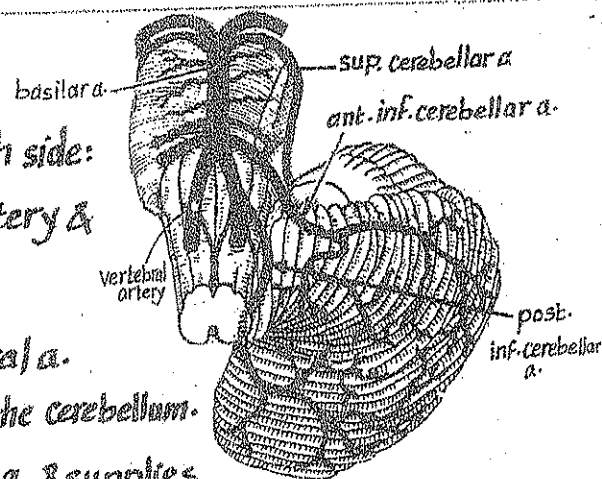
## \* Blood supply of the cerebellum:

the cerebellum is supplied by 3 arteries on each side:

(1) superior cerebellar a. : arises from the basilar artery & supplies the sup. surface of the cerebellum.

(2) post. inf. cerebellar a. : arises from the vertebral a. & supplies the post. part of the inf. surface of the cerebellum.

(3) ant. inf. cerebellar a. : arises from the basilar a. & supplies the ant. part of the inf. surface of the cerebellum.



## \* Functions of the Cerebellum:

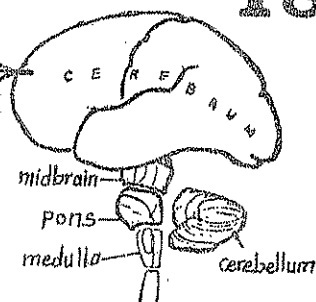
each cerebellar hemisphere influences the muscular activity of the ipsilateral 1/2 of the body

- (1) It coordinates the action of the different groups of muscles, so that the movements are done smoothly & accurately. This is chiefly done by the neo-cerebellum.
- (2) it controls the muscle tone, posture & equilibrium of the body. This is chiefly done by the archicerebellum & paleocerebellum.

# The Cerebrum

18

- \* It is the upper & largest part of the brain.
- \* It is divided incompletely into Rt. & Lt. Cerebral hemispheres by the median longitudinal Cerebral fissure.
- \* At the floor of this fissure, a mass of white matter called the Corpus Callosum unites the 2 Cerebral hemispheres together.

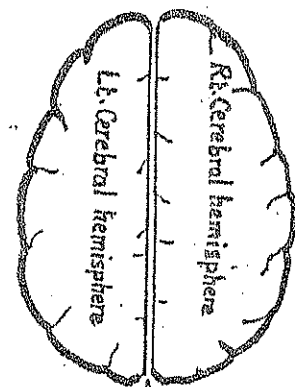


## The Cerebral hemispheres

\* Site: they occupy the ant., the middle & the upper part of the post. Cranial fossae.

### \* Relations:

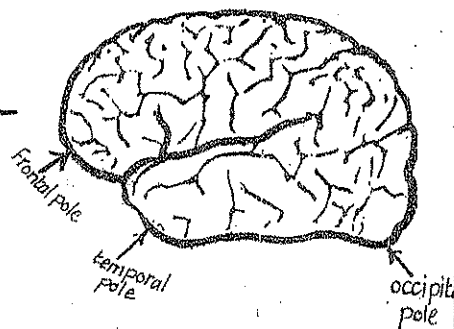
- (1) the 2 Cerebral hemispheres are separated from each other by a sickle-shaped fold of dura called the falx Cerebri which occupies the median longitudinal Cerebral fissure.
- (2) the 2 Cerebral hemispheres are separated from the Cerebellum by a horizontal fold of dura called the tentorium Cerebelli



\* Surfaces: each cerebral hemisphere has 3 surfaces:

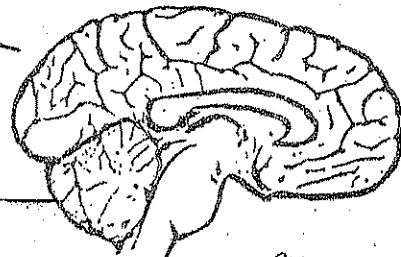
### (1) Lateral (supero-lateral) Surface:

is convex, directed upwards & laterally and applied to the inner aspect of the vault of skull.



### (2) Medial Surface:

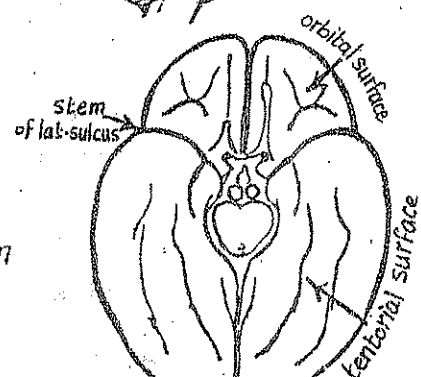
is flattened & separated from the medial surface of the other cerebral hemisphere by the median longitudinal fissure containing the falx Cerebri.



### (3) Inferior surface: irregular & is divided by the

stem of the lateral sulcus into 2 parts:

- (a) ant. part called orbital surface lying on the roof of orbit
- (b) post. part called tentorial surface lying on the tentorium Cerebelli.

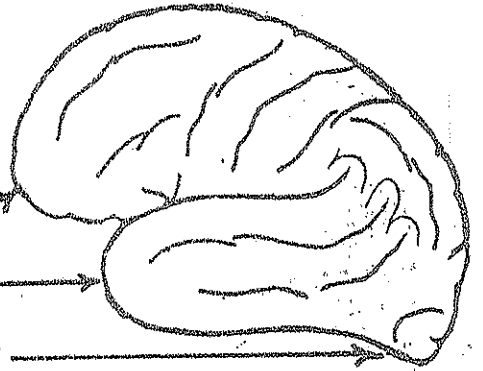


\* Borders: each hemisphere has 3 borders:

- (1) Superomed (superior) border: an arched border extending from the frontal pole to the occipital pole. It separates the lat. surface from the med. surface & is related to the sup. sagittal sinus.
- (2) Infero-lateral (inferior) border: extends from the temporal pole to the occipital pole. It separates the lat. surface from the inf. surface.
- (3) superciliary border: a curved border separating the lat. surface from the orbital part of the inf. surface.

\* Poles: each hemisphere has 3 poles:

- (1) frontal pole: at the ant. end of the frontal lobe.
- (2) temporal: " " " " " " " " temporal lobe.
- (3) occipital: " " " " " " " " post. end of the occipital lobe.



## Lobes of each hemisphere

\* Each Cerebral hemisphere is divided by 3 main sulci or fissures into 4 lobes (which have been given the names of the skull bones under which they lie):

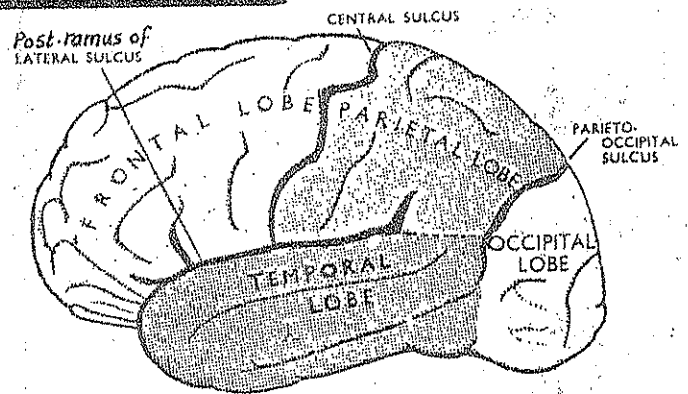
\* These 4 lobes are:

- (1) the frontal lobe
- (2) the parietal lobe
- (3) the temporal lobe
- (4) the occipital lobe

\* The 3 major sulci (fissures) which divide the hemisphere into lobes are:

(1) The Central Sulcus (Fissure of Rolando):

- starts at a point a little behind the middle of the superior border.
- runs obliquely downwards & forwards (without interruption), across the lat. surface.
- ends below at a point just above the middle of the post. ramus of the lat. fissure.
- its upper end usually extends a little on the medial surface of the Cerebral hemisphere.
- it separates the frontal lobe (in front of it) from the parietal lobe (behind it).

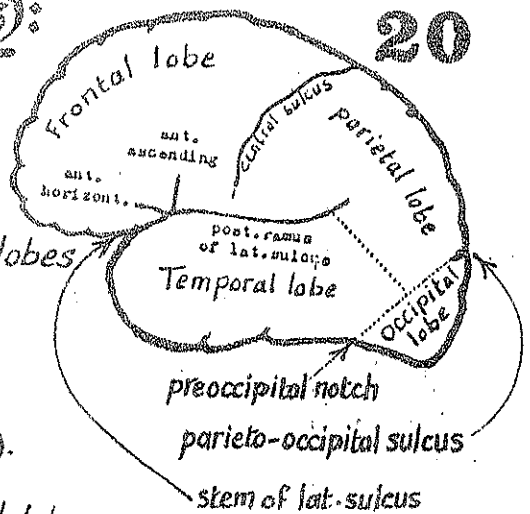


## 2-The Lateral Fissure (fissure of Sylvius):

- Starts on the inf. surface of the hemisphere lat. to the ant. perforated substance.
- Its Stem extends laterally between the temporal & frontal lobes to reach the lat. surface where it divides into 3 rami :

- (a) post. ramus : the longest ; runs backwards between the frontal & parietal lobes (above) & the temporal lobe (below).
- (b) ant. horizontal ramus : runs forwards into the frontal lobe.
- (c) ant. ascending ramus : " upwards " " " " "

- the lat. sulcus lodges : (1) the middle cerebral a. & its branches. —  
(2) the deep middle cerebral vein.



## 3-The Parieto-occipital Sulcus:

- it is found mainly on the med. surface of the hemisphere in front of the occipital pole.
- extends for a short distance on the lat. surface 2" in front of the occipital pole.

## Boundaries of the lobes of the hemisphere

1-the Frontal lobe: lies  $\left\{ \begin{array}{l} \text{in front of the central sulcus \&} \\ \text{above the post. ramus of the lat. sulcus.} \end{array} \right.$

2-the Parietal lobe: bounded:

- anteriorly: by the central sulcus.
- posteriorly: by the upper  $\frac{1}{2}$  of a line connecting the parieto-occipital sulcus & the pre-occipital notch which lies on the inf. border 3-4 cm. in front of the occipital pole.
- inferiorly: by the post. ramus of the lat. sulcus & an imaginary line joining the post. ramus with the centre of the line between the parieto-occipital sulcus & pre-occipital notch.

3-the temporal lobe: bounded:

- superiorly: by the post. ramus of the lateral sulcus.
- posteriorly: by the lower  $\frac{1}{2}$  of the line joining the parieto-occipital sulcus & the preoccipital notch.

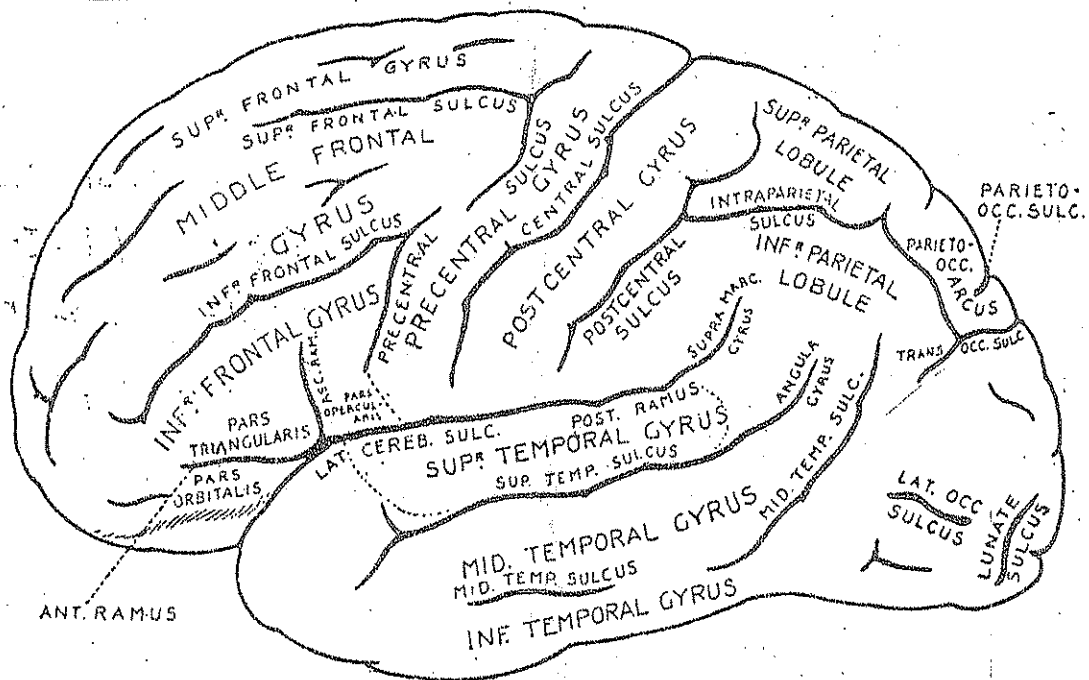
4-the Occipital lobe: lies behind the imaginary line connecting the parieto-occipital sulcus & the pre occipital notch.

# Sulci & Gyri of the Cerebral hemisphere

21

- \* The surfaces of the hemisphere is formed of grey matter & called Cerebral Cortex.
- \* Each surface is divided by Sulci (grooves) into gyri (Convolutions).
- \* These infoldings result in marked increase in the surface area of the cerebral cortex without increasing the size of the cerebral hemisphere.

## I- the Sulci & Gyri of the lateral surface



## A- Frontal lobe

### \* Important sulci:

#### (1) Precentral sulcus:

- lies nearly parallel to the central sulcus & about one finger's breadth in front of it.
- it is usually divided into 2 parts: upper & lower.

#### (2) Sup. frontal sulcus:

- begins at the upper part of the precentral sulcus.
- runs forwards nearly parallel to the sup. border of the hemisphere.

#### (3) Inf. frontal sulcus:

- begins at the lower part of the precentral sulcus.
- runs forwards & downwards below the sup. frontal sulcus.

## \* Important Gyri:

22

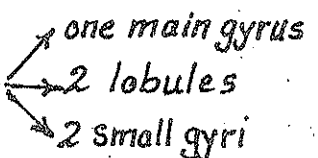
- (1) The Precentral gyrus: lies between the Central sulcus & the precentral sulcus.
- (2) The Superior frontal gyrus: lies above the superior frontal Sulcus.
- (3) The Middle frontal gyrus: lies between the sup. frontal sulcus & the inferior frontal sulcus.
- (4) The Inferior frontal gyrus: lies below the inferior frontal sulcus

## B-Parietal lobe

### \* Important Sulci:

- (1) the Postcentral Sulcus: runs nearly parallel to the Central sulcus & about one finger breadth behind it. It may be formed of 2 parts: upper & lower.
- (2) the Intra-parietal Sulcus: runs backwards like an arch beginning at the postcentral sulcus and passes parallel to the sup. border towards the occipital lobe.

\* Important Gyri: the parietal lobe is divided into:



- (1) the postcentral Gyrus: is the main gyrus & lies between the Central sulcus & the post Central sulcus.
- (2) the Superior parietal lobule: a small part lying above the intra parietal sulcus.
- (3) the Inferior parietal lobule: a larger part lying below the intra parietal sulcus.
- (4) the Supramarginal gyrus: a small arched gyrus surrounding the upper end of the post. ramus of the lat. sulcus. It is the most convex part of the lat. surface.
- (5) the angular gyrus: small arched gyrus surrounding the upper end of the sup. temporal sulcus.

## \* Sulci:

(1) The Superior temporal Sulcus:

- begins near the temporal pole.
- runs backwards parallel to the post. ramus of the lat. sulcus & about 1 finger breadth below it.
- it ends by turning upwards in the parietal lobe where it is surrounded by the angular gyrus.

(2) The middle temporal sulcus: it is an interrupted sulcus. It runs parallel to the sup. temporal sulcus & about one finger breadth below it.

## \* Gyri:

(1) The sup. temporal gyrus: lies between the post. ramus of the lat. sulcus (above) & the sup. temporal sulcus (below).

(2) The middle temporal gyrus: lies between the sup. temporal sulcus (above) and the middle temporal sulcus (below).

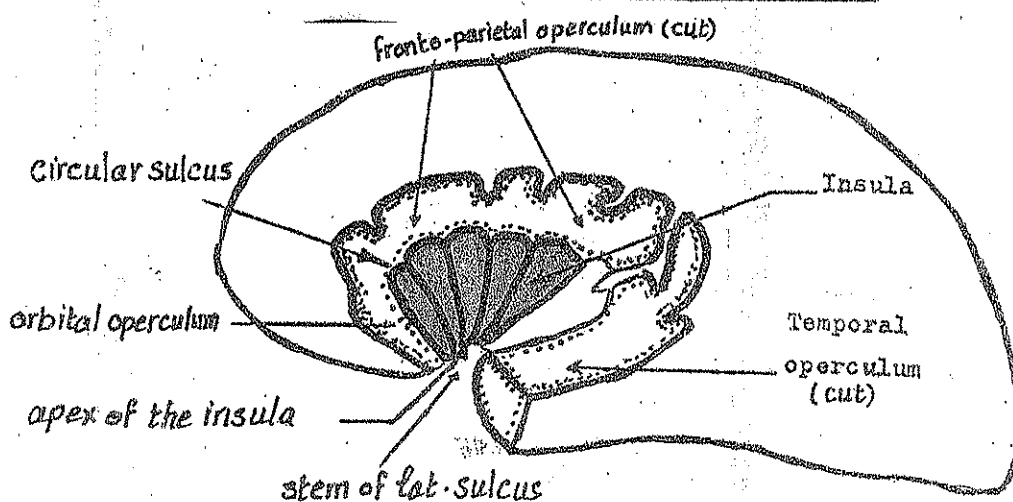
(3) The inferior temporal gyrus: lies below the middle temporal sulcus.

## D-Occipital lobe

\* The main part of the occipital lobe lies on the medial surface.

\* Only a small part appears on the lat. surface and presents one sulcus called the transverse occipital sulcus.

## The Insula



\* Definition: the insula is the part of the cerebral cortex which is **24** hidden in the bottom of the lateral sulcus & appears when the lips of that sulcus are separated.

\* Shape : it is a conical mass having a base & an apex.

\* the base : is surrounded by the circular sulcus of the insula.

\* the Apex : is called limen insulae & is directed downwards.

\* its surface : is marked by a number of gyri radiating superiorly from the stem of the lat. sulcus & crossed by the middle cerebral artery.

\* the Opercula of the insula: are the parts of the cerebral hemisphere which cover the insula (fronto-parietal operculum, temporal operculum & orbital operculum).

## Sulci & Gyri of the inf. surface

\* The ant. 1/3 of the inferior surface is called the Orbital Surface.

it represents the inferior surface of the frontal lobe & rests on the orbital plate of frontal bone.

\* The post. 2/3 of the inferior surface is called the tentorial surface

it represents the inferior surface of the temporal & occipital lobes.

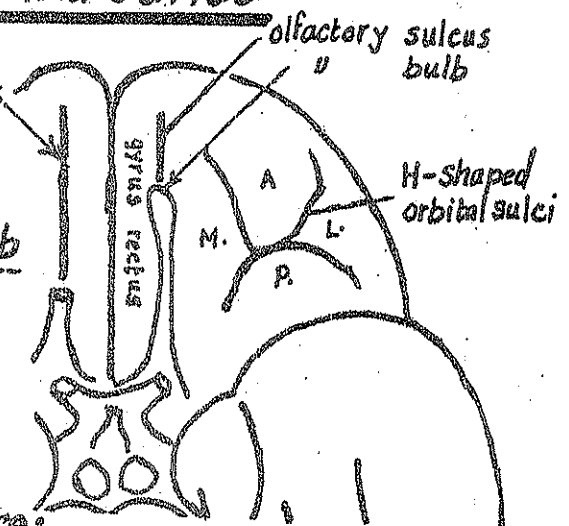
The tentorial surface partly rests on the upper surface of the tentorium cerebelli.

## Sulci & Gyri of the Orbital surface

(1) Olfactory sulcus : a straight deep sulcus which lies near the medial border & nearly parallel to it. It lodges the olfactory bulb & tract.

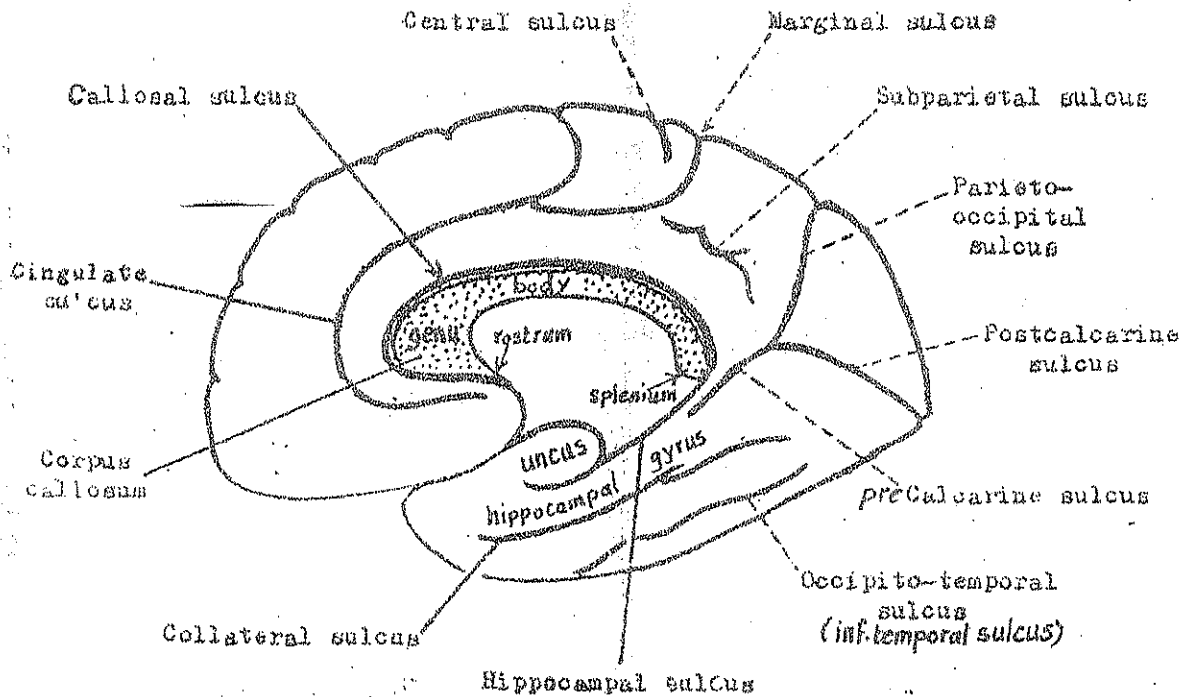
(2) Gyrus rectus (straight gyrus) : lies medial to the olfactory sulcus.

(3) the remaining part of the orbital surface: is divided into : ant., post., med. & lateral gyri by H-shaped orbital sulci.





# The Sulci & Gyri of the Medial & Tentorial Surfaces 25



## \* The important Sulci:

### (1) the Callosal & hippocampal sulci:

(a) Callosal Sulcus: is an arched sulcus which lies just above the Corpus Callosum. It begins below the rostrum of the corpus callosum, forms an arch over its genu & body then bends around its splenium to become continuous with the hippocampal sulcus.

(b) Hippocampal Sulcus: seems to be the continuation of the callosal sulcus. It passes forwards from the splenium of corpus callosum to end in the bend between the uncus & the hippocampal gyrus (See the figure).

(2) Cingulate Sulcus: an arched sulcus lying about one finger's breadth above the callosal sulcus & parallel to it. It ends a little behind the upper end of the central sulcus by dividing into 2 branches:

(a) the marginal sulcus: which turns upwards to cut the sup. border.

(b) the subparietal sulcus: which continues backwards in the main direction of the cingulate sulcus.

(3) Calcarine Sulcus: it is a deep arching sulcus having 2 parts: ant. & post. which meet each other almost at right angle:

(a) an anterior part called precalcarine : begins below the splenium of corpus callosum & runs upwards & backwards to meet the lower end of the parieto-occipital sulcus.

(b) a posterior part called postcalcarine : extends downwards & backwards from the lower end of the parieto-occipital sulcus to reach the occipital pole.

#### (4) Parieto-occipital Sulcus:

- begins at the junction of the precalcarine & postcalcarine sulci.
- runs upwards to cut the upper border of the C-hemisphere about 2" in front of the occipital pole.

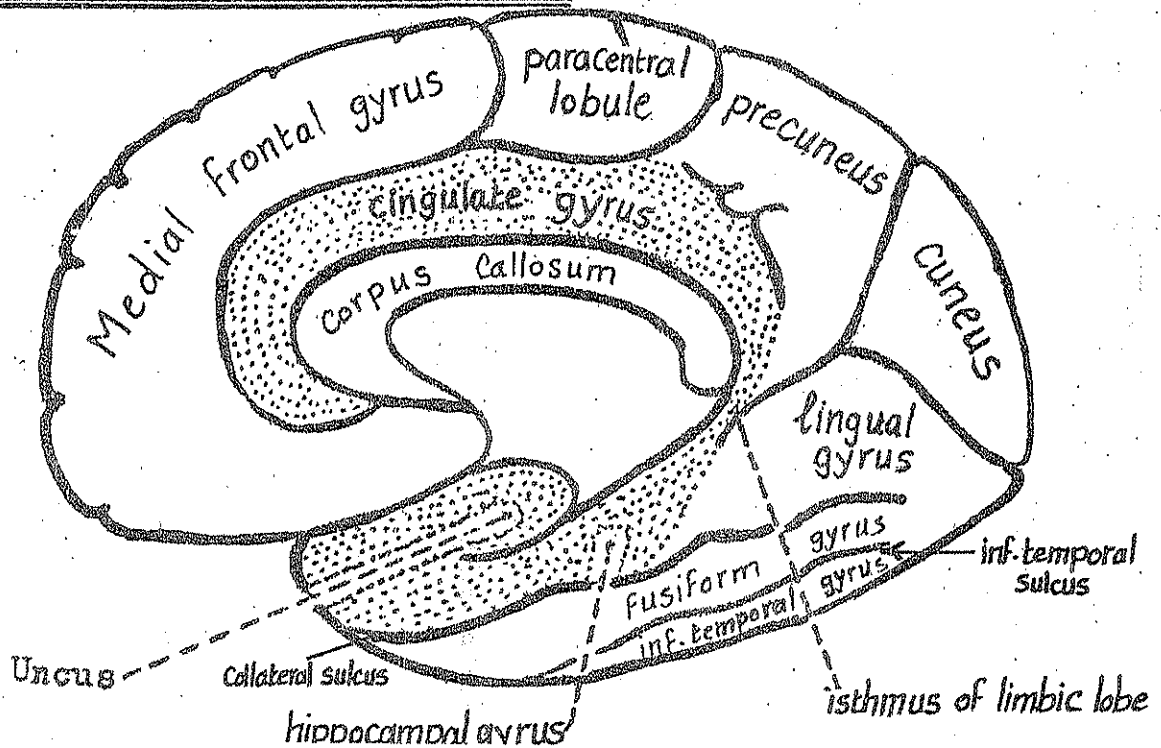
#### (5) Collateral Sulcus:

- It is the best marked sulcus on the tentorial surface.
- It begins at the temporal pole & extends backwards & parallel to the calcarine sulcus and lat. to it till it reaches the med. surface of the occipital lobe.

#### (6) Inferior temporal (occipito-temporal) sulcus:

it is an irregular interrupted sulcus lying on the tentorial surface lat. to & parallel with the Collateral sulcus.

### \* The important Gyri:



## (1) Cingulate gyrus:

27

- lies on the medial surface between the cingulate sulcus & the callosal sulcus.
- its posterior end turns downwards around the splenium of the corpus callosum to form the isthmus which joins the hippocampal gyrus anteriorly

## (2) Hippocampal gyrus & uncus:

- lies on the tentorial surface between the hippocampal sulcus and the ant. part of the collateral sulcus.
- its ant. end bends to form the UNCUS.

## (3) Medial Frontal gyrus:

- lies on the medial surface above the cingulate gyrus & in front of the paracentral lobule.
- It forms the medial surface of the sup. frontal gyrus.

## (4) The Cuneus:

- it is a triangular gyrus lying between the parieto-occipital sulcus and the postcalcarine sulcus

## (5) The Pre-cuneus: it is a quadrilateral gyrus lying between:

- (a) the marginal sulcus (in front) (b) the parieto-occipital sulcus (behind)
- (c) the subparietal sulcus (below) (c) the sup. border of the hemisphere (above)

## (6) The paracentral lobule:

- it is a quadrilateral gyrus surrounding the upper end of the central sulcus.
- it contains the motor & sensory areas of the lower part of the lower limb.

## (7) Lingual gyrus:

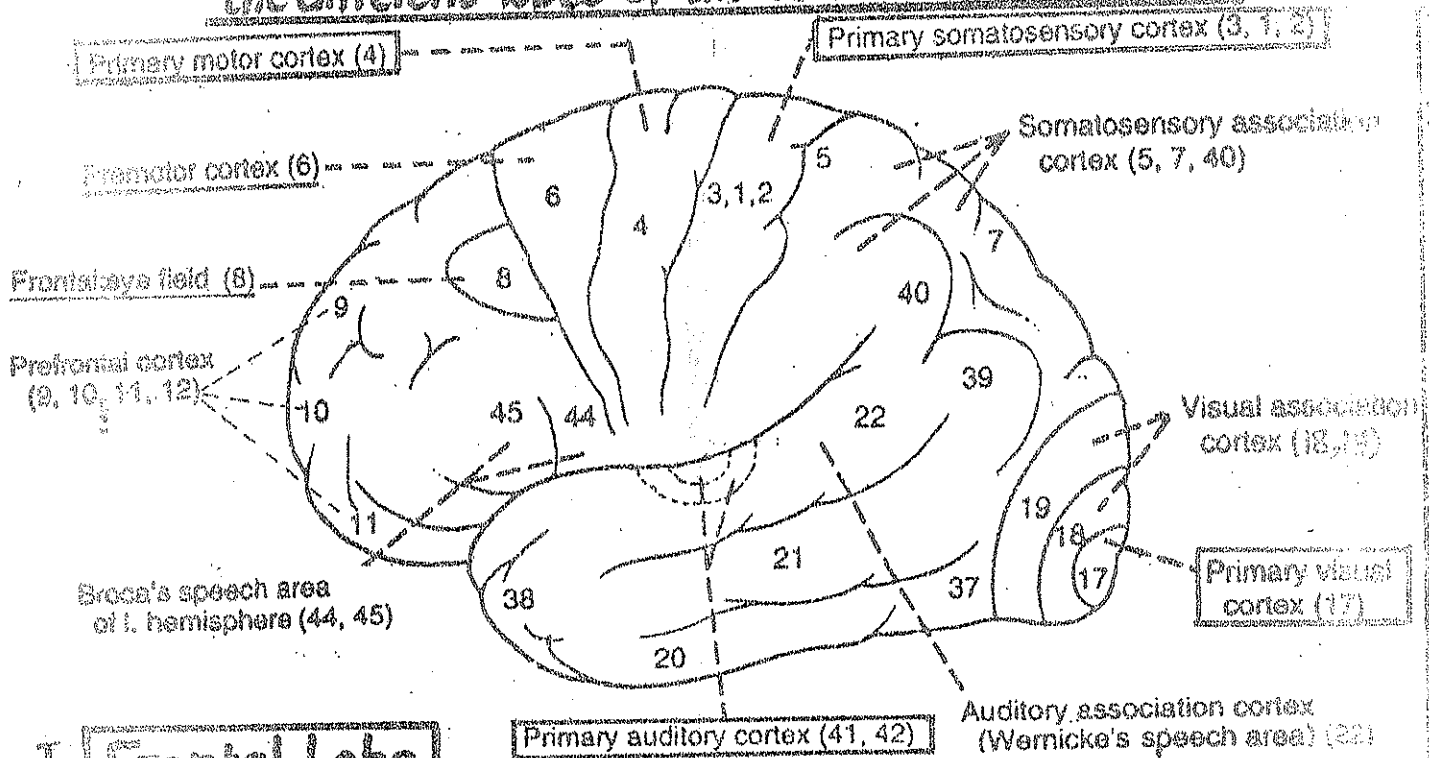
lies between the calcarine sulcus (above) & the post. part of the collateral sulcus (below).

## (8) Fusiform gyrus: (med. occipito-temporal gyrus):

lies between the collateral sulcus & the inferior temporal sulcus.

## (9) Inferior temporal gyrus: lies lateral to the inf. temporal sulcus.

# Important functional areas of the different lobes of the cerebral hemispheres

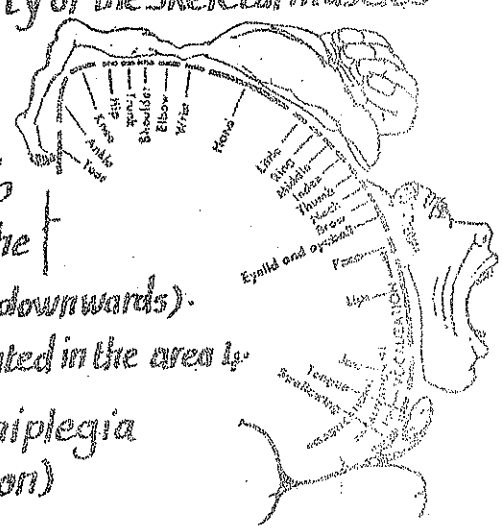


Brodmann's areas of the lateral surface

## I Frontal Lobe

### (1) The Motor area (area 4):

- \* Site: occupies the precentral gyrus & extends to occupy the ant. part of the paracentral lobule on the medial surface of the cerebral hemisphere.
- \* Function: it contains the giant pyramidal cells of Betz which give origin to 80% of the pyramidal tract which controls the motor activity of the skeletal muscles of the opposite 1/2 of the body (except the eye).
- \* Body representation: the body is represented upside down in this gyrus i.e the area of the lower limb occupies the uppermost part followed by the trunk, the upper limb, the neck & the head (arranged from above downwards).
- N.B: the movements and not the muscles are represented in the area 4.
- \* Lesion of the area 4: results in Contralateral hemiplegia (of upper motor neuron lesion)



### (2) Premotor area (area 6):

- \* Site: in front & parallel to the motor area. It is wide above (5cm) & narrow below (1cm).
- \* Function: it is the main extrapyramidal area for the body except the eye (which is found in the occipital lobe)

### (3) Frontal eye field (area 8):

- \* Site: in front of the premotor area, in the post. part of the middle frontal gyrus.

#### (4) Broca's Speech area (area 44, 45) :

29

\* Site: in the post. part of inf. frontal gyrus in the dominant hemisphere.  
(left hemisphere in the right-handed persons).

\* function: it lies near to the motor area of the larynx, tongue & lips (all together are necessary for speech).

\* Injury to this area causes patients to speak slowly & with effort (nonfluent speech).

#### (5) Prefrontal Cortex (areas 9, 10, 11 & 12) :

\* Site: in the remaining part of lat. surface of the frontal lobe as far as the frontal pole.  
& also extends to the med. surface

\* function: it is concerned with the control of conduct, behavior, thinking & emotions.

\* Injury to this area leads to Frontal lobe syndrome which comprises :

(a) abnormal social behavior (b) emotional disturbances (c) educational regression.

(6) Orbital Surface of frontal lobe : is related to the control of autonomic activity.

## II- Parietal Lobe

#### (1) 1<sup>st</sup> Somatosensory cortex (Main sensory area) : areas 3, 1, 2

\* Site: it occupies the postcentral gyrus on the lat. surface of the cerebral hemisphere & extends to the post. part of the paracentral lobule on the med. surface.

\* function:

(1) it receives pain, touch, proprioception, temperature & taste sensations from the opposite  $\frac{1}{2}$  of the body (The body is represented upside down).

(2) it contributes to the pyramidal tract (giving 10% of its fibres).

\* lesion to this area results in loss of tactile discrimination from the opposite  $\frac{1}{2}$  of the body.

#### (2) Somatosensory association cortex (areas 5 & 7) :

\* Site: in the sup. parietal lobule.

\* function: knowing the meaning of the sensations felt (by associating the visual, auditory & tactile sensations).

\* lesion to this area results in :

(a) inability to recognize the felt objects (astereognosis)

(b) disturbed body image (astatognosis): inability to recognize the position of body parts in space (the patient may feel that the Rt.  $\frac{1}{2}$  of his body is the Lt.  $\frac{1}{2}$ ).

#### (3) Supramarginal gyrus (area 40) :

\* site: it surrounds the upper end of the post. ramus of lateral sulcus.

\* function: it interrelates sensory, auditory & visual stimuli.

- \* Injury of this area leads to apraxia (inability to perform purposeful movements):
  - (a) Ideomotor apraxia: inability to perform complicated motor tasks e.g. Saluting.
  - (b) Ideational apraxia: inability to use objects (e.g. when tools are placed in a patient's hands).
  - (c) Facial apraxia: inability to perform facial-oral movements e.g. licking the lips.

#### (4) Angular gyrus (area 39): (visual auditory conversion area):

- \* Site: it surrounds the upper end of superior temporal sulcus.
- \* Function: it receives input visual impulses from areas 18, 19 & projects them to the Wernicke's area.
- \* Injury to this area leads to:
  - (1) agraphia: inability to express thoughts in writing.
  - (2) dyscalculia: difficulty with arithmetics (inability to do simple sums).

### III- Temporal lobe

#### (1) Auditory Sensory area (area 41, 42):

- \* Site: in the middle part of the sup. temporal gyrus (Heschl's gyrus):
- \* Function: it receives the auditory radiation from the medial geniculate body.
- \* Injury: unilateral destruction results in only partial deafness (due to bilateral cochlear representation).

#### (2) Auditory association area (area 22)

- \* Site: in the post. part of sup. temporal gyrus. It includes Wernicke's speech area which is connected to Broca's area by the arcuate fasciculus.
- \* Function: it is responsible for knowing the meaning of sounds.
- \* Injury of this area in the dominant hemisphere leads to Wernicke's aphasia: the patient finds difficulty in understanding spoken language, speaks faster than normal & has difficulty in finding the right words to express himself.

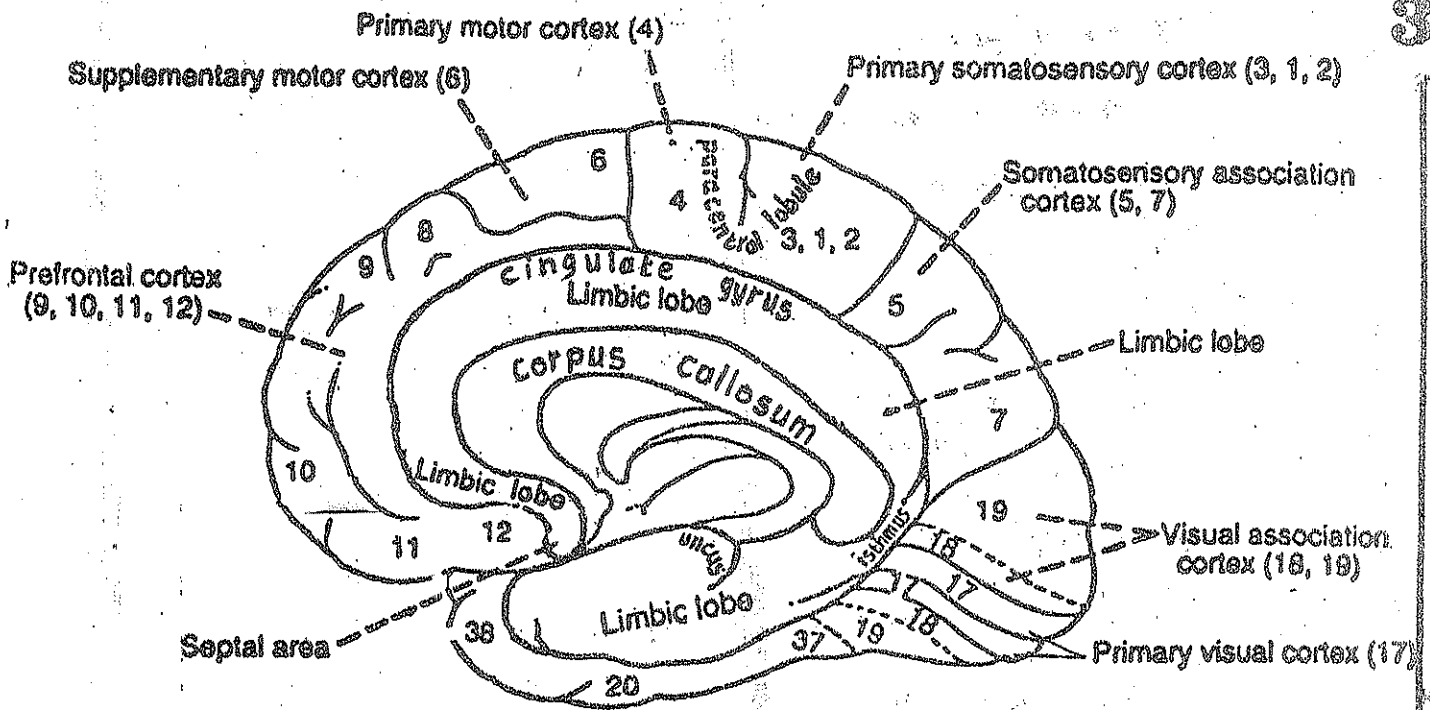
#### (3) The Insula:

- \* Site: see page 24
- \* Function: the gustatory cortex (area 43) in the parietal operculum & para-insular cortex. It receives taste impulses from the thalamus.

### IV- The occipital lobe

#### (1) Visual Sensory area (area 17):

- \* Site: found mainly in the med. surface of occipital lobe in both banks of calcarine sulcus.
- \* Function: it receives input visual sensation from the lat. geniculate body via the optic radiation.
- \* Injury: results in visual field defects e.g. contralateral homonymous hemianopia.



(2) Visual association are (areas 18, 19) :

- \* Site : in the cuneus & lingual gyrus, surrounding the visual sensory area 17.
- \* Function : it is responsible for knowing the meaning of the pictures seen.
- \* Injury : may result in visual hallucinations.

**V - the Rhinencephalon or Limbic lobe**

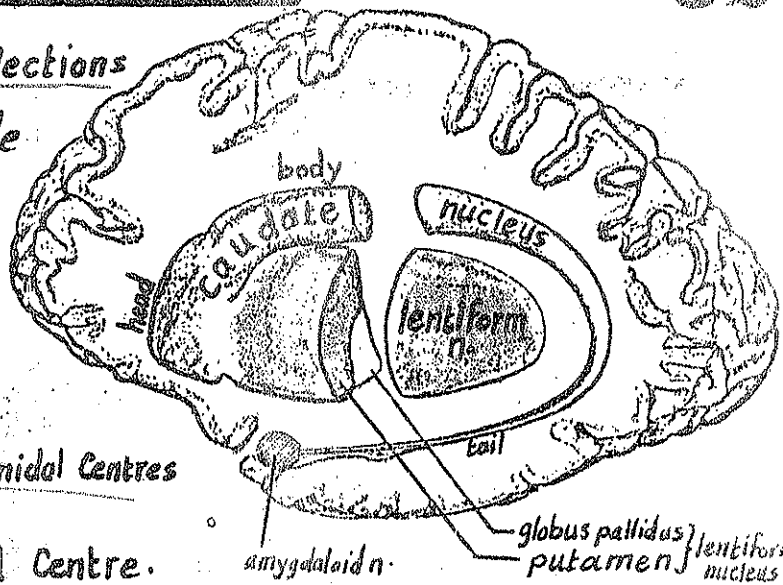
- \* It is the name given to number of cortical & subcortical structures lying on the medial surface in the form of an arch (limbus).
- \* The limbic lobe includes the shadowed areas in the figure (cingulate gyrus, isthmus, hippocampal gyrus & uncus) + other structures
- \* It is described in detail in page 97.
- \* Functions : (1) reception of olfactory stimuli.  
 (2) integration of olfactory, visceral & somatosensory sensations.  
 (3) influencing the behaviour, emotions & memory.

Internal Structure of cerebral hemisphere : see p. 86



# Basal Ganglia

● Definition: basal ganglia are collections of grey matter deeply placed inside the white matter of the cerebral hemisphere.



LATERAL ASPECT

● Components:

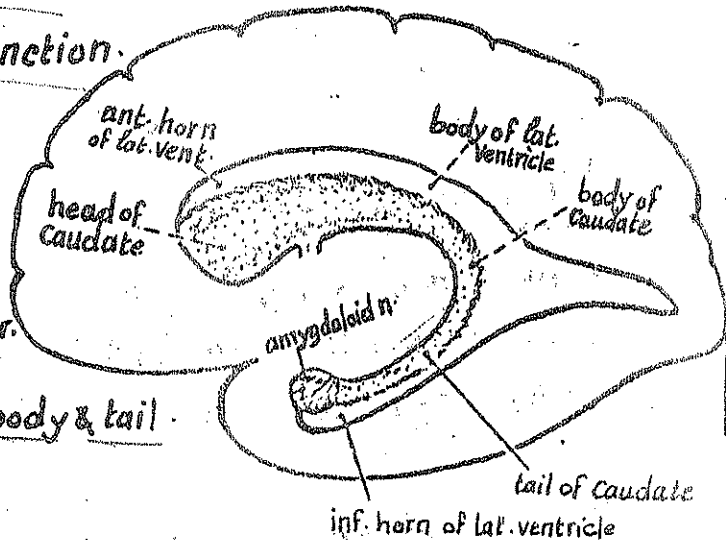
- 1- Caudate nucleus
  - 2- lentiform nucleus
  - 3- amygdaloid nucleus: ... a smell Centre.
  - 4- Claustrum..... unknown function.
- } Extra pyramidal Centres

## 1- The Caudate Nucleus

(the nucleus with a tail)

● Shape: Comma-shaped mass of grey matter.

● Parts & Relations: it consists of head, body & tail.



MEDIAL ASPECT

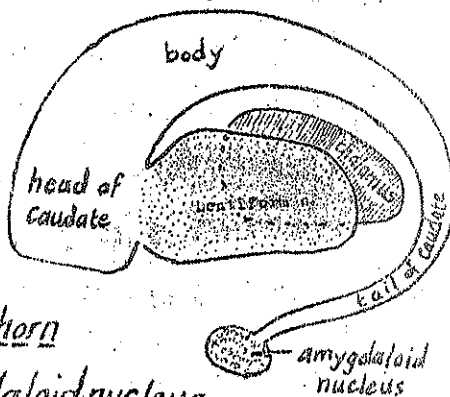
(1) head: it is the large ant. end.

- it forms the lat. wall of the ant. horn of the lat. ventricle.

- it is fused posteriorly with the lentiform nucleus & below with the ant. perforated substance.

(2) body: arches upwards & backwards above & lat. to the thalamus forming part of the floor of the central part of the lat. ventricle.

(3) tail: curves downwards & forwards in the roof of the inf. horn of lat. ventricle in the temporal lobe. It ends at the amygdaloid nucleus.



## 2- The Amygdaloid Nucleus

● it is a small rounded mass lying mostly in the uncus of temporal lobe, joined to the tail of caudate nucleus.

● it is a smell Centre.



## 3- Lentiform Nucleus

(Lens-like)

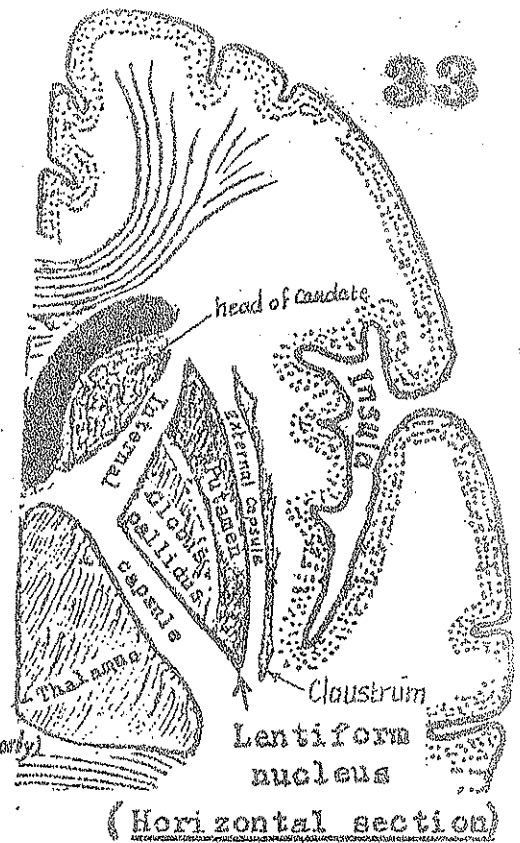
\* Shape: it resembles a biconvex lens which consists of 2 parts, has 2 surfaces & related to 2 capsules.

\* Parts: it consists of:

- (1) Putamen: the larger darker lateral part.
- (2) globus pallidus: the smaller, paler medial part.

\* Surfaces & relations:

- (1) medial surface: is highly convex & is related to the internal capsule which separates the lentiform nucleus from the head of caudate (anteriorly) & the thalamus (posteriorly).
- (2) Lateral surface: is slightly convex & is related to the external capsule which separates the lentiform nucleus from the Clastrum & insula.



## 4- Claustrum

it is a thin layer of grey matter lying between the external capsule (medially) & the white matter of the insula (laterally). Its antero-inferior part fuses with the amygdaloid nucleus & ant. perforated substance. Its function is unknown.

## The Corpus Striatum

\* it is the name given to:

- (1) the caudate nucleus
- (2) the lentiform nucleus &
- (3) the intervening ant. limb of internal capsule

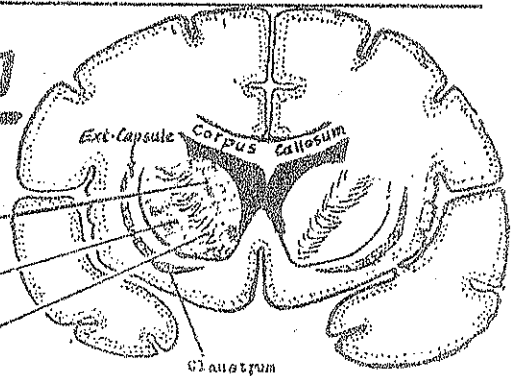
\* They are called so because they show a striated appearance.

Corpus Striatum:

Caudate N.

Lentiform N.

Int. Capsule



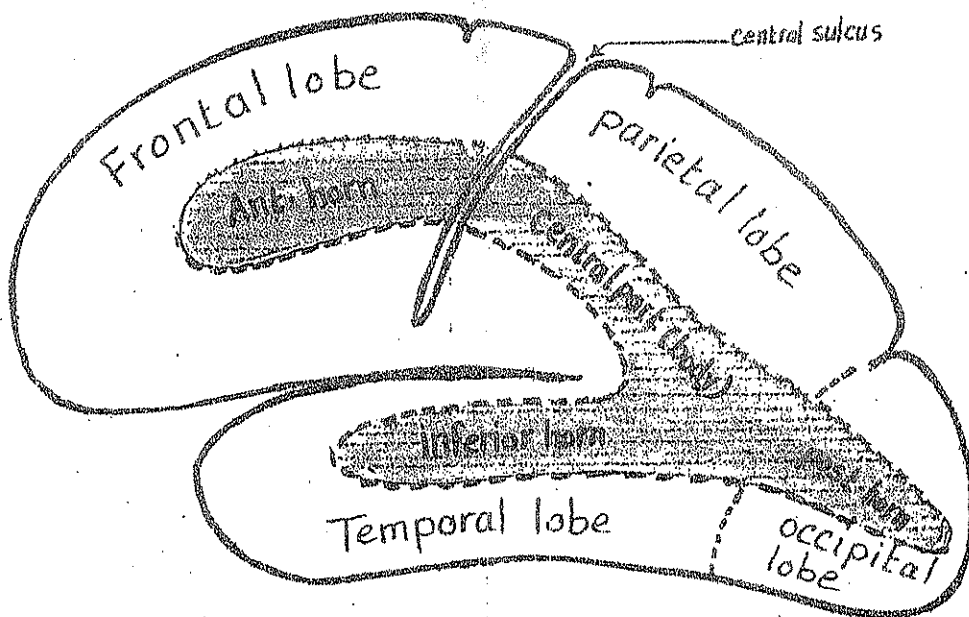
Coronal section of Cerebral Hemisphere behind genu of C.C. illustrating basal ganglia & Int. capsule

## The External Capsule

\* it is a thin layer of white matter which covers the outer surface of the lentiform nucleus (forming an external capsule to it) & separating the lentiform n. from the claustrum & the white matter of the insula. Some of its fibres are probably association fibres connecting the temporal lobe to the frontal & parietal lobes.

\* Internal Structure & connections of the basal ganglia: page 96

# The Lateral Ventricle



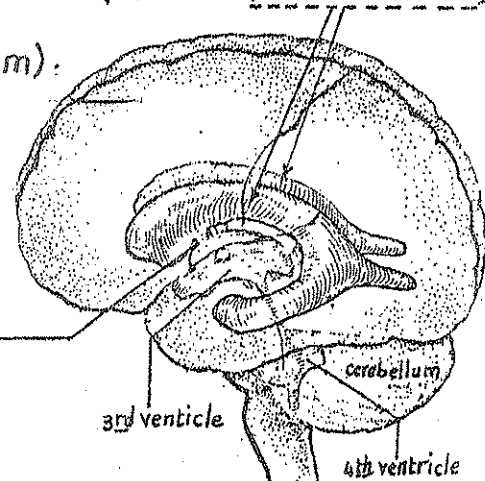
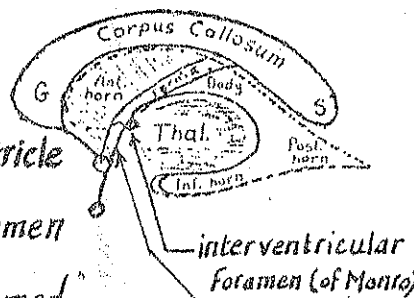
\*Site: it is the cavity present in each cerebral hemisphere. (there are 2 lat. ventricles)

\*Lining: it lined by ependyma (ciliated cubical epithelium).

## \*Communications:

- it communicates with the 3rd ventricle through the interventricular foramen which lies in the ant. part of the med. wall of the lat. ventricle

- the interventricular f. is bounded anteriorly by the column of the fornix & posteriorly by the ant. end of the thalamus.



## \*Shape & Parts: it is an elongated crescentic cavity consisting of body & 3 horns:

(a) the body (central part): lies in the parietal lobe. It extends from the interventricular f. to the splenium of corpus callosum. It communicates with the 3 horns.

(b) Anterior horn: lies in the frontal lobe. It extends forwards & laterally from the interventricular f. to a point  $1\frac{1}{2}$  inches behind the frontal pole.

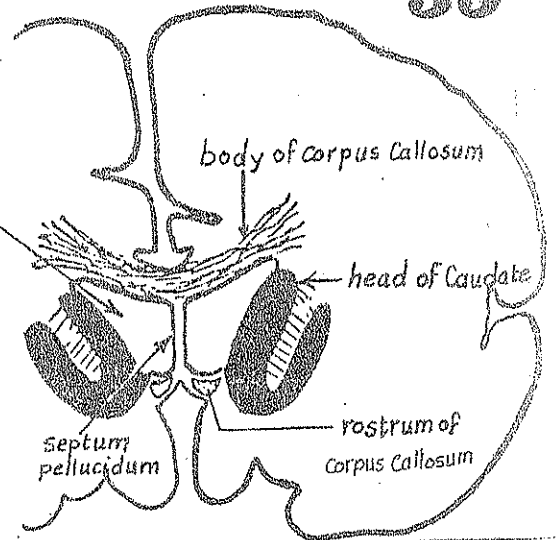
(c) Posterior horn: lies in the occipital lobe where it extends backwards & medially.

(d) Inferior horn: lies in the temporal lobe. It extends from the body, first downwards behind the thalamus then forwards in the temporal lobe to end at the uncus.

## \* Boundaries & Relations:

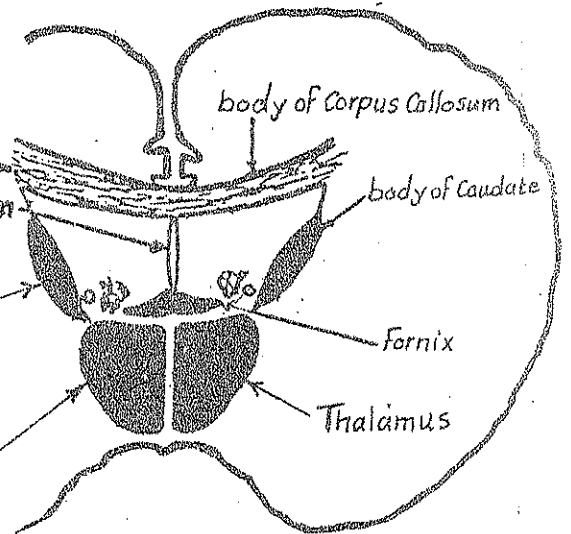
### (A) the anterior horn: $\Delta$ in coronal section

- Roof: the ant. part of the body of Corpus Callosum.
- Med. Wall: the ant. part of septum pellucidum
- Lat. wall & floor: head of Caudate nucleus & rostrum of Corpus Callosum
- Ant. wall (limit): the genu of corpus callosum.



### (B) The Central Part (body):

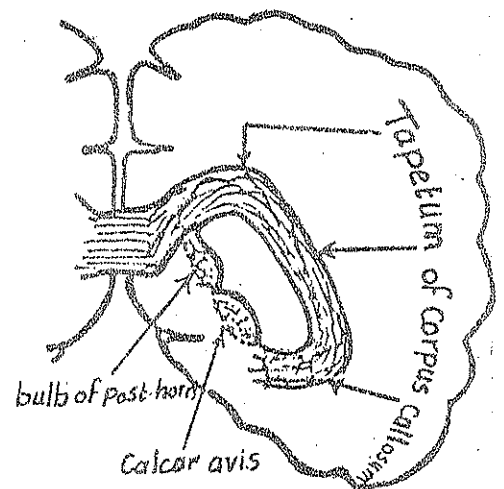
- Roof: formed by the body of Corpus Callosum
- Med. Wall: formed by the post. part of the Septum pellucidum
- Floor: is sloping & formed by the following structures (from lat. to medial):
  - (1) the body of Caudate nucleus
  - (2) the lat. part of the upper surface of the thalamus
  - (3) the body of the Fornix which arches above the med. part of the upper surface of the thalamus.



N.B: the part of the thalamus in the floor of the body of central part is partially hidden by the choroid plexus.

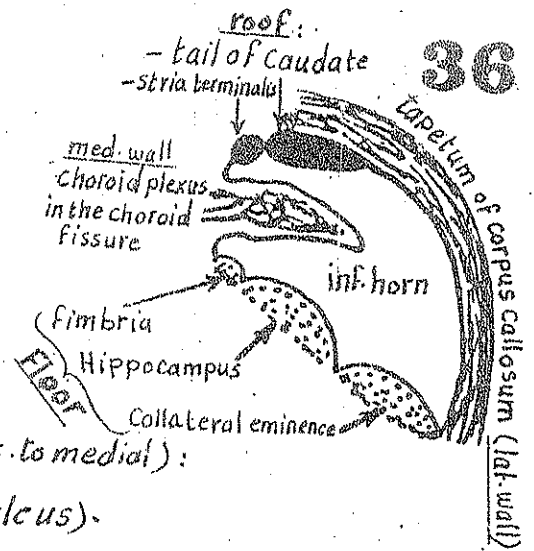
### (C) The Posterior horn:

- the roof, lat. wall & floor: is formed by the tapetum of Corpus Callosum which separates the inf. horn from the optic radiation.
- the Med. Wall: is sloping and shows 2 elevations:
  - (1) Superiorly: bulb of post. horn: produced by the fibres of the forceps major of the internal capsule.
  - (2) Inferiorly: Calcar avis: which is a swelling produced by the Calcarine sulcus which extends deeply into the occipital lobe.



D-Inferior horn: has the following boundaries:

- Roof: formed by the tail of caudate as it passes forwards to end in the amygdaloid nucleus.
- Med. wall: is occupied by the lower part of the choroid fissure through which the choroid plexus enters the inf. horn.
- Floor: formed of the following structures (from lat. to medial):
  - (1) Collateral eminence: (produced by the collateral sulcus).
  - (2) Hippocampus, covered by a layer of nerve fibres called the alveus.
  - (3) Fimbria of the hippocampus:
- Lateral wall: formed by the tapetum of corpus callosum.

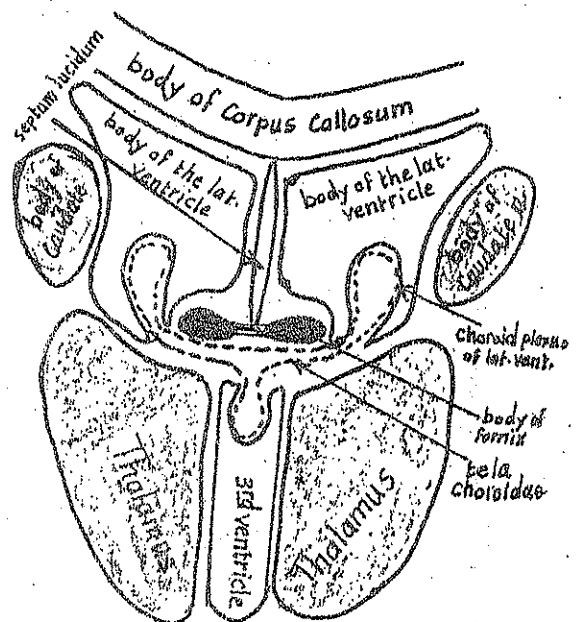


## The Septum Pellucidum (lucidum)

- \* It is a vertical membrane formed of white & grey matter which occupies the gap between the corpus callosum (above) & the fornix (below).
- \* It consists of 2 layers with a slit-like cavity in between.
- \* It forms a partition between the ant. horns & the central parts of the 2 lat. ventricles (forming the med. wall of the ant. horn & the central part of each lat. ventricle).

## The Tela Choroidae

- \* It is a double-layered fold of pia mater intervening between:
  - the body of the fornix ----- above.
  - the upper surface of the 2 thalami } ----- below.
  - & the roof of the 3rd ventricle }
- \* It contains choroid plexuses which invaginate into:
  - (1) the body of each lat. ventricle through the choroid fissure (between the fornix & the thalamus).
  - (2) the 3rd ventricle through its ependymal roof.
- \* It also contains the Rt. & Lt. internal cerebral veins (which drain the choroid plexuses) at its edges.



# Diencephalon

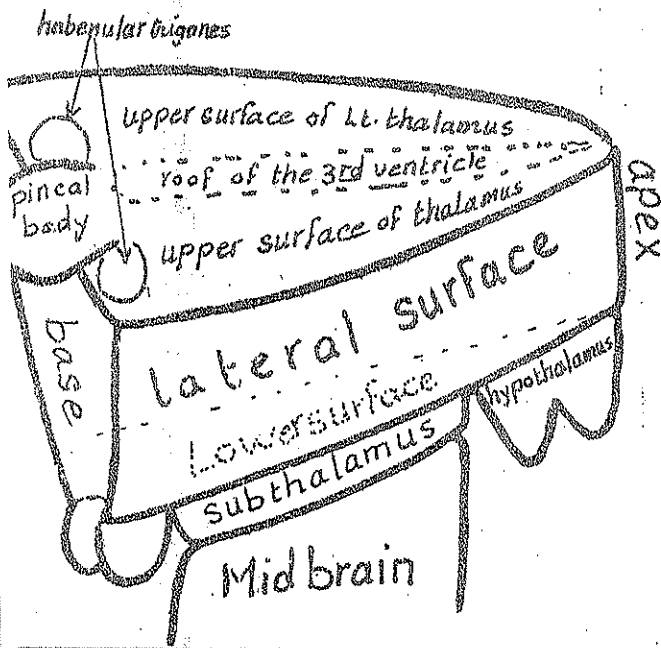
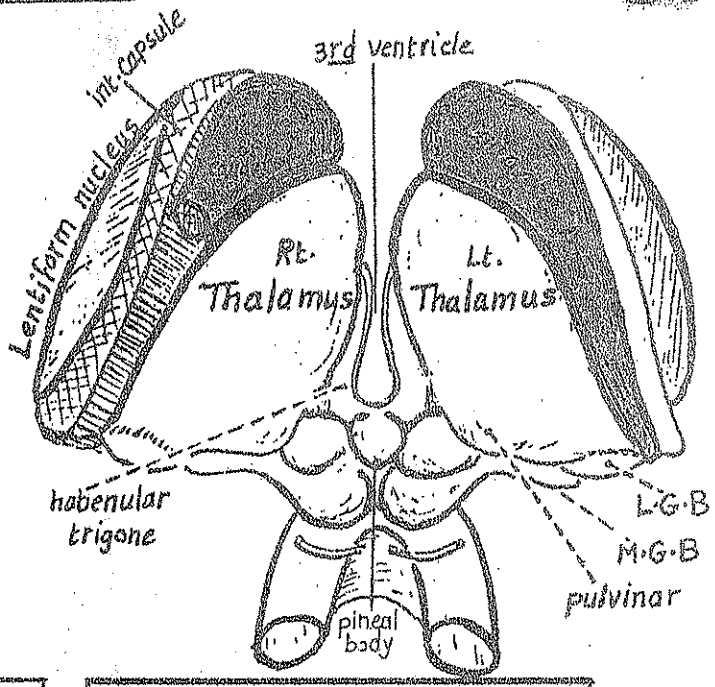


Diagram illustrating the structure of the diencephalon



Diencephalon, seen from behind

Site: it is the part of the brain stem which lies above the midbrain & between the lower parts of the 2 cerebral hemispheres.

Its cavity: is the 3rd ventricle.

Shape: wedge shaped having:


- apex: is the ant. sharp border.
- base: directed posteriorly.
- 2 lateral surfaces: each is quadrilateral in outline.
- upper surface: triangular in outline with its apex directed anteriorly. It is formed of:
  - (a) the upper surface of the 2 thalami (on each side of the median plane).
  - (b) the roof of the 3rd ventricle, the pineal body & the 2 habenular trigones (in the median plane, arranged from before backwards).

i- the lower surface: is divided into 3 parts:

- (a) the hypothalamus: the ant. part which is connected to the pituitary gland.
- (b) the subthalamus: the middle & largest part which lies over the midbrain.
- (c) the metathalamus: the post. part which is formed by the med & lat. geniculate bodies.

\* Subdivisions of the diencephalon: it is subdivided into 5 parts: **38**

- (1) Thalamus (bilateral): the largest part
- (2) Subthalamus: the part lying directly above midbrain.
- (3) Hypothalamus: lies in front of the subthalamus
- (4) Metathalamus (bilateral): formed by the lat. & medial geniculate bodies
- (5) Epithalamus: formed of the pineal body, the 2 habenular trigones & the habenular commissure.



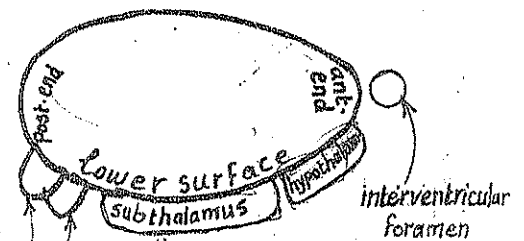
## 1- The Thalamus

\* It is an ovoid mass of grey matter (1.5" long & 1/2 inch broad) lying in the middle of the cerebrum.

\* Site: it lies one on each side of the 3rd ventricle, immediately above the subthalamus & projecting in front & behind it.

\* Shape & relations: it is oval in shape having:

- (1) narrow ant. end: forming the post. boundary of the interventricular foramen.
- (2) expanded post. end called pulvinar which overhangs the med. & lat. geniculate bodies & projects behind the post. wall of the 3rd ventricle.



(3) upper surface:

- medially: it is covered by tela choroidae & body of the fornix
- laterally: it forms the floor of the central part of the lat. ventricle & is related to body of caudate N. & stria terminalis

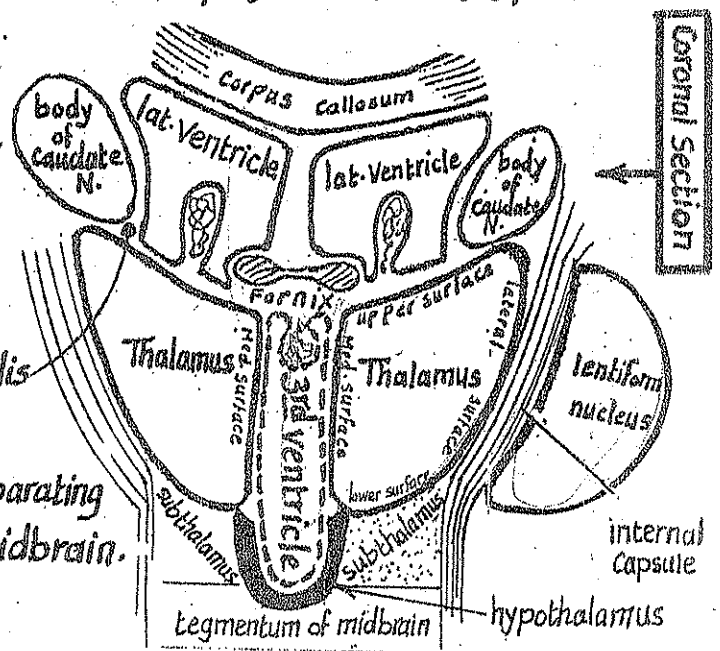
(4) Lower surface:

- posteriorly: it rests on the subthalamus separating it from the tegmentum of the midbrain.
- anteriorly: it rests on the hypothalamus.

(5) Medial surface:

forms the upper part of the lat. wall of the 3rd ventricle & is separated from the hypothalamus below by the hypothalamic sulcus.

(6) Lateral surface: related to the post. limb of the internal capsule separating it from the lentiform nucleus.





- \* Blood supply of thalamus: (1) mainly from the post-cerebral a.  
(2) post-communicating a.

\* Internal Structure: see tractology page 98

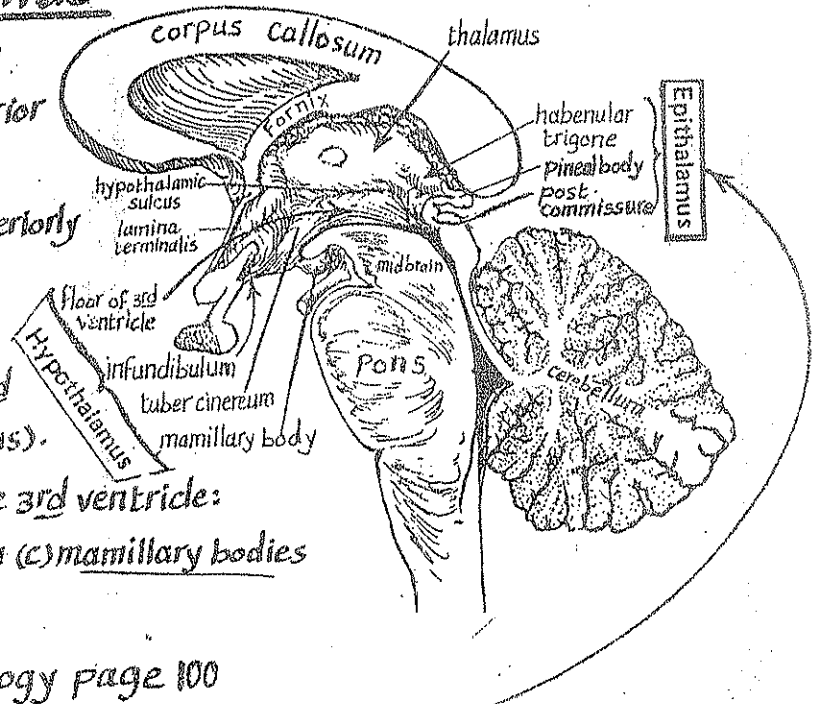
## 2- Hypothalamus

\* It is the part of the diencephalon which lies in front of subthalamus & antero-inferior to the thalamus.

\* it extends from the lamina terminalis anteriorly to the mamillary bodies posteriorly.

\* It includes the following structures:

- (1) the lower part of the lat. wall of the 3rd ventricle (below the hypothalamic sulcus).
- (2) the structures forming the floor of the 3rd ventricle:
  - (a) the infundibulum (b) the tuber cinereum (c) mamillary bodies
  - (d) the posterior perforated substance.



\* Internal structure: see tractology page 100

## 3- Epithalamus

\* It lies in the post-end of the upper surface of the diencephalon.

\* it consists of: 2 habenular trigones, habenular commissure, pineal body & the post-commissure

- (1) the habenular trigone: is a small triangular depression (one on each side), lying med. to the pulvinar of the thalamus.
- (2) the habenular commissure: is a transverse band between the 2 sides connecting the 2 habenular trigones & running in the upper root of the stalk of the pineal body.

(3) the pineal body:

- it is a small conical mass lying in between the post-ends of the 2 thalami
- it is overlapped above by the splenium of the corpus callosum but is separated from it by the great cerebral vein.
- below, it overhangs the depression between the 2 sup. colliculi on the post-surface of the midbrain.
- the pineal body is attached to the post. wall of the 3rd ventricle by a hollow stalk having 2 roots:
  - ← upper root attached to the habenular commissure.
  - ← lower root attached to the post. commissure.



\* Internal structure of Epithalamus: see tractology page 101.

## 4- Metathalamus

\* It is the part of the diencephalon which is attached to the post. part of the inf. surface of the thalamus below the pulvinar.

\* It consists of the medial & lateral geniculate bodies:

### (1) Medial geniculate body (M.G.B):

\* it is a small ovoid mass lying just lat. to the sup. colliculus of the midbrain.

\* it is connected to the inferior colliculus by the brachium of inf. Colliculus.

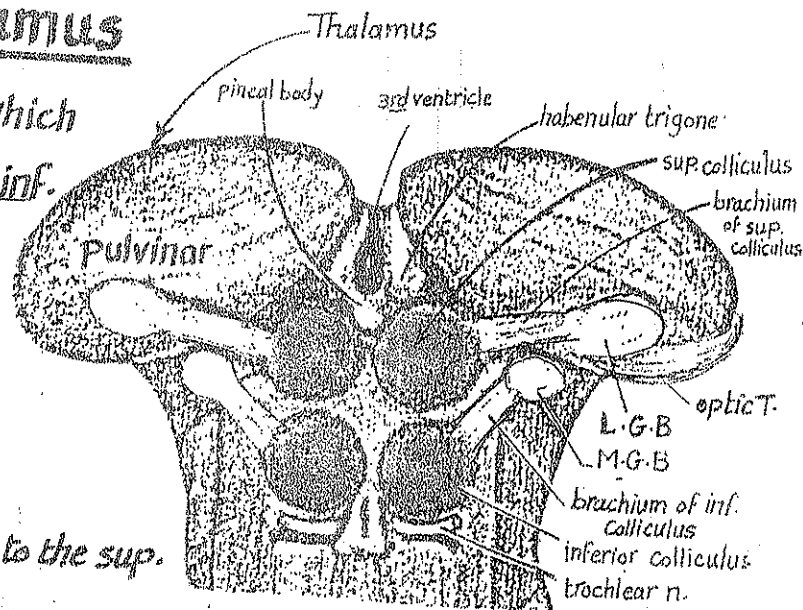
### (2) Lateral geniculate body (L.G.B):

\* it is a small ovoid mass lying lat. to the M.G.B.

\* it is connected posteriorly to the sup. colliculus via the brachium of sup. colliculus.

\* it is connected anteriorly to the optic tract:

\* Internal structure of the metathalamus: see tractology page 102



## 5- Subthalamus

\* It is the part of the diencephalon which intervenes between the thalamus & the tegmentum of midbrain.

\* relations:

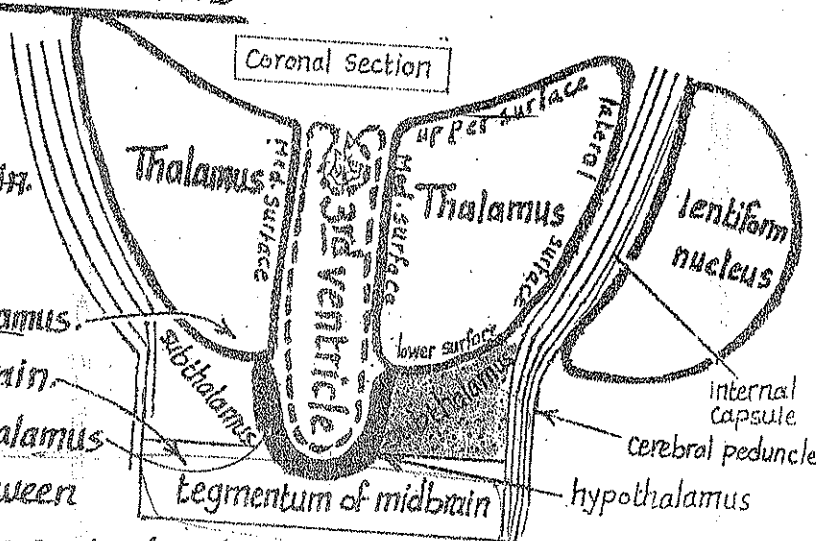
- superiorly: ventral nuclei of the thalamus.

- inferiorly: tegmentum of the midbrain.

- medially: ventral part of the hypothalamus

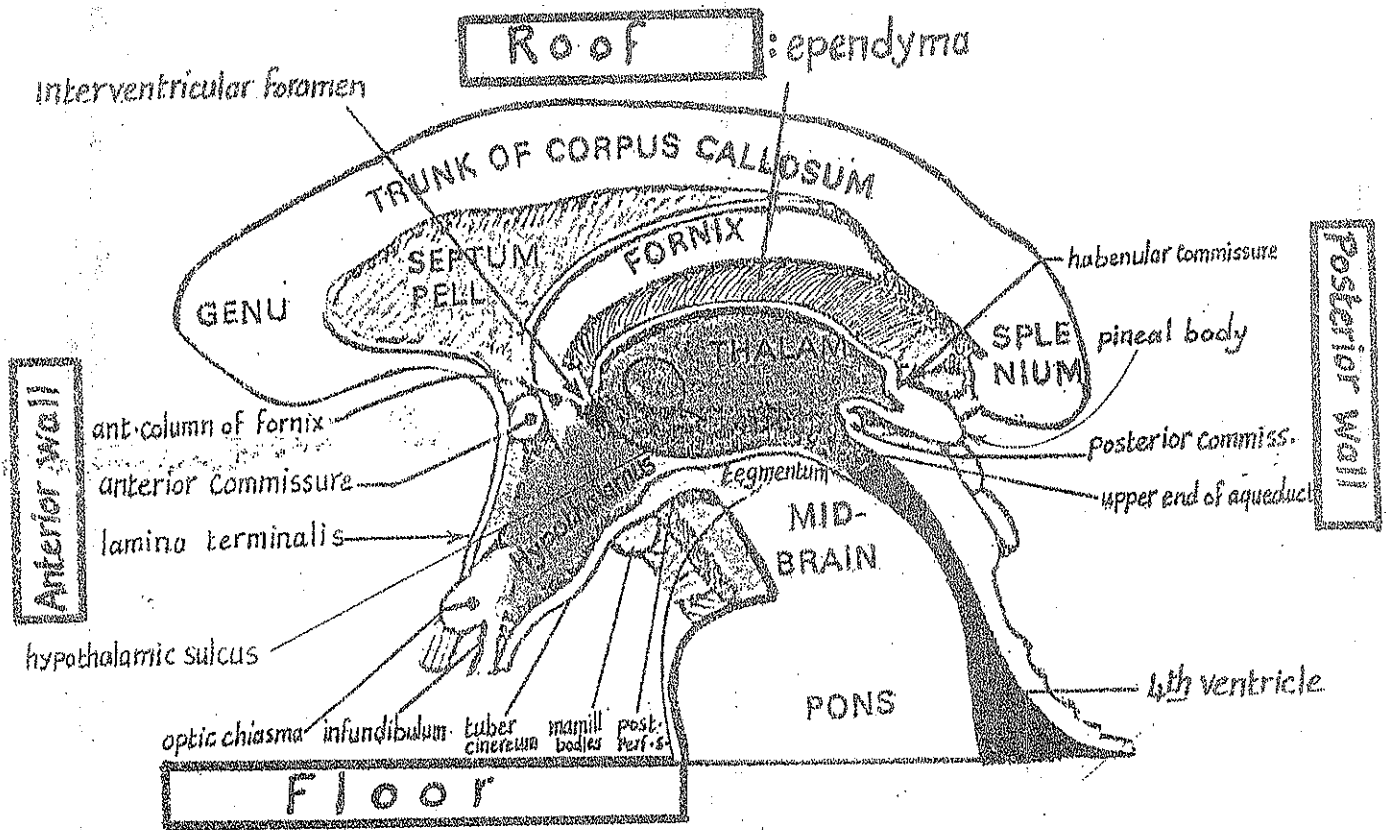
- laterally: the junctional zone between

the internal capsule & the cerebral peduncle of the midbrain.



\* Internal structure: see tractology page: 102

# Third Ventricle



\* Definition: it is the cavity of the diencephalon.

\* Shape & site: it is a slit like cavity lying in the median plane between the Rt & Lt. thalamus. It has an irregular outline.

\* Communications:

(1) antero superiorly, on each side, it communicates with each lat. ventricle by an interventricular foramen which is bounded anteriorly by the ant. column of the fornix & bounded posteriorly by the ant. end of the thalamus.

(2) Postero inferiorly, in the median plane, it communicates with the 4<sup>th</sup> ventricle through the cerebral aqueduct.

\* Boundaries:

(1) Floor: formed:

- (a) anteriorly: by the hypothalamus
  - (b) posteriorly: by tegmentum of midbrain.
- (1) optic chiasma.
  - (2) infundibulum & tuber cinereum.
  - (3) mamillary bodies.
  - (4) post-perforated substance.

(2) Roof: Formed by ependyma lining the undersurface of the tela choroidea.

It stretches between the 2 thalami extending from the interventricular foramen anteriorly to the habenular commissure posteriorly & is invaginated by the choroid plexus of the 3<sup>rd</sup> ventricle.

(3) Anterior wall: formed of the following structures from above downwards: 42

- (a) the 2 ant. columns of the fornix as they descend to reach the mamillary bodies.
- (b) the ant. commissure as it crosses the median plane just in front of the ant. columns of the fornix.
- (c) the lamina terminalis stretching from the rostrum of corpus callosum to the optic chiasma. It represents the cephalic end of the primitive neural tube.

(4) Posterior wall: formed of the following structures from above downwards:

- (a) the habenular commissure.
- (b) pineal body.
- (c) post. commissure.
- (d) the upper end of the aqueduct of the midbrain.

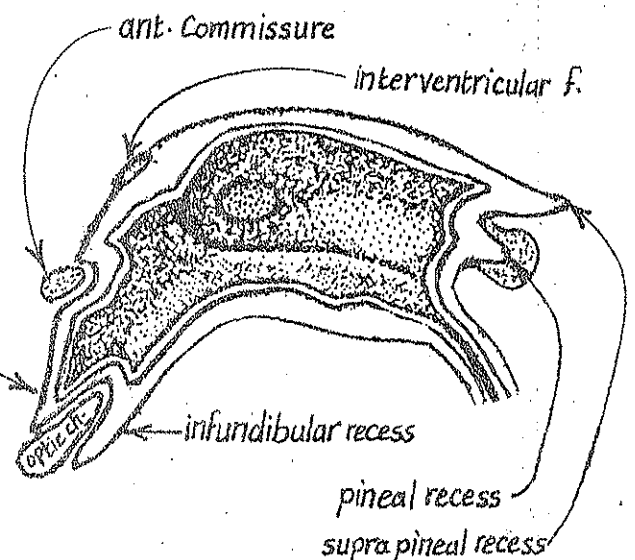
(5) Lateral Wall: Formed by:

- (a) the medial surface of the thalamus in its postero superior part.
- (b) the hypothalamus in its anteroinferior part.
- (c) the hypothalamic sulcus which separates the thalamus from the hypothalamus. The sulcus extends from the interventricular foramen to the cerebral aqueduct.
- (d) the interventricular foramen in the most ant. part of the lat. wall (at the junction of the roof with the ant. & lat. walls).

N.B: the interthalamic adhesion connects the medial surfaces of the 2 thalami across the ventricular cavity.

\* Recesses of the 3rd ventricle:

- (1) optic recess: just above & in front of the optic chiasma.
- (2) Infundibular recess: into the infundibulum.
- (3) Supra-pineal recess: just above the pineal body.
- (4) Pineal recess: into the stalk of the pineal body.



\* The 1<sup>st</sup> & 2<sup>nd</sup> nerves are attached to the Forebrain

\* The 3<sup>rd</sup> & 4<sup>th</sup> nerves are attached to the Midbrain

\* The middle 4 cranial nerves (5, 6, 7 & 8) are attached to the PONS.

\* The lower 4 cranial nerves (9, 10, 11 & 12) are attached to the Medulla.

## Details:

### (1) Olfactory n. (1<sup>st</sup> cranial n.):

- \* Consists of about 20 small filaments on each side.
- \* They arise from the olfactory mucosa & pass through the cribriform plate of ethmoid to end in the olfactory bulb.

### (2) Optic nerve (2<sup>nd</sup> cranial n.):

- \* it is not a true peripheral n. but a tract of the C.N.S.
- \* it consists of the axons of the ganglion cells of the retina.
- \* it ends by joining the anterolateral aspect of the optic chiasma.

### (3) Oculomotor n. (3<sup>rd</sup> cranial n.):

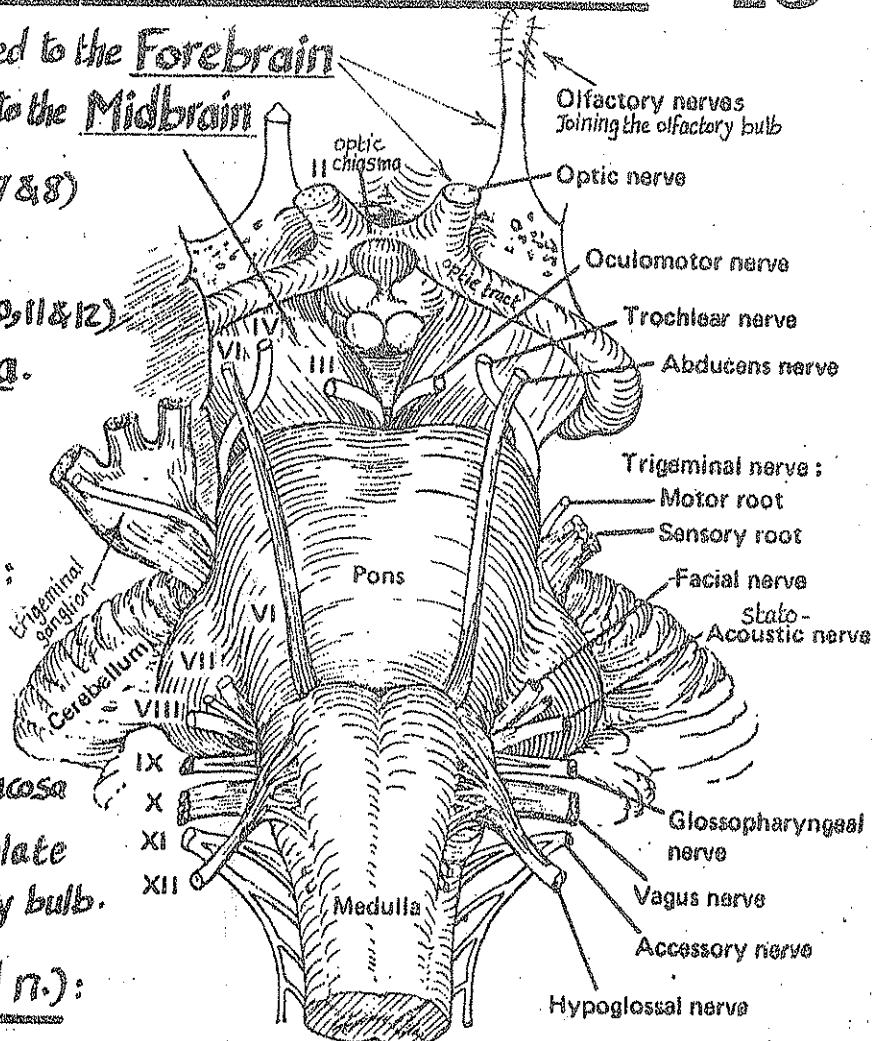
it emerges from a groove on the medial aspect of the cerebral peduncle of midbrain.

### (4) Trochlear n. (4<sup>th</sup> cranial n.):

- \* it is the smallest cranial n. & the only n. which is attached to the dorsal aspect of the brain stem.
- \* it emerges from the post. surface of the midbrain just below the inf. colliculus.
- \* it pierces the sup. medullary velum then winds round the lat. aspect of the midbrain just above the pons to reach the interpeduncular fossa.

### (5) Trigeminal n. (5<sup>th</sup> cranial n.):

- \* it is the thickest cranial n. & arises by 2 roots
- \* the 2 roots are attached to the lat. aspect of the pons (at its junction with the M.C.P.)



## (6) Abducent n. (6<sup>th</sup> cranial n.):

44

emerges at the lower border of the pons (from the groove between the pons & the pyramid of the medulla close to the middle line).

## (7) & (8) The Facial (7<sup>th</sup>) & Vestibulocochlear (8<sup>th</sup>) Cranial nerves:

both emerge from the lower border of the pons at the ponto-cerebellar angle (the angle between the M.C.P., the medulla & the cerebellum).

N.B: (a) the facial n. lies medial in position & is formed of 2 roots → Facial n. proper (motor)  
nervus intermedius (sensory & parasympathetic).

(b) the Vestibulo-cochlear n. lies lat. in position & is formed of 2 roots → Cochlear (for hearing).  
vestibular (for equilibrium).

## (9) Glossopharyngeal (9<sup>th</sup>) Cranial n.:

arises by 4-5 rootlets from the posterolateral sulcus of medulla (the groove between the olive & the I.C.P.).

## (10) The Vagus (10<sup>th</sup>) Cranial n.:

arises by 10 rootlets from the posterolateral sulcus of medulla (below the rootlets of the glossopharyngeal n.).

## (11) The Accessory (11<sup>th</sup>) Cranial n.: has 2 roots:

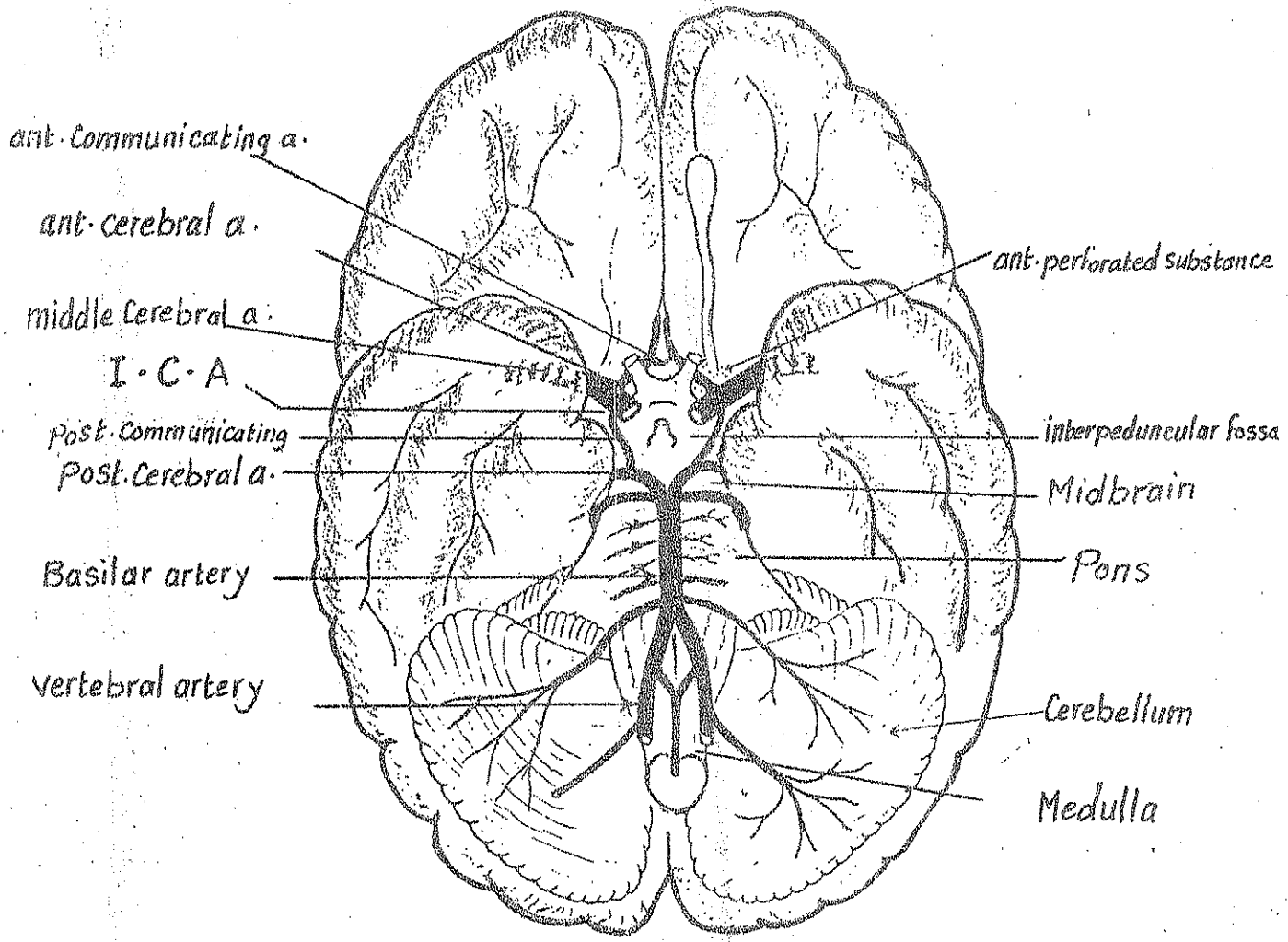
(a) cranial root: arising from the posterolateral sulcus of medulla by 5-6 rootlets lying below the attachment of the vagus n.

(b) spinal root: arises from the upper 5 or 6 cervical segments of the spinal cord. It ascends through the f. magnum to join the cranial root forming together the accessory n.

## (12) The Hypoglossal n. (12<sup>th</sup> cranial n.):

arises by 12 rootlets from the anterolateral sulcus of medulla (the groove between the pyramid & the olive).

\* Deep origin (nuclei) of the Cranial nerves: see page 103



- The Brain is supplied by 2 pairs of arteries
- (A) Rt. & Lt. Internal Carotid Artery (I.C.A).
- (B) Rt. & Lt. vertebral arteries.

## (A) Internal Carotid artery (I.C.A)

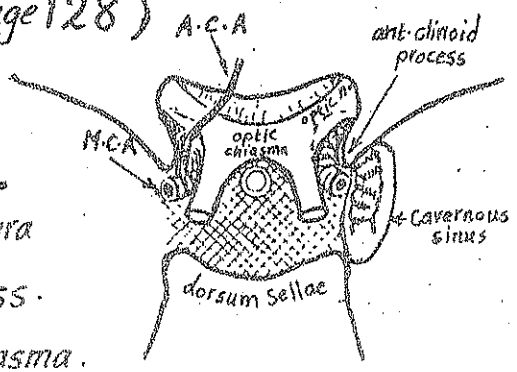
Origin: arises in the neck as one of the 2 terminal branches of the C.C.A

Course: the I.C.A has 4 parts :

- (1) cervical part
  - (2) Intrapetrous part
  - (3) Intracavernous part
- } See Head & Neck (page 128)

### (4) Intracranial part of I.C.A

Each I.C.A leaves the Cavernous sinus by piercing the dura mater & arachnoid mater, med. to the ant. clinoid process. & ascends in the subarachnoid space lat. to the optic chiasma.





\* In the subarachnoid space each I.C.A gives off the following branches: **46**

- (1) Ophthalmic a. which enters the optic canal below the optic n. to supply the orbit.
- (2) post. communicating a. which joins the post. Cerebral a. to establish the Circle of Willis
- (3) ant. choroidal a. : which supplies the choroid plexus of the lat. ventricle.

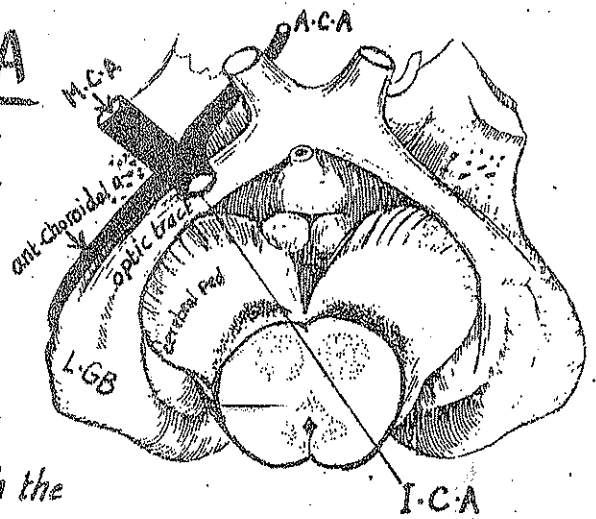
\* It ends below the ant. perforated substance of the brain by dividing into 2 terminal branches:

- (1) the ant. Cerebral a. (the smaller branch)
- (2) the middle Cerebral a. (the larger branch & in line with the main trunk of the I.C.A)

## Branches of the I.C.A

### I - Anterior Choroidal a.:

- \* arises from the I.C.A just before it divides into its 2 terminal branches
- \* It passes backwards along the optic tract around the cerebral peduncle as far as the lat. geniculate body.
- \* It ends by entering the inf. horn of lat. ventricle through the lower part of the choroid fissure
- \* It supplies: the optic tract, L.G.B., internal capsule (post. part of post. limb, retro- & sublenticular part). It also supplies the choroid plexus of inf. horn of lat. ventricle

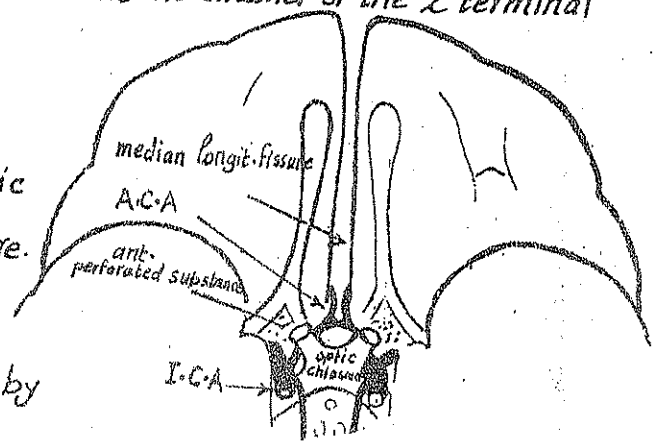


### II - Anterior Cerebral artery (A.C.A)

\* Origin: it arises below the ant. perforated substance as the smaller of the 2 terminal branches of the I.C.A

\* Course:

- it passes forwards & medially above the optic chiasma to reach the median longitudinal fissure.
- then it bends forwards in the fissure where it becomes joined to its fellow of the opposite side by the ant. communicating a.





- Then it turns sharply upwards in the median longitudinal fissure to reach the med. surface of the cerebral hemisphere where it lies below the rostrum of corpus callosum.

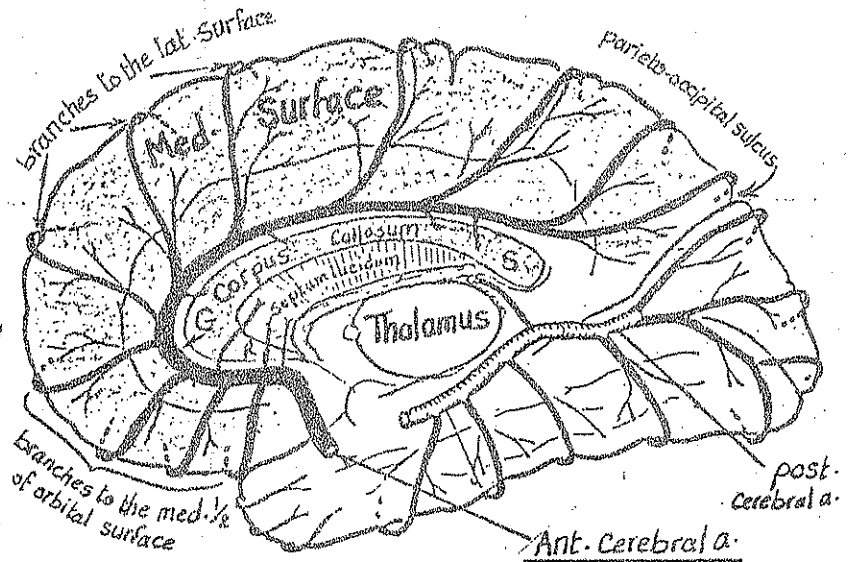
- It runs in the callosal sulcus, first curving upwards around the genu then passing backwards above the body of Corpus Callosum.

\* Termination: it ends above the splenium of C. callosum by turning upwards in front of the parieto-occipital fissure.

## \* Branches:

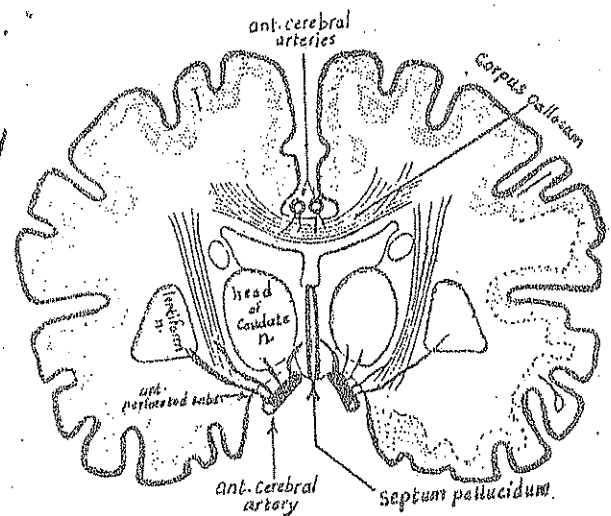
A) Cortical branches: to supply:

- (1) the medial surface of the hemisphere from the frontal pole to the parieto-occipital sulcus.
- (2) the upper 1" of the lat. surface as far as the upper end of parieto-occipital fissure.
- (3) the med. 1/2 of the orbital surface of the frontal lobe.



B) Central branches: pierce the ant. perforated substance & lamina terminalis to supply:

- (1) the ant. part of the Corpus striatum.
- (2) the ant. part of ant. limb of internal capsule.
- (3) the septal region including the Septum lucidum.



C) Callosal branches: to supply all parts of Corpus Callosum except the splenium (which is supplied by the post. Cerebral a.).

\* Clinical importance: the A.C.A. supplies 3 important regions:

- (1) The motor & sensory areas of the lower limb in the paracentral lobule.
- (2) The Septal region: where a small lesion may result in prolonged unconsciousness.
- (3) The Corpus Callosum: obliteration of its blood supply may result in apraxia (inability to perform purposeful movements inspite of intact muscles).

# Middle Cerebral Artery (M.C.A) 48

\*Origin: arises below the ant. perforated substance as the larger of the 2 terminal branches of I.C.A.

\*Course & relations:

- It passes laterally in the stem of lat. sulcus.
- then it turns backwards & upwards in the post. ramus of the lat. sulcus crossing over the insula.

\*End: it ends on the surface of the insula by breaking up into many terminal branches.

\*Branches of the M.C.A

I- Cortical branches: supply 1, 2 & 3:

(1) The whole lat. surface of the C. hemisphere EXCEPT:

- (a) a narrow strip (1" in breadth) along the sup. border (which is supplied by the A.C.A).
- (b) the lat. surface of the occipital lobe + a narrow strip on the lat. surface of temporal lobe close to the inf. border. (which are supplied by the Post. Cerebral artery).

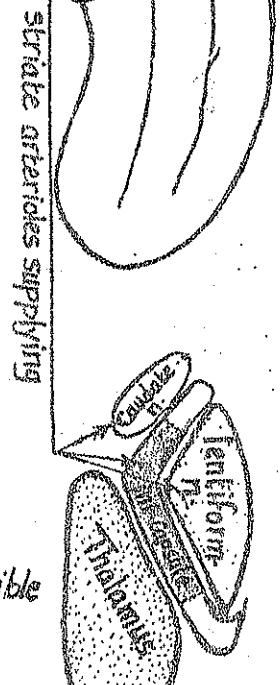
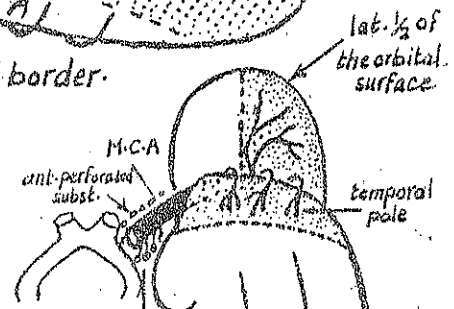
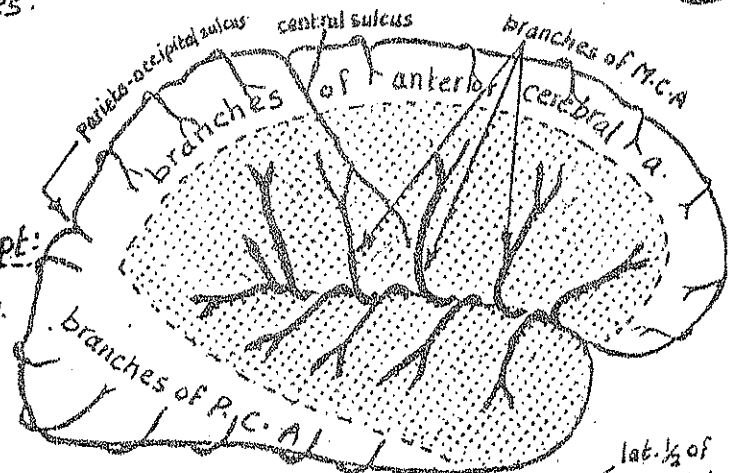
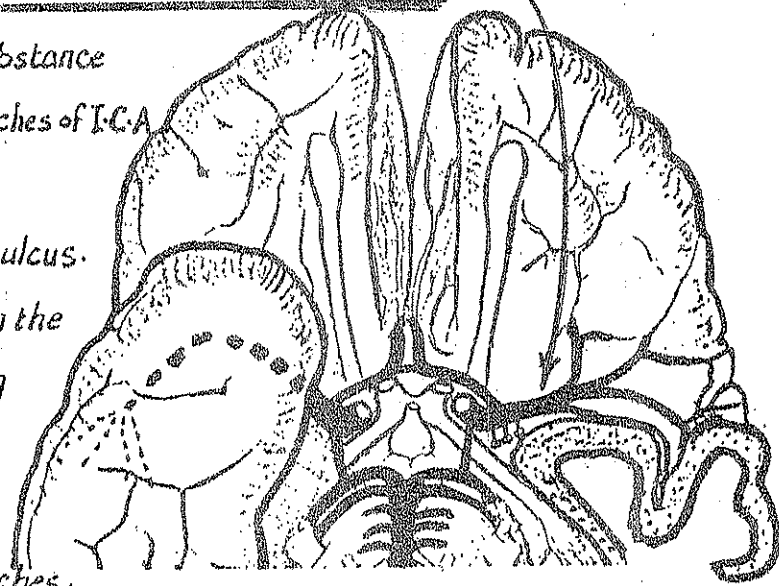
(2) the lat. 1/2 of the orbital surface of the C. hemisphere.

(3) the temporal pole & the insula.

II- Central branches: are many branches called striate arterioles which arise from the M.C.A near its origin & penetrate the ant. perforated substance to supply:

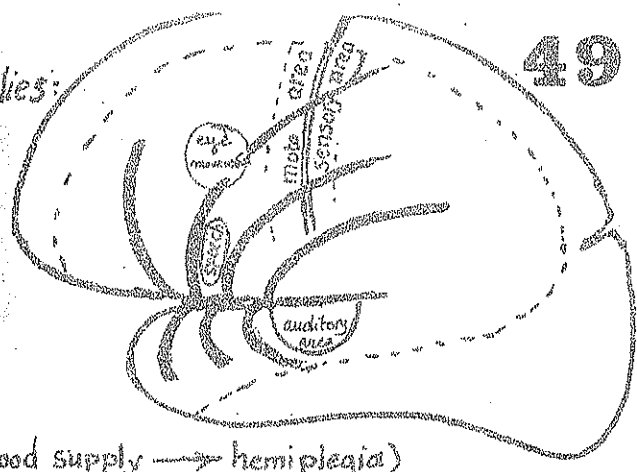
- (1) the Corpus striatum (lentiform & Caudate)
- (2) the post. 1/2 of ant. limb, genu & the ant. part of the post. limb of the internal capsule.

NB one of the Central branches is larger than the others & is called the artery of cerebral haemorrhage (Charcot's artery) as it is the most susceptible artery in the brain to rupture.



\* Clinical importance of M.C.A : it supplies:

- (1) the motor & sensory areas for the whole body except the lower limbs.
- (2) the auditory area in the sup. temporal gyrus.
- (3) Motor speech area in the inf. Frontal gyrus.
- (4) Most of the internal Capsule (obstruction of its blood supply → hemiplegia)



The Vertebro-basilar System

1-Vertebral artery

Origin: Each vertebral a. arises in the root of the neck as a branch from the 1<sup>st</sup> part of subclavian a.

Course:

- The Rt. & Lt. vertebral arteries enter the cranial cavity through the foramen magnum.
- Inside the skull, the vertebral aa. pass upwards, forwards & medially in the subarachnoid space to reach the ant. aspect of medulla oblongata.

Termination: the 2 vertebral arteries unite at the lower border of the pons to form the basilar a.

Branches:

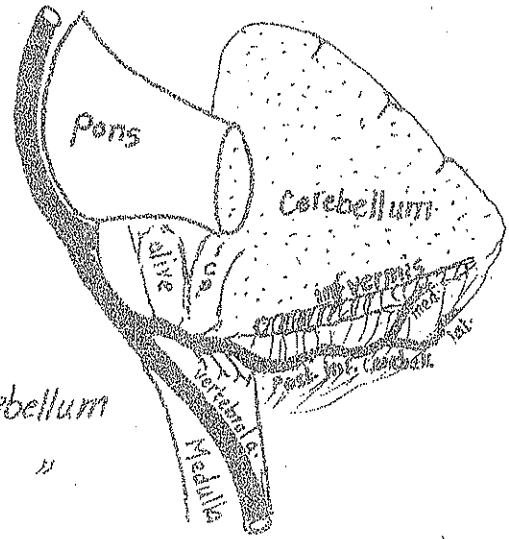
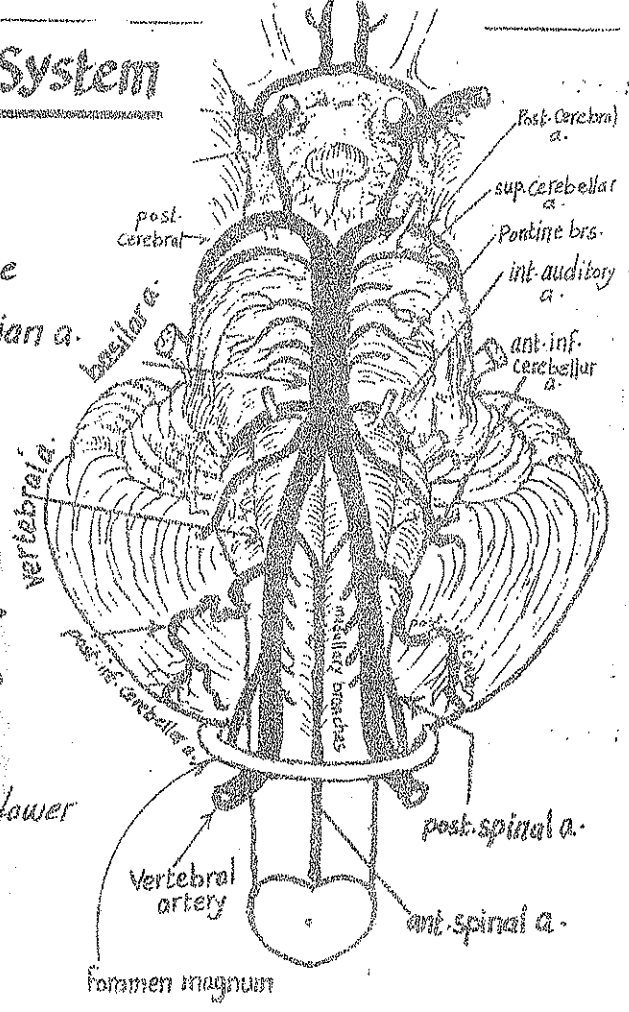
Posterior inferior cerebellar a. :

it is the largest & the main branch of the vertebral a.

Course: it runs backwards around the medulla just below the olive & the inf. cerebellar peduncle to reach the inf. surface of the cerebellum where:

ends: by dividing into 2 terminal branches:

- 1) a med. terminal br. : supplying the inf. vermis of the cerebellum
- 2) a lat. terminal br. supplying the post. part of inf. surface of "



\* Clinical importance : the post. inf. cerebellar a supplies also the lat. & dorsal parts of the medulla which contain the spinal lemniscus, the nucleus ambiguus & the spinal nucleus of trigeminal n. Thrombosis of the artery causes loss of function of these structures (called lat. medullary syndrome).

## (2) Posterior spinal a.

- it is the 1st branch of vertebral a. inside the cranial cavity.
- it descends to the spinal cord along the line of the post. roots of the spinal nerves.

## (3) anterior spinal a. (the longest a. in the body) :

- arises from the upper most part of the vertebral a.
- the 2 ant. spinal arteries unite in front of the medulla to form a single median ant. spinal a. which descends along the ant. median longitudinal sulcus of the spinal cord down to the filum terminale. It supplies the ant. part of the medulla & the spinal cord

## (4) Medullary branches : to supply the medulla.

# 2-Basilar Artery

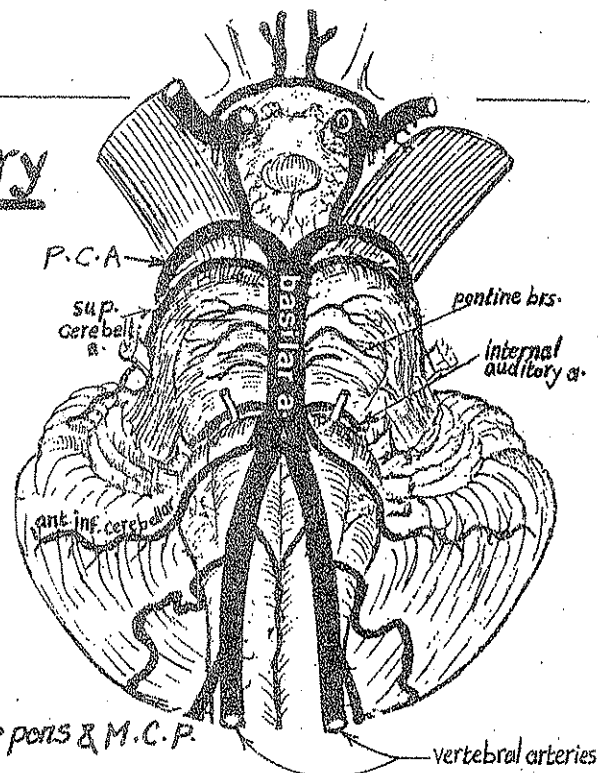
\* It begins : at the lower border of pons by the union of the 2 vertebral arteries.

\* Course : it ascends along the basilar sulcus in front of the pons.

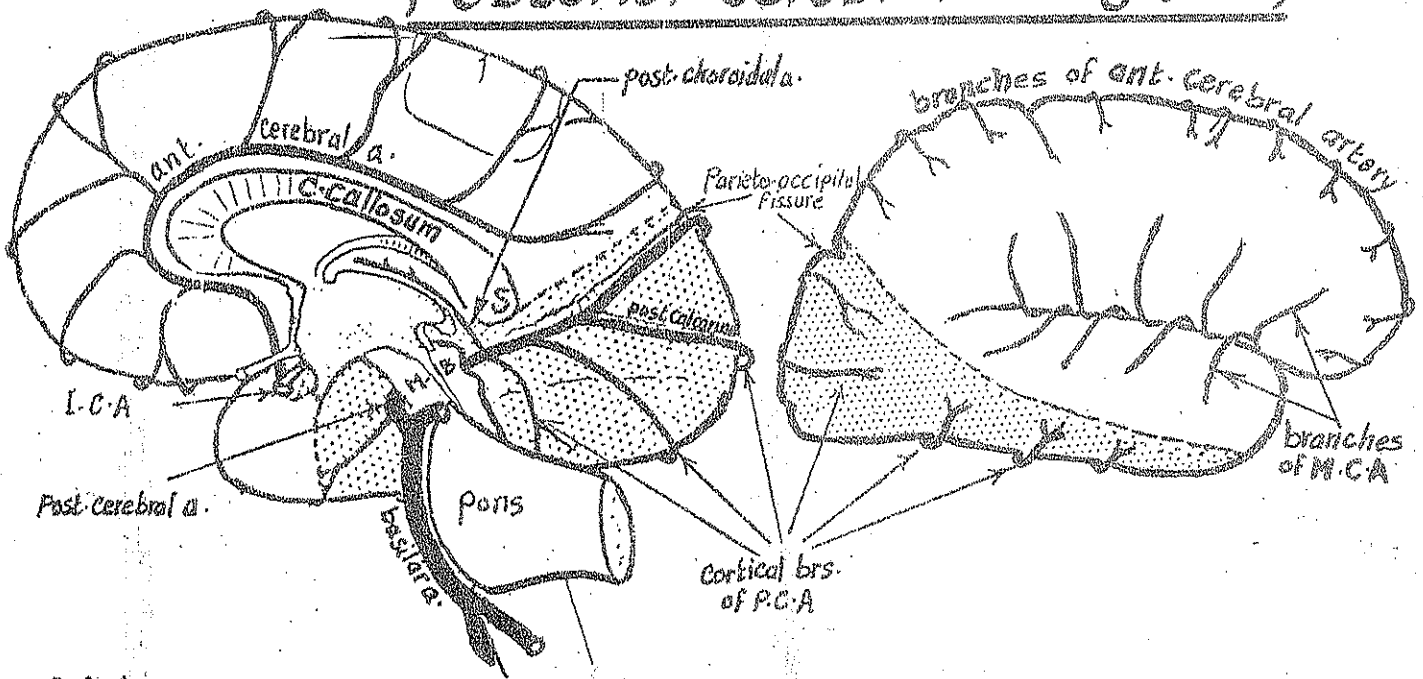
\* It ends at the upper border of the pons by dividing into 2 post. Cerebral arteries.

## \* Branches :

- (1) Pontine branches : numerous small twigs supplying the pons & M.C.P.
- (2) ant. inf. cerebellar a. : passes posterolaterally around the lower border of the pons to supply the ant. part of the inf. surface of the cerebellum.
- (3) Internal auditory a. : accompany the 7th & 8th cranial nerves through the internal auditory meatus to supply the internal ear.
- (4) Sup. cerebellar a. : a large br. arising from the upper part of the basilar a. It passes posterolaterally around the upper border of the pons to reach the upper surface of the cerebellum supplying it.
- (5) 2 Post-Cerebral arteries : are the 2 terminal branches.



# Posterior Cerebral Artery (P.C.A) 51



\*Origin : the Rt. & Lt. post. cerebral a.a. arise at the upper border of the pons as the 2 terminal branches of the basilar a.

## \*Course:

- each P.C.A. curves laterally & backwards around the cerebral peduncle of the midbrain parallel to the sup. cerebellar a.
- it then passes below the splenium of corpus callosum on the med. surface of the Cerebral Hemisphere.
- finally it enters the ant. part of the Calcarine sulcus where,

\*it ends : by dividing into 2 terminal branches which run in the parieto-occipital fissure & in the post. part of the Calcarine sulcus.

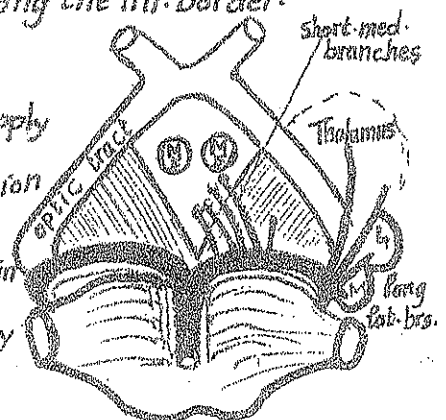
\*Branches :  $\left\{ \begin{array}{l} \text{Central branches.} \\ \text{Cortical} \\ \text{post. choroidal a.} \end{array} \right.$

(A) Cortical branches : to supply :

- (1) the tentorial surface behind the temporal pole.
- (2) the med. & lat. surfaces of the occipital lobe.
- (3) a narrow strip on the lat. surface of the temporal lobe along the inf. border.

(B) Central Branches:

- (1) Short med. group : pierce the post. perforated substance to supply the cerebral peduncles, the mammillary bodies, the subthalamic region & the ant. part of the thalamus.
- (2) Long lateral group : curve around the lat. side of the midbrain to supply the geniculate bodies, post. part of thalamus & pineal body

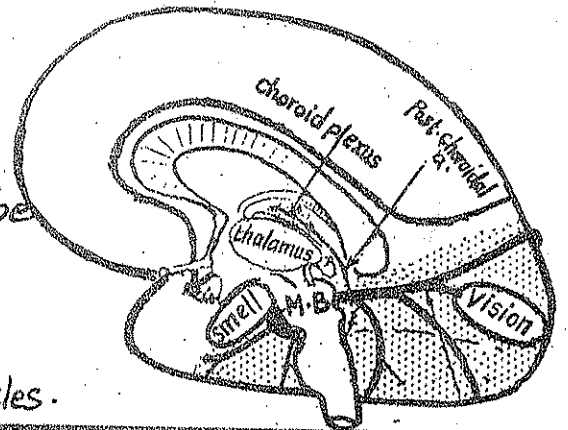


(C) The post-choroidal a.:

- arises below the splenium of corpus callosum.
- passes forwards inside the brain in the edge of tela choroidae to supply the choroid plexuses of the lat. & third ventricles.

\* Clinical importance of P.C.A.: it supplies:

- (1) the centre of smell in the uncus.
- (2) the whole visual cortex in the occipital lobe.
- (3) most of the thalamus.
- (4) most of the midbrain.
- (5) most of the choroid plexus of the 3rd & lat. ventricles.



Circulus arteriosus of Willis

\* Definition: it is an arterial anastomosis between 9 arteries supplying the brain.

\* Site: in the interpeduncular cistern around the interpeduncular fossa.

\* Relations:

- inferiorly:
  - optic chiasma (in front).
  - cavernous sinus (on each side).
  - dorsum sellae (behind).

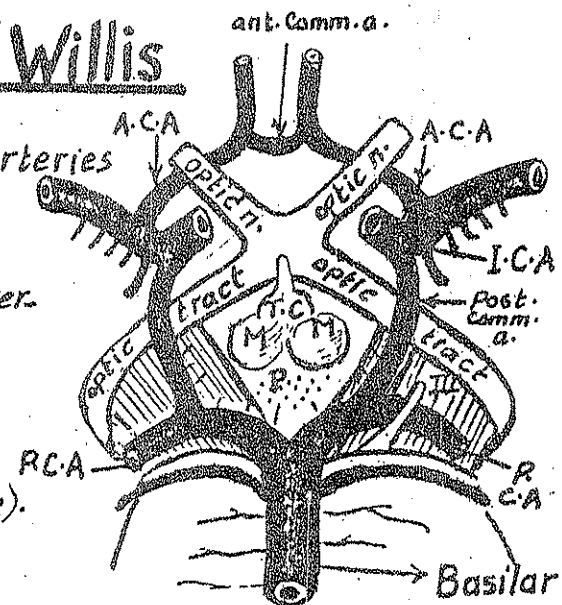
- superiorly the circle of Willis surrounds the following structures

(from before backwards):

- (1) pituitary stalk.
- (2) the tuber cinereum.
- (3) the mammillary bodies.
- (4) the post-perforated substance.

\* Formation: The following arteries enter in the formation:

- Rt. & Lt. anterior cerebral arteries.
- the ant. communicating a. connecting the 2 ant. cerebral arteries.
- the Rt. & Lt. int. Carotid arteries.
- the Rt. & Lt. post. Communicating aa.
- the Rt. & Lt. post. Cerebral arteries.

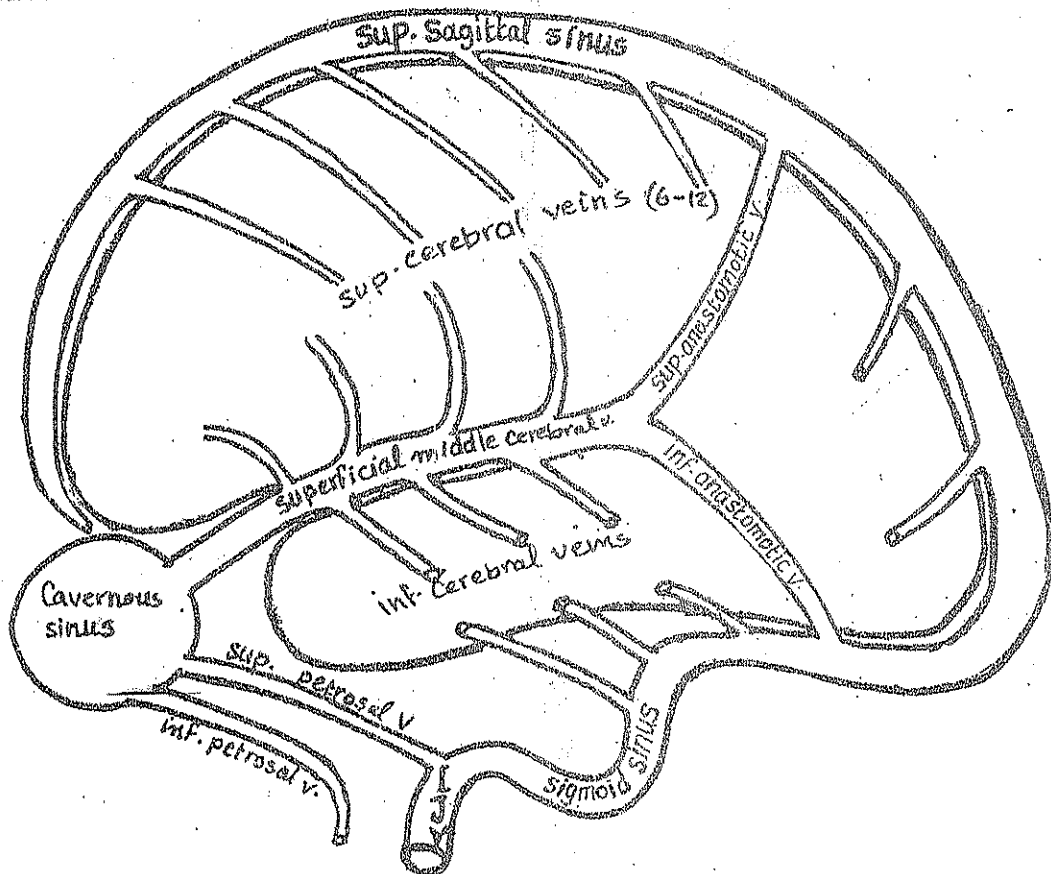




## Characters:

- (1) They are thin walled with no smooth muscle fibres & no valves
- (2) Most of them lie on the surface of the hemisphere (in the subarachnoid space).  
Only few veins arise from the inside of the brain.

## (1) Veins of the lat. surface of the hemisphere



Sup. cerebral veins: 6-12 veins which run upwards to end in the sup. sagittal sinus.

### Inf. cerebral veins:

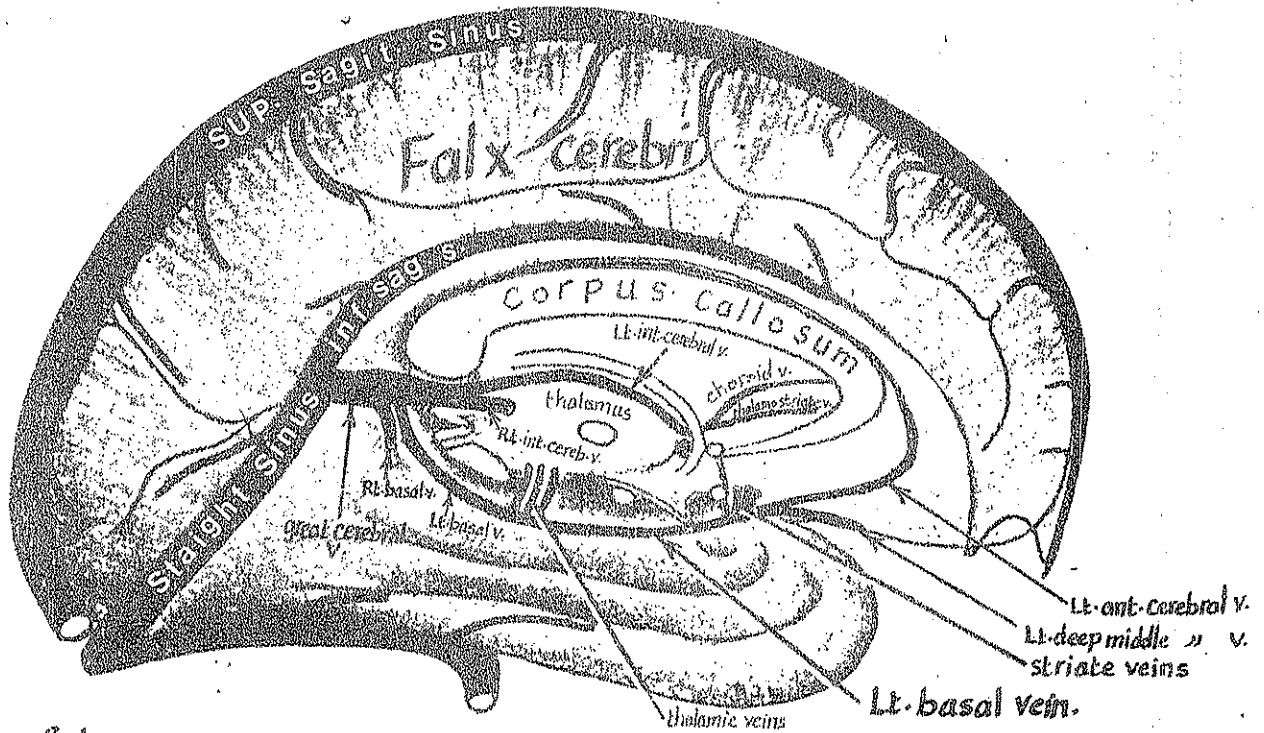
- the majority of these veins end in the superficial middle cerebral v. which lies in the stem of the lat. sulcus & ends in the Cavernous sinus.
- Some inf. cerebral veins end in the transverse sinus.

V.B in many cases, a sup. anastomatic vein connects the post. end of the superficial middle cerebral vein with the sup. sagittal sinus. Also an inferior anastomatic v. connects the superficial middle cerebral v. with the transverse sinus.



## (2) Veins of the medial surface of the hemisphere

54



- (a) the veins of the upper part of the med. surface ascend to end in the sup. & inf. sagittal sinuses.
- (b) the veins of the lower part of the med. surface drain into the ant. cerebral v. which lies in the callosal sulcus (accompanying the ant. cerebral artery) & ends in the basal v.
- N.B: each of the Rt. & Lt. basal vein lies on the base of the brain, & is formed below the ant. perforated substance by the union of the following 3 veins:
- (a) ant. cerebral v. which accompanies the ant. cerebral a. on the med. surface.
- (b) the deep middle cerebral v. which runs on the surface of the insula accompanying the middle cerebral a.
- (c) striate veins which drain the corpus striatum & come out through the ant. perforated substance.

## (3) The deep veins of the brain

(a) Internal cerebral veins (Rt. & Lt.): each vein is formed near the inter ventricular f. by the union of 2 veins:

- (1) choroid v. draining the choroid plexus of the lateral ventricle.
- (2) thalamostriate v. running in the groove between thalamus & caudate nucleus.

The Rt. & Lt. internal cerebral veins pass backwards in the roof of the 3rd ventricle (between the 2 layers of the tela choroidea) to end just below splenium of C. Callosum by joining each other to form the great cerebral vein.

(b) Great cerebral v.:

- it is a short median v. formed by the union of the Rt. & Lt. internal cerebral veins.
- it emerges from beneath the splenium of the corpus callosum.
- it receives the Rt. & Lt. basal veins.
- it ends by joining the inf. sagittal sinus to form the straight sinus.

# The Meninges of the brain

55

The brain is surrounded by 3 membranes, from inside outwards they are:

- (1) pia mater
- (2) arachnoid mater
- (3) dura mater

## The Pia mater :

- It is a delicate vascular membrane forming the inner most covering membrane of the brain.
  - It closely surrounds the brain & is carried into all sulci by the branches of the Cerebral arteries.
  - It is invaginated below the body of the fornix to form a double fold called the tela Choroidea in which the choroid plexuses of the 2 lat. ventricles & the 3rd ventricle are formed.
- It sends tubular sheaths around the cranial nerves in the cranial cavity.

## Arachnoid mater :

- It is a thin delicate membrane lying outside the pia mater.
- It covers the gyri & bridges over the sulci of the brain. It is only carried into the median longitudinal fissure by the falx cerebri.
- It sends tubular sheaths around the cranial nerves till their points of exit from the skull.
- It forms small masses called arachnoid villi (microscopic) & arachnoid granulations (macroscopic) which project into the sup. sagittal & transverse sinuses pouring the C.S.F into them.
- It is separated from the pia mater by a narrow space called the subarachnoid space containing C.S.F, the blood vessels on the outer surface of the brain & reticulum of fine fibres connecting the arachnoid mater to the pia mater.

## The Subarachnoid Cisterns:

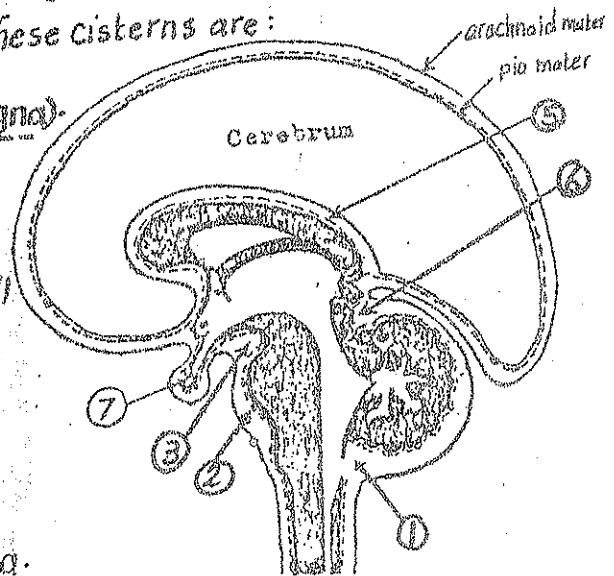
These are areas in which the arachnoid & pia are widely separated from each other leading to widening of the subarachnoid space. These cisterns are:

### (1) Cerebello-medullary Cistern (cisterna magna)

- lies between the back of the medulla & the inferior surface of the cerebellum.
- it communicates with the 4th ventricle by 3 small openings through which the C.S.F drains from the 4th ventricle to this cistern.

### (2) The pontine Cistern:

lies in front of the pons & upper part of medulla.



- It contains the vertebral & basilar arteries.
- It is traversed by the roots of the lower 8 cranial nerves.

### (3) The Interpeduncular Cistern:

- lies below the interpeduncular fossa
- It contains the arteries forming the Circulus arteriosus of Willis.
- It is traversed by the roots of the 3rd & 4th cranial nerves.

### (4) Cistern of lateral sulcus:

- It is an extension of the interpeduncular cistern into the stem of the lat-sulcus.
- It contains the middle cerebral a.

### (5) The Cistern of Corpus Callosum:

- lies on the upper surface of Corpus Callosum
- Contains the ant. Cerebral a.

### (6) the Cistern of the great Cerebral v.:

- lies between the splenium of Corpus Callosum & the upper surface of the cerebellum
- it contains the great cerebral v.

### (7) the Chiasmatic Cistern: lies around the optic chiasma.

## III- The Dura mater :

- \* It is a thick membrane forming the outermost covering of the brain.
- \* It consists of 2 layers : outer & inner
  - (1) outer (endosteal) layer : lines the inner surface of the skull bones.
  - (2) Inner (meningeal) layer :
    - Surrounds & protects the brain
    - sends tubular extensions around the cranial nerves which fuse with the epineurium of the nerves outside the skull
    - Sends 4. Septa inwards (Falx Cerebri, Falx Cerebelli, tentorium cerebelli & diaphragma sellae) which divide the cranial cavity into compartments.
- \* The 2 layers of the dura are fused together except in certain places where they separate to form the venous sinuses

# The Cerebro-Spinal Fluid (C.S.F)

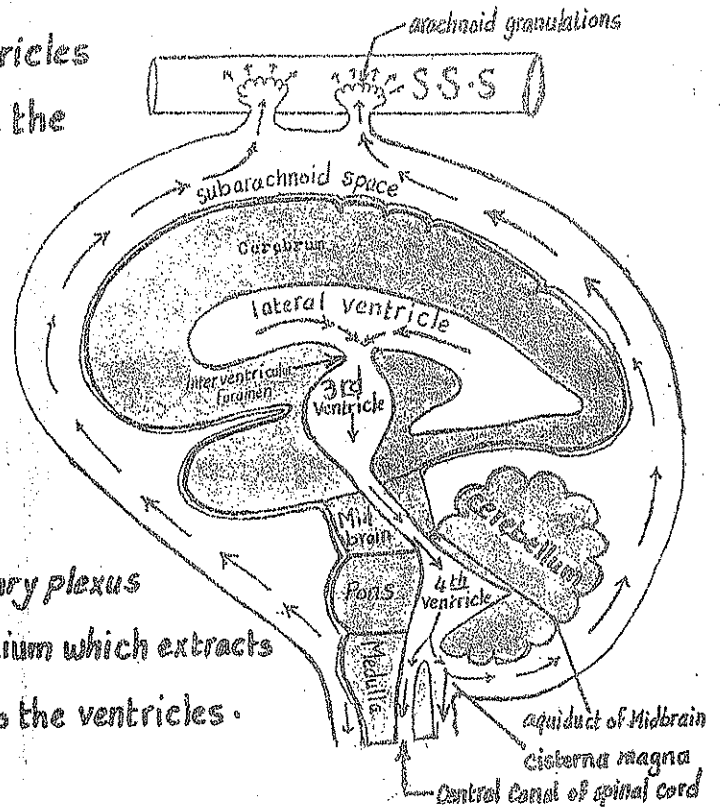
57

\* It is the fluid which circulates in the ventricles & central canals of the C.N.S and also fills the subarachnoid space & cisterns.

## (1) production of the C.S.F:

- it is secreted by the choroid plexuses present in the med. walls of the lat. ventricles, roofs of the 3rd ventricle & 4th ventricle.

- The Choroid plexus: is formed by a capillary plexus invaginating a single layer of cuboidal epithelium which extracts the fluid from the capillaries & secretes it into the ventricles.



## (2) Circulation:

the C.S.F in each lat. ventricle → interventricular foramen → 3rd ventricle  
 → aqueduct of midbrain → 4th ventricle → some fluid enter the central canal of S. Cord  
 → the majority passes through the 3 foramina in the roof of the 4th ventricle → subarachnoid space where it flows over the surface of the brain & spinal cord.

(3) Absorption of the C.S.F: the C.S.F. is absorbed by means of the arachnoid villi and granulations which absorb the C.S.F from the subarachnoid space & pours it into the dural venous sinuses particularly the sup. sagittal sinus to reach the blood stream.

## (4) Functions of the C.S.F:

- (a) it takes the place of the lymph in the C.N.S which is devoid of lymphatic vessels.
- (b) acts as a protective water cushion to the C.N.S against blows & shocks.
- (c) regulation of the intracranial pressure.

## (5) Characters of the C.S.F:

- (a) amount: 135 c.c.
- (b) replacement: it is continuously produced & absorbed at a rate of 400-500 c.c daily (i.e it is replaced 3 times per day).
- (c) Pressure: 100 mm. of water
- (d) appearance: Clear watery fluid.

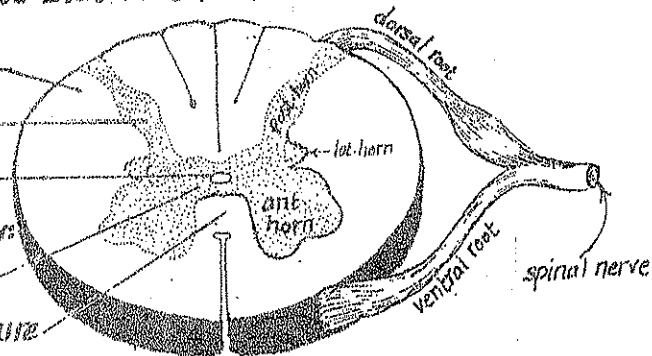
## 1- Internal Structure of the Spinal Cord

- A transverse section in the spinal cord shows that it is formed of:

- (1) outer white matter.
- (2) inner grey matter.
- (3) Central canal (1 mm. in diameter).

- The 2 halves of the spinal cord are connected by:

- (a) grey commissure containing the central canal.
- (b) white commissure in front of the grey commissure.



white

### (A) Grey matter

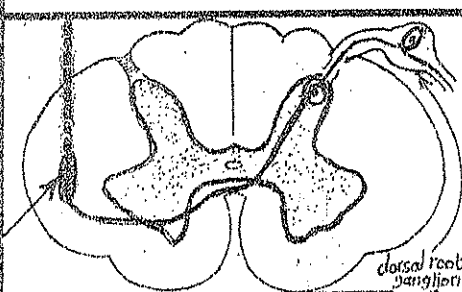
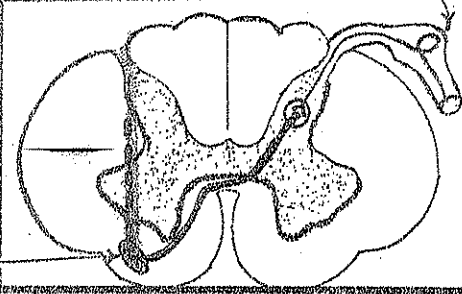
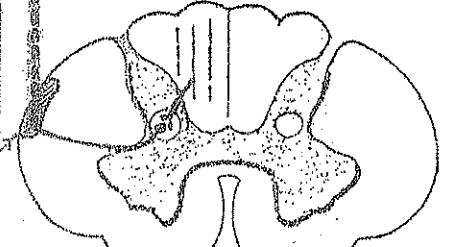
\* Structure: it consists of nerve cells & unmyelinated nerve fibres

\* Shape: H-shaped formed of:

- (a) anterior horns: containing motor nuclei.
- (b) 2 posterior horns: containing sensory nuclei → ? (Lumbar)
- (c) 2 lat-horns (in the thoracic & sacral regions): containing autonomic cells.

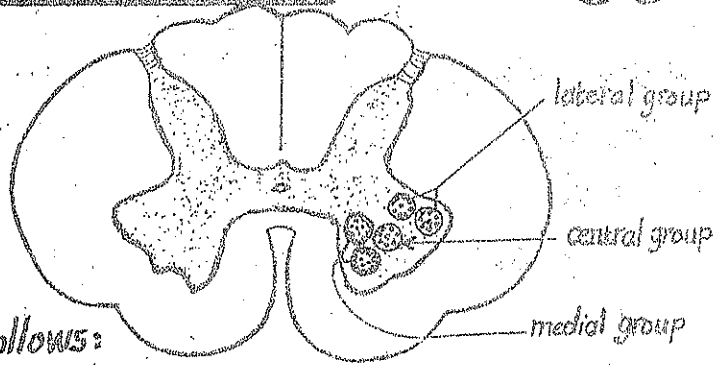
\* Nuclei of the grey matter:

### I-Nuclei of the post-horn (sensory)

Nucleus & site	afferents	efferents	
(1) <u>Substantia gelatinosa of Rolando (S.G.R)</u> at the apex of the post-horn	Pain & temperature impulses via central processes of dorsal root ganglion cells.	its axons cross to the opposite side in the white commissure & ascend in lat. white matter as the lat. spinothalamic T.	
(2) <u>Nucleus proprius</u> in the middle part of the post-horn	light pressure & crude touch impulses via central processes of dorsal root ganglion cells.	its axons cross to the opposite side in the white commissure then ascend in the ant. white matter as ant. spinothalamic T.	
(3) <u>Clark's dorsal nucleus</u> at the base of the post-horn (in the thoracic & upper	proprioceptive impulses via collaterals from the fibres of the post-column of white matter	its axons ascend in the lat. column of the same side forming the post. spino-cerebellar tract.	

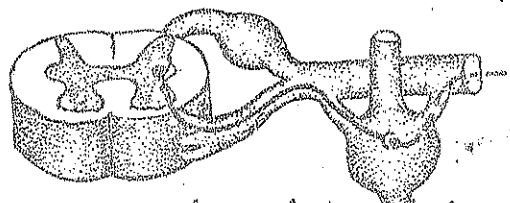
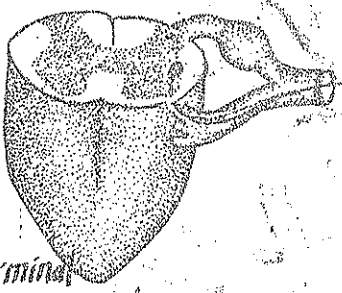
## II- Nuclei of the Ant-horn (motor)

- \* The ant-horn cells & their axons which run in the peripheral nerves the lower motor neurones (L.M.N).
- \* The A.H.Cs. are grouped into 3 groups of motor nuclei (med., lat. & central) as follows:



group	Afferent impulses	Efferent fibres (axons)
(1) <u>Medial group</u> (ventromed & dorsomed. nuclei) found in all segments of the spinal cord	<ul style="list-style-type: none"> <li>- pyramidal tract impulses</li> <li>- extra pyramidal " " "</li> <li>- proprioceptive impulses from muscles.</li> </ul>	run in the peripheral nerves supplying <u>trunk</u> muscles
(2) <u>Lateral group</u> (ventrolat. & dorsolat. nuclei) found in all segments of the spinal cord	<ul style="list-style-type: none"> <li>- From short associative tracts (for reflex arc).</li> </ul>	run in the peripheral nerves supplying the <u>limb</u> muscles
(3) <u>Central group</u> : only present in the <u>Cervical</u> region		its axons run in: (1) the <u>phrenic n.</u> (supplying the diaphragm) (2) <u>Spinal accessory n.</u> (supplying sternomastoid & trapezius mm.).

## III- Nuclei of the lat-horn (autonomic)

Nucleus	Afferent impulses	Efferent fibres
(1) <u>Sympathetic</u> present in the lat-horns of the segments from T1 to L2 or 3	via descending autonomic fibres arising from the hypothalamus & visceral centres in the brain-stem.	 <p>its axons leave the cord through the ventral roots of the corresponding nerves as pre-ganglionic fibres which relay in the corresponding ganglia of the sympathetic chain.</p>
(2) <u>Parasympathetic</u> present in the lat-horns of the 2nd, 3rd & 4th sacral segments of the spinal cord		 <p>its axons leave the cord through the ventral roots of the corresponding nerves as pre-ganglionic fibres which relay in terminal ganglia in the organs supplied.</p>



## B - The White Matter

60

\* It is divided into 3 large columns on each side :

(1) post. Column : lying between the post. median septum & the attachment of the dorsal nerve root.

It contains ascending tracts only.

(2) lateral column : lying between the attachments of the dorsal & ventral nerve roots. It contains both ascending & descending tracts.

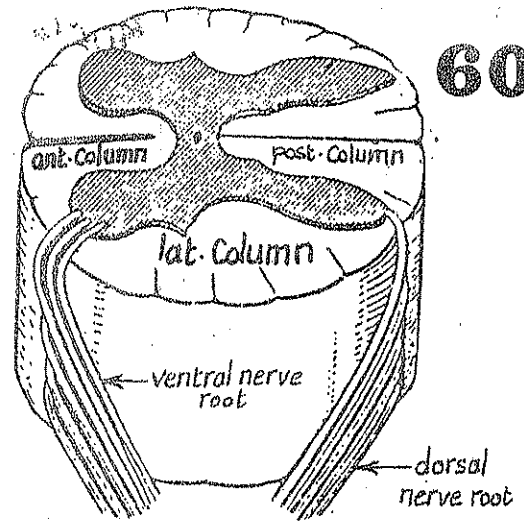
(3) anterior column : lying between the ant. median fissure & the attachment of the ventral nerve root. It contains descending tracts mainly.

\* Structure : the white matter contains 3 types of nerve fibres (tracts) :

(1) Ascending or afferent (sensory) tracts : Carrying sensory impulses from the spinal cord to higher centres (brain stem & C-cortex).

(2) descending or efferent tracts : carrying motor or autonomic impulses from higher centres to the spinal cord.

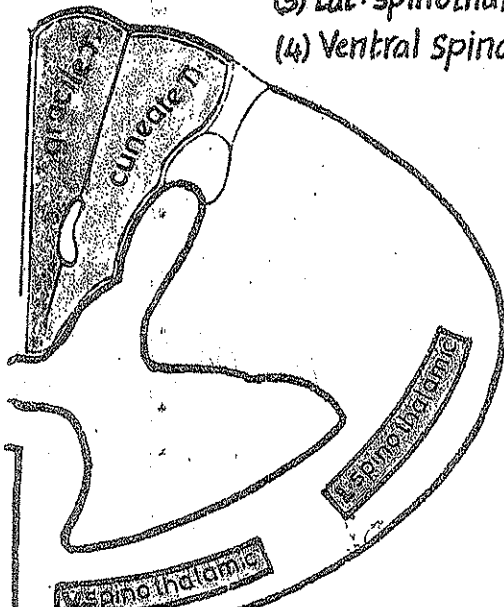
(3) associative tracts : containing short ascending & descending fibres which coordinate the function of the different regions of S-cord.



## I - Ascending tracts of the spinal cord

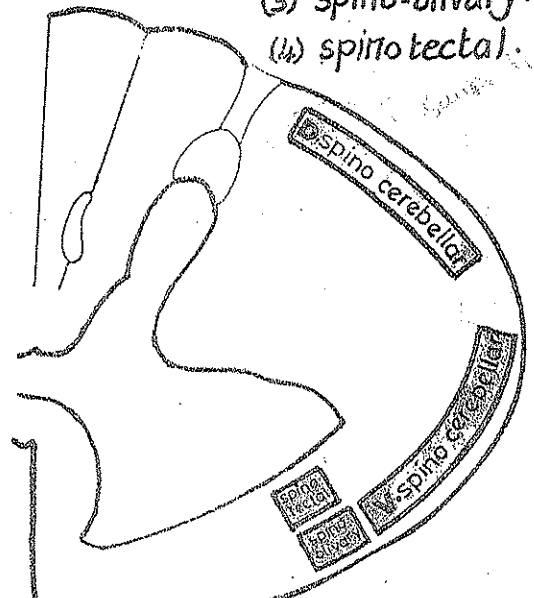
4 tracts carrying conscious sensations

- (1) Gracile
- (2) Cuneate
- (3) Lat. spinothalamic
- (4) Ventral spinothalamic



4 tracts carrying unconscious sensations

- (1) dorsal spinocerebellar
- (2) Ventral " "
- (3) spino-olivary
- (4) spino tectal





# 1- The 4 tracts which carry conscious sensations:

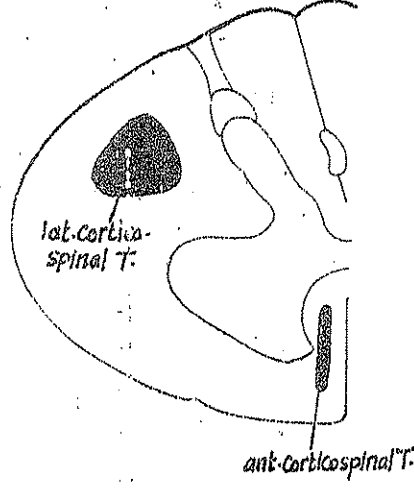
Tract & its position	Sensation carried	Origin	Termination	
(1) <u>Gracile T.</u> in the post-column close to the middle line.	proprioceptive & Fine touch sensations from lower 1/2 of the body.	cells of the post root ganglion whose central processes pass in the medial	gracile nucleus in closed medulla.	
(2) <u>Cuneate T.</u> in the post-column, lat. to the gracile T.	proprioceptive & fine touch sens. from the upper 1/2 of the body.	division of the post nerve root & ascend in the post-column of the spinal cord.	cuneate nucleus in closed medulla.	
(3) <u>Lat. spinothalamic T.</u> in the lat-column deep to the ventral spino cerebellar T.	Pain & temperature from all the body below the head.	axons of S-G-R which cross to the opposite side in front of the Central Canal	P.L.V.N. of thalamus	
(4) <u>Ant. spinothalamic T.</u> in the ant-column lying deep to the <u>Vestibulocerebellar T.</u>	crude touch & light pressure from the opposite 1/2 of the body below the head	axons of the nucleus proprius which cross to the opposite side.	P.L.V.N. of thalamus	

# 2- The 4 tracts which carry unconscious sensations:

Tract & its position	Sensations carried	Origin	Termination	
(1) <u>post-spinocerebellar T.</u> in the lat-column just lat. to Lissauer T.	proprioceptive sens. from the trunk & L-L to the cerebellum.	axons of Clark's nucleus of the same side	ipsilateral cerebellar hemi- sphere	
(2) <u>Ant. spinocerebellar T.</u> in the lat-column just in front of the post-spinocerebellar T.	proprioceptive impulses from the L-Limb to the cerebellum. (trunk & upper & lower limbs)	nucleus dorsalis axons of large cells at the base of the post-horn of the opposite side.	2 decussation. the fibres ascend till the midbrain, recross the middle line again to reach the ipsilateral cerebellar hemisphere	
(3) <u>Spino-olivary T.</u> in the lat-column alongside the olivospinal tract.	proprioceptive impulses	axons of the cells of the nucleus proprius which cross to the opposite side	in the inf. olivary nucleus then pass to the cerebellum via the olivo-cerebellar fibres	
(4) <u>spino-tectal T.</u> in the lat-column deep to the ventral spino- cerebellar T.	pain, temp. & touch impulses from spinal cord to the tectum of midbrain (serving spino-visual reflexes)	axons of the cells of the post-horn which cross to the opposite side.	in the sup. colliculus of the tectum of mid brain.	

## II- Descending tracts of the Spinal Cord

**(a) Pyramidal (page 68)**



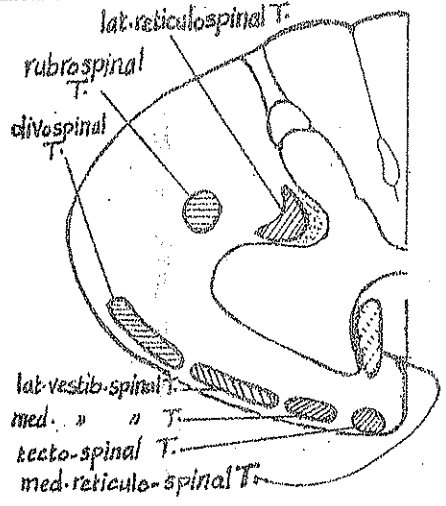
**(1) Lateral cortico spinal T.**

- \* Consists of crossed pyramidal fibres
- \* descends in the lat. Column of the spinal cord deep to the post spino-cerebellar tract.

**(2) Anterior cortico spinal T.**

- \* Consists of uncrossed pyramidal fibres
- \* descends in the ant. column alongside the ant. median fissure.
- \* ends at the midthoracic region

**(b) Extra pyramidal (page 70)**



**(1) rubrospinal T.:** descends in the lat. column just ant. to lat. corticospinal T.

**(2) olivospinal T.:** descends in the lat. column near the surface at the site of exit of the ventral roots.

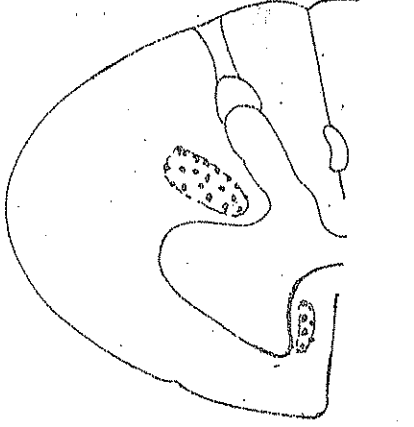
**(3) lat. reticulospinal T.:** descends in the lat. column deep to the rubrospinal T.

**(4) Tectospinal T.:** descends in the ant. column superficial to the ant. corticospinal T.

**(5) Vestibulospinal tracts:** descend close to the surface of the ant. column as small med. vest. spinal T. (partly crossed) & larger lat. vest. spinal T. (uncrossed)

**(6) med. reticulospinal T.:** descends as scattered fibres in the med. part of ant. column

**(c) descending autonomic**



\* They arise from autonomic centres in the hypothalamus & brain stem.

\* they descend in:

- (a) the lat. column (in close relation to the lat. reticulospinal, rubrospinal & lat. corticospinal tracts)
- (b) in the ant. column in close relation to the med. reticulo-spinal T.

\* they end on the autonomic cells of the lat. horn of:

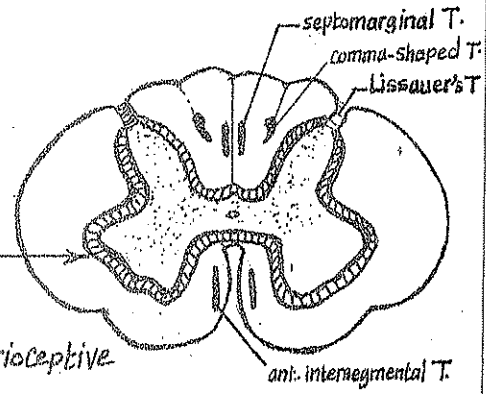
- (a) thoracic segments.
- (b) upper 2 lumbar segments.
- (c) 2nd, 3rd & 4th sacral

## III- Intersegmental tracts

\* They are short ascending & descending fibres which connect the various segments together to integrate their activities. They include:

- (1) Fasciculi proprii: lie just outside the grey matter surrounding it like ring.
  - (2) Septomarginal T.
  - (3) Comma-shaped T.
- } are present in the post. column & contain proprioceptive associative fibres.

- (4) ant. intersegmental T.: in the ant. column. it is continuous with the med. longitudinal bundle of the brainstem
- (5) Lissauer's T.: is a short tract at the apex of the post. horn formed of very short ascending & descending fibres



# The great afferent (sensory) pathways

63

## \* General rules :

(A) Conscious sensations include 2 types :

- (a) exteroceptive sensations : are sensations from the skin (pain, temperature & touch).
- (b) proprioceptive sensations : are sensations from muscles, joints, ligaments & fascia (sense of position, passive movement & vibrations).

(B) All conscious sensations must reach the sensory area in the postcentral gyrus

(C) the sensory area of each hemisphere receives sensations from the opposite  $\frac{1}{2}$  of the body

(D) Each sensation is transmitted from the receptors to the sensory area by 3 neurones as follows :

(1) 1st order neurone : for all sensations without exception : lies in the dorsal root ganglion of the spinal n. Each neurone has 2 processes :

- (a) peripheral process which receives the sensation from the receptor.
- (b) central process which transmits the sensation to the 2nd order neurone.

(2) 2nd order neurone : is either in :

- (a) the spinal cord (in case of pain, simple touch & temperature sensations).
- or (b) in the medulla (in case of proprioceptive & complex touch sensations).

N.B : the axons of the second order neurones must cross the middle line (either in the spinal or in the medulla) to reach the thalamus of the opposite side.

(3) 3rd order neurone : for all sensations without exception : lies in the postero-lateral ventral nucleus (P.L.V.N) of the thalamus of the opposite side. The axons of the cells of the P.L.V.N. of thalamus finally transmit the sensation to the sensory area in the postcentral gyrus.

(E) Afferent sensory fibres include the following :

- (1) General somatic sensory (G.S.S) fibres : carry exteroceptive & proprioceptive sensations to the C.N.S.
- (2) General visceral sensory (G.V.S) fibres : carry sensations from the viscera to the C.N.S.
- (3) special somatic sensory (S.S.S) fibres : " " " " ear (hearing & equilibrium) & from the eye (vision) to the C.N.S.
- (4) special visceral sensory (S.V.S) fibres : carry taste & smell to the C.N.S.

N.B : Efferent motor fibres include the following :

- (1) General somatic motor (G.S.M) fibres : carry motor orders from C.N.S to striated muscles.
- (2) General visceral motor (G.V.M) " : " autonomic (sympathetic & parasymp.) orders from the C.N.S to smooth muscles, heart & glands.
- (3) Special visceral motor (S.V.M) fibres : carry motor orders to special visceral muscles (which are derived from visceral or branchial arches in the H.N).

# Pain & temperature pathways

## \* Receptors:

- (1) Free naked nerve endings → for pain.
- (2) Ruffini organ → for temperature
- (3) Krause' organ → for cold.

## \* 1st order neurone (dorsal root gang. cells):

- the cell bodies are small-sized cells whose peripheral processes (thin finely myelinated) receive the sensation from the receptors while their central processes enter the spinal cord in the lat. bundles of the dorsal roots forming the Lissauer's tract which ends in the S.G.R.

## \* 2nd order neurone (cells of the S.G.R):

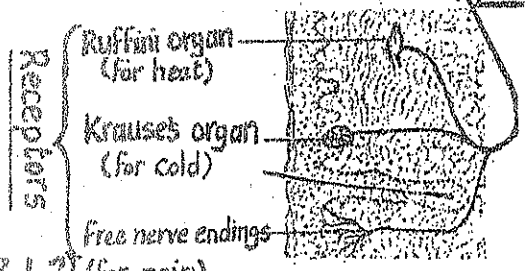
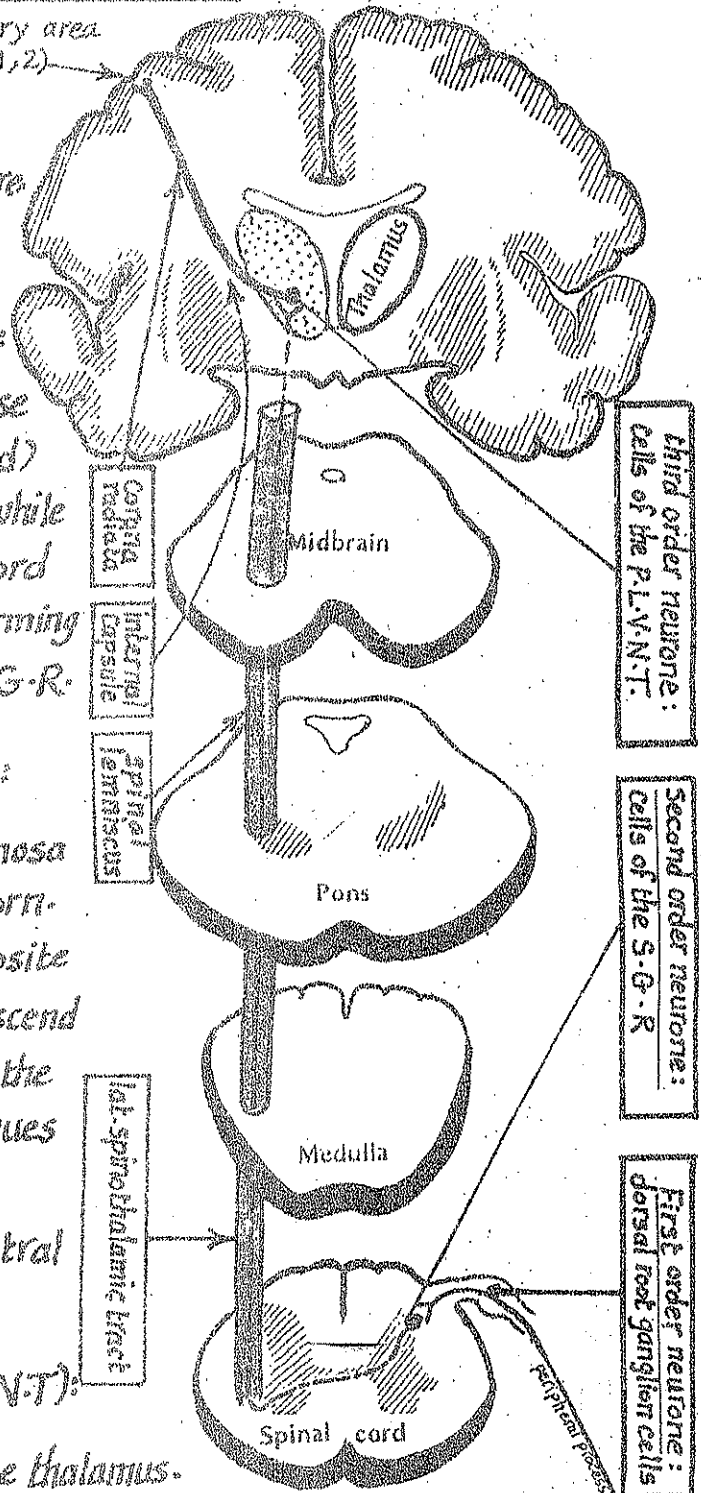
- the cell bodies lie in the Substantia gelatinosa of Rolandi (S.G.R.) in the tip of the post. horn.
- the axons of these cells cross to the opposite side in the ant. white commissure then ascend in the lat. column of the spinal cord forming the lateral spino-thalamic tract which continues upwards in the brain stem as the spinal lemniscus to end in the posterolateral ventral nucleus of thalamus (P.L.V.N.T.).

## \* 3rd order neurone (cells of the P.L.V.N.T):

- the cell bodies lie in the P.L.V.N. of the thalamus.
- their axons form the sensory radiation which pass in the post. 1/2 of the post. limb of the internal capsule.

\* Termination: the fibres of the sensory radiation finally reach sensory area (areas 3, 1, 2) in the post central gyrus of the parietal lobe.

Sensory area (3, 1, 2)



Receptors

# Touch Pathways

(1) Fine touch (touch discrimination & stereognosis): has the same pathway as proprioceptive sensation (page 66).

(2) Simple or crude touch: has the following pathway:

\* Receptors:

- (1) Merkel's touch corpuscles in the epidermis.
- (2) Meissner's " " in the papillary layer of dermis
- (3) Tuft of Bonet: around the hair follicles

\* 1st order neurone (dorsal root ganglion cells):

- the cell bodies are medium-sized cells of the dorsal root ganglion whose:
- peripheral processes (medium-sized fibres) receive the sensation from the receptors.
- Central processes enter the spinal cord in the dorsal roots & ascend for several segments in the posterior column to end in the main sensory nucleus (M.S.N.).

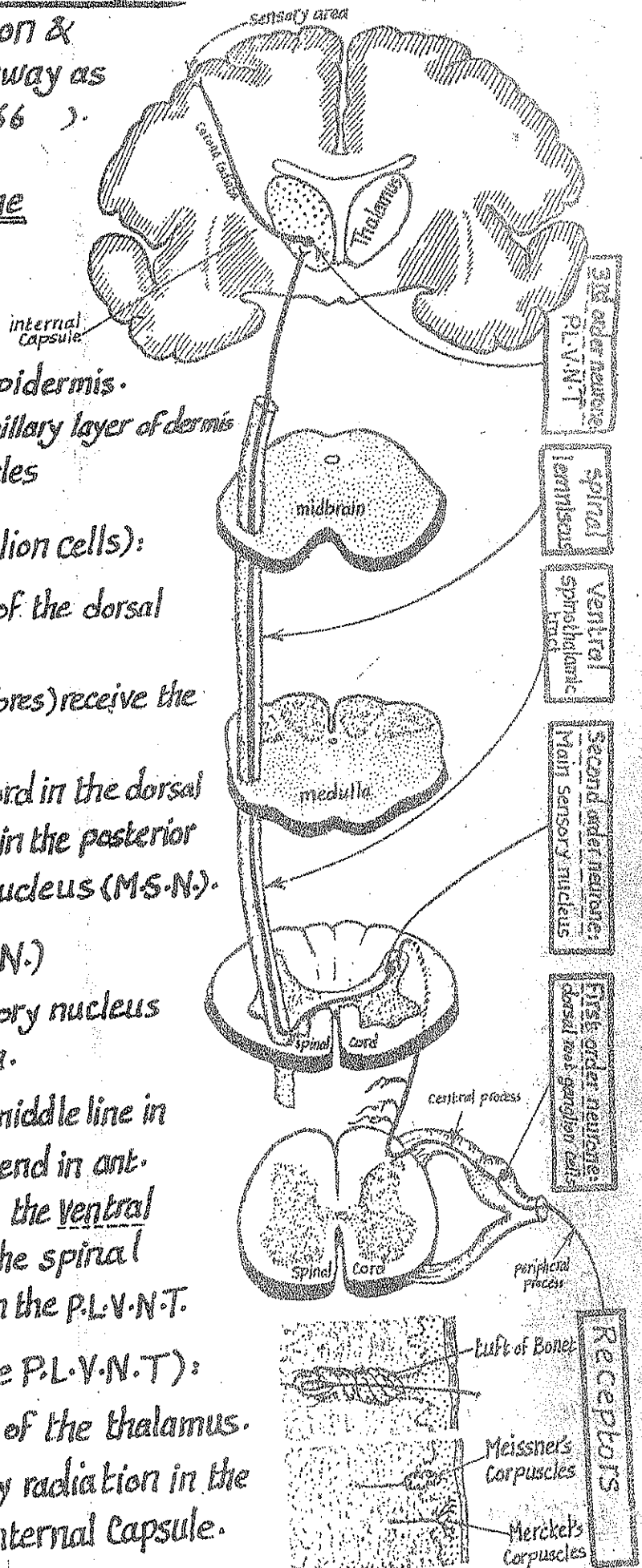
\* 2nd order neurone (cells of M.S.N.)

- the cell bodies lie in the main sensory nucleus (nucleus proprius) of the post. horn.
- the axons of these cells cross the middle line in the ant. white commissure then ascend in ant. column of the white matter forming the ventral spino-thalamic tract which joins the spinal lemniscus in the brain stem & ends in the P.L.V.N.T.

\* 3rd order neurone (cells of the P.L.V.N.T.):

- the cell bodies lie in the P.L.V.N of the thalamus.
- their axons ascend in the sensory radiation in the post. 1/2 of the post. limb of the internal capsule.

\* Termination: in the sensory area in the postcentral gyrus.





## \* Receptors:

- (1) Pacinian corpuscles : in C.T. between muscles & around Capsules of the joints.
- (2) Muscle spindles : in the skeletal muscles.
- (3) Tendon spindles : in the tendons.

## \* 1st order neurone (dorsal root gang. cells):

- the cell bodies are large-sized cells whose peripheral processes (thick, heavily myelinated) receive the sensation from the receptors while their central processes enter the spinal cord in the med. bundles of the dorsal roots then ascend in the post. column forming 2 tracts:
  - (a) the gracile tract which lies medially & carries sensations from the lower 1/2 of the body.
  - (b) the cuneate tract which lies laterally & carries sensations from the upper 1/2 of the body.
- the fibres of these 2 tracts relay in the gracile & cuneate nuclei in the medulla.

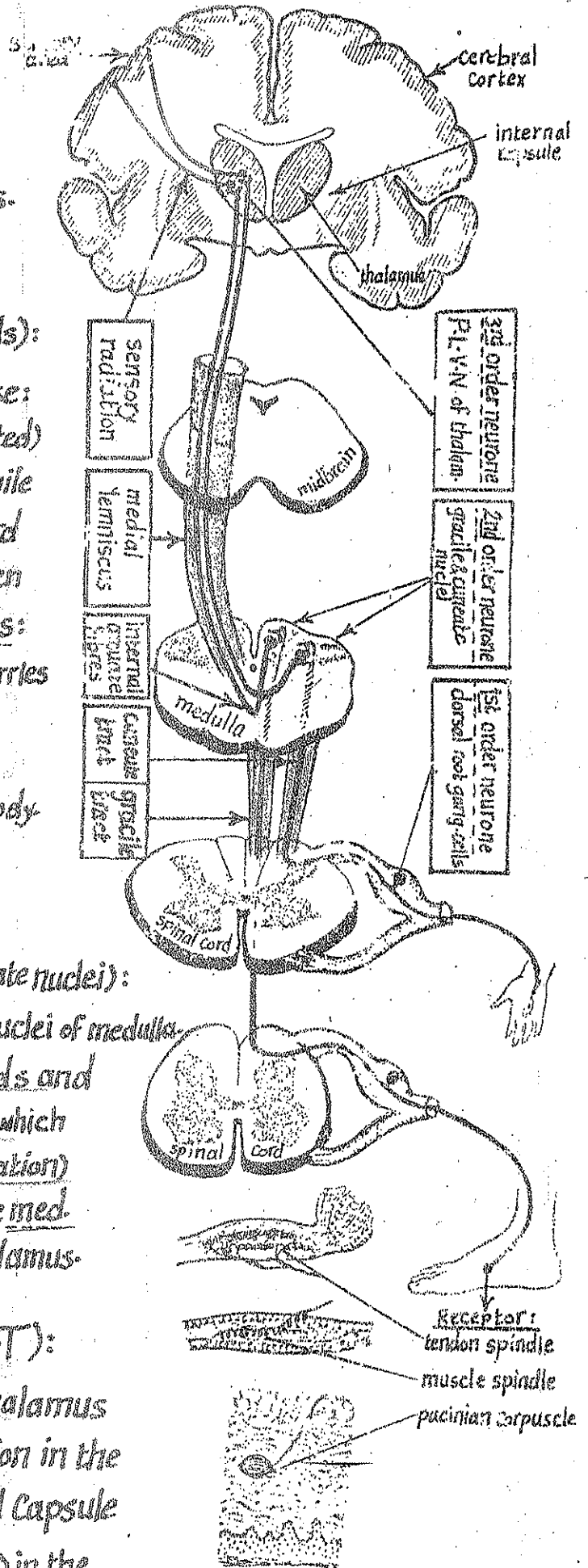
## \* 2nd order neurone (cells of gracile & cuneate nuclei):

- the cell bodies lie in the gracile & cuneate nuclei of medulla.
- the axons of these cells first curve forwards and medially forming the internal arcuate fibres which cross the middle line (in the sensory decussation) then ascend in the opposite side forming the med. lemniscus which ends in the P.L.V.N. of thalamus.

## \* 3rd order neurone (cells of the P.L.V.N.T):

- the cell bodies lie in the P.L.V.N. of thalamus
- their axons pass in the sensory radiation in the post. 1/2 of the post. limb of the internal Capsule

## \* Termination: in the sensory area (3,1,2) in the postcentral gyrus of the parietal lobe.



# The great efferent (Motor) Pathways


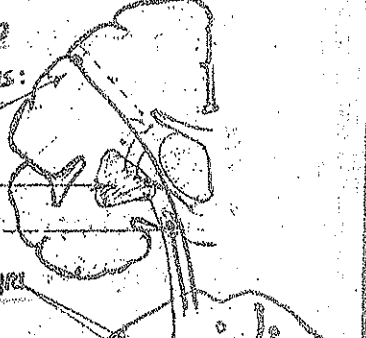

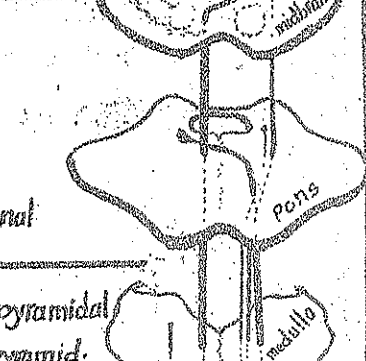

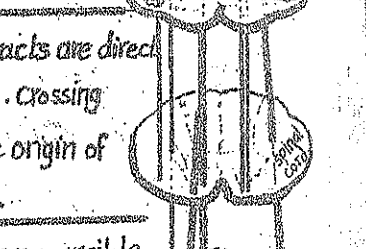
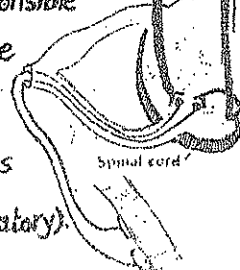

## \*General rules:

-all Voluntary movements are initiated by nerve impulses that arise from the motor areas of the brain & are transmitted to the striated muscles via a pathway formed of 2 neurones:

(A) Upper motor neurones: the motor cells of the cerebral cortex & subcortical centres whose axons constitute the pyramidal & extrapyramidal tracts which descend to end around the motor nuclei of cranial nerves in the brain stem & the A.H-Cs of the spinal cord.

(B) Lower motor neurones: include the cells of the motor nuclei of the cranial nerves & the A.H-Cs of the spinal cord & their axons which constitute the motor fibres of the peripheral nerves that terminate in the motor end plate of the striated muscles.

## (A) Upper motor neurones

	Pyramidal tract	Extrapyramidal tracts
Origin	<p>Localized (cortical areas):</p> <p>(1) 80% arise from motor area 4</p> <p>(2) 10% arise from the premotor area 6</p> <p>(3) 10% arise from the area 3, 1, 2!!</p> 	<p>widely distributed (from cortical &amp; subcortical areas):</p> <p>(1) premotor area 6</p> <p>(2) corpus striatum</p> <p>(3) subthalamic centres</p> <p>(4) red nucleus &amp; substantia nigra</p> <p>(5) inf. olivary nucleus</p> 
Course	<p>one neurone carries impulses from the cerebral cortex to the ant-horn cells without interruption</p> 	<p>many neurones carry impulses from the cortical &amp; subcortical centres to the A.H-Cs i.e. multisynaptic, multineuronal</p> 
site in the medulla:	<p>in the medulla, the pyramidal tract occupies the pyramid</p> 	<p>in the medulla, the extrapyramidal tracts do not occupy the pyramid.</p> 
Crossing of fibres:	<p>80% of fibres cross to the opposite side in the medulla</p> <p>the remaining fibres cross to the opposite side in the spinal cord.</p> 	<p>some extrapyramidal tracts are direct while others are crossed. Crossing occurs at the level of the origin of the extrapyramidal tract.</p> 
Function:	<p>(1) on movement: responsible for fine, isolated, precise &amp; specific movements</p> <p>(2) on tone: it increases tone &amp; reflexes (facilitatory)</p>	<p>(1) on movements: they are responsible for gross, synergic movements requiring the activity of large groups of muscles</p> <p>(2) on tone: some tracts are facilitatory while others are inhibitory for tone &amp; reflexes.</p>



# The Pyramidal tract

\* Definition:

it is a bundle of nerve fibres arising from the cerebral cortex & descending without interruption to relay on the motor nuclei of cranial nerves in the brain stem or around the A.H.Cs of the spinal cord.

\* Subdivisions: it is subdivided into:

- (a) Corticospinal tract. (b) Corticobulbar tract.

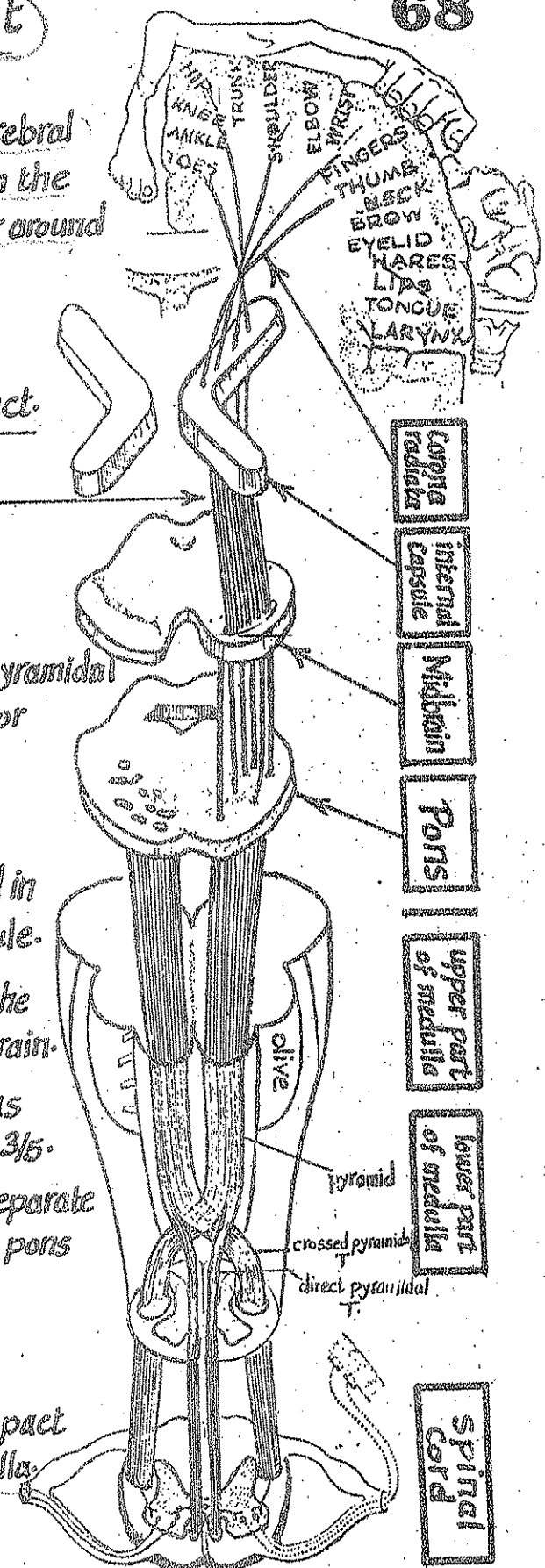
## (A)-the Corticospinal tract

\* It is the part of the pyramidal tract ending around the A.H.Cs of the spinal cord.

\* Origin: it arises as the axons of the giant pyramidal cells of Betz mainly from the upper 2/3 of the motor area 4 in the precentral gyrus.

\* Pathway:

- (1) In the cerebral hemisphere: the fibres descend in the Corona radiata & converge towards the int. Capsule.
- (2) In the internal Capsule: the fibres descend in the ant. 1/2 of its post. limb converging towards midbrain.
- (3) In the midbrain: the fibres descend in the crus cerebri occupying its middle 3/5.
- (4) In the pons: the corticospinal fibres form separate bundles descending in the basilar part of the pons separated by the transverse pontine fibres.
- (5) In the upper part of the medulla: the separate bundles collect again forming a compact bundle (the Pyramid) in the ant. part of the medulla.
- (6) In the lower part of the medulla:
  - (a) 75-85% of the fibres of the pyramid cross to the opposite side in the pyramidal decussation & continue downwards as the crossed pyramidal tract in the spinal cord.
  - (b) 15-25% of the fibres of the pyramid descend on the same side forming the direct pyramidal tract in the spinal cord.



(7) In the spinal cord:

- (a) the crossed pyramidal tract descends in the lat-column of the white matter. Its fibres relay on the A.H.Cs of the same side.
- (b) the direct pyramidal tract descends in the ant-column of the white matter. Its fibres cross the middle line to relay on the ant-horn cells of the opposite side.

### B- The Cortico-bulbar fibres (tract)

- \* It is the part of the pyramidal T. whose fibres relay on the motor nuclei of the cranial nerves (of opposite side).
- \* Subdivisions: the corticobulbar T. is subdivided into:
- (1) med-cortico-bulbar fibres: ending on the nuclei of the cranial nerves controlling the eye movements (3, 4 & 6).
  - (2) lat-cortico-bulbar fibres: ending on the motor nuclei of the other cranial nerves (5, 7, 9, 10, 11 & 12).

#### 1-Med-Cortico-bulbar fibres

- \* Origin: the fibres arise as axons of the cells of the area 8 (the frontal motor eye field).
- \* Pathway:
- (1) In the cerebral hemisphere: the fibres descend in corona radiata then the genu of the internal capsule.
  - (2) In the midbrain: they descend in the med. part of the crus cerebri (very close to the middle line).
  - (3) they end by relaying on the nuclei of the cranial nerves 3, 4 & 6 of the opposite side (in midbrain & pons).

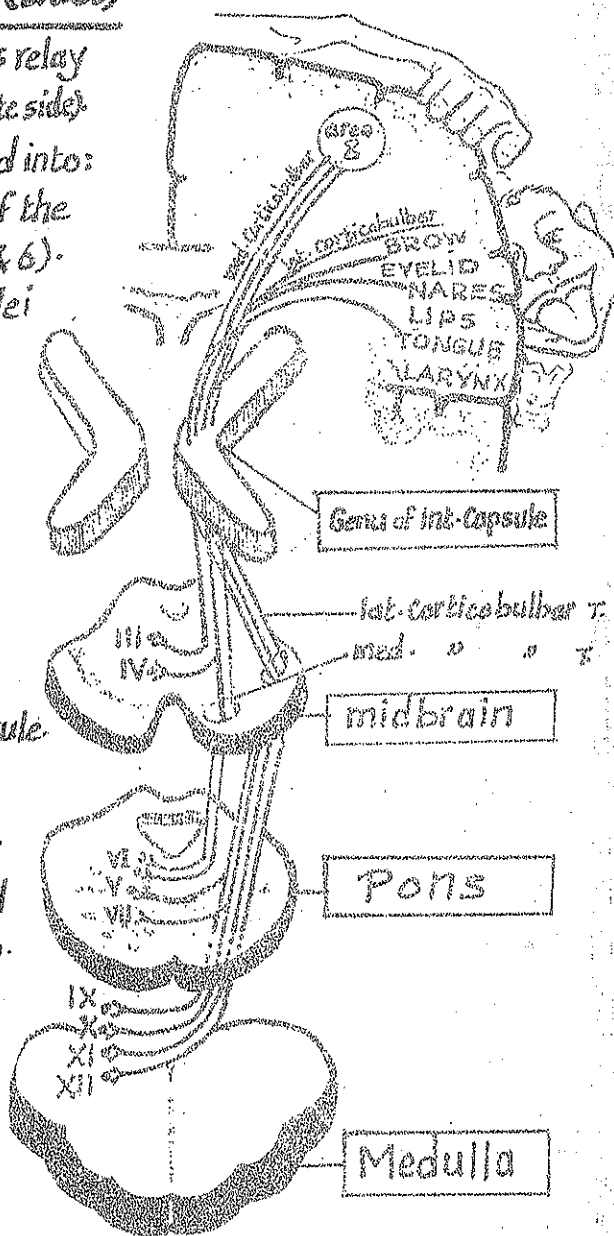
#### 2-Lat-Cortico-bulbar fibres

- \* Origin: the fibres arise as axons of the cells in the lower  $\frac{1}{3}$  of the motor area 4.

\* Pathway:

- (1) In the cerebral hemisphere: the fibres descend in the corona radiata then the genu of the internal capsule.
- (2) In the midbrain: the fibres descend in the lat. part of the crus cerebri (dorso-lateral to the corticospinal fibres).
- (3) In the pons & medulla: the fibres end on the nuclei of the cranial nerves 5, 7, 9, 10, 11 & 12 of the opposite side.

N.B.: the 5<sup>th</sup> & 7<sup>th</sup> nerve motor nuclei receive fibres from both ipsilateral & contralateral corticobulbar tracts.

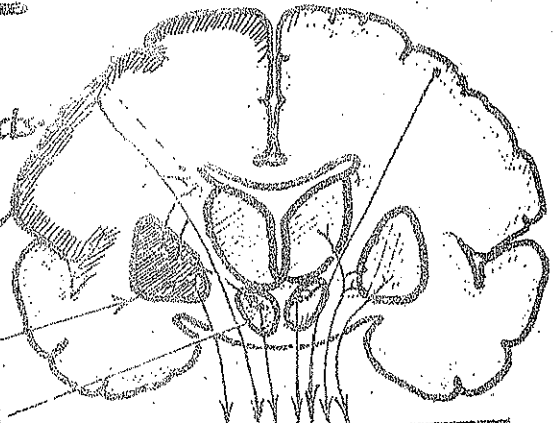


# Extrapyramidal System

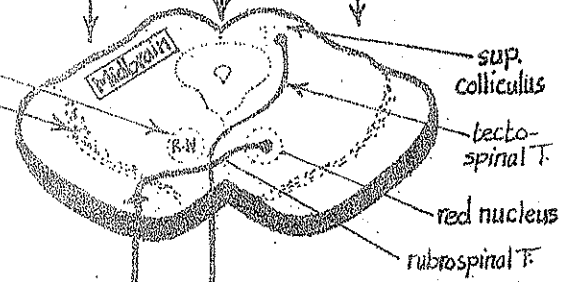
\* The extrapyramidal system includes:  
 (a) extrapyramidal centres (b) extrapyramidal tracts.

## (A) Extra pyramidal Centres

- (1) Premotor area of the cerebral cortex (area 6)
- (2) Corpus striatum (caudate & lentiform nuclei)
- (3) subthalamic nucleus in the subthalamus
- (4) Red nucleus (in the midbrain)
- (5) substantia nigra (in the midbrain)
- (6) inf. olivary nucleus in medulla.
- (7) nuclei of the reticular formation in the brain stem.



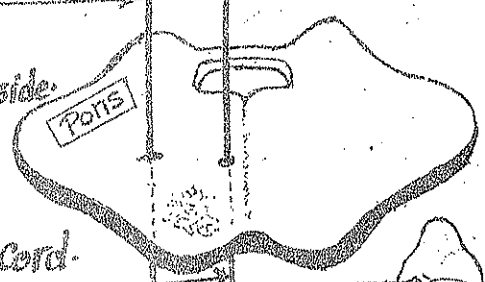
to extrapyramidal centres of brainstem



## (B) Extra pyramidal tracts of the Sp. cord

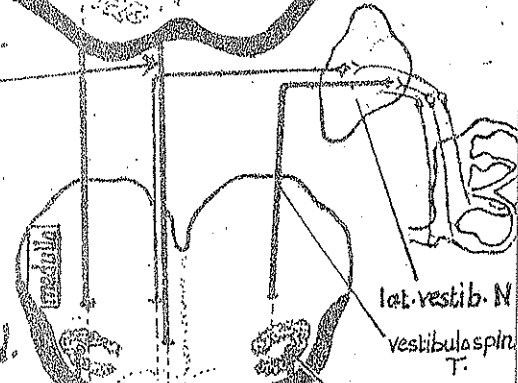
### (1) Rubrospinal tract:

- \* arises from the red nucleus & crosses to the opposite side.
- \* descends in the lat. column of the spinal cord.
- \* function: relays impulses from the corpus striatum & cerebellum to the A.H-Cs of the spinal cord.



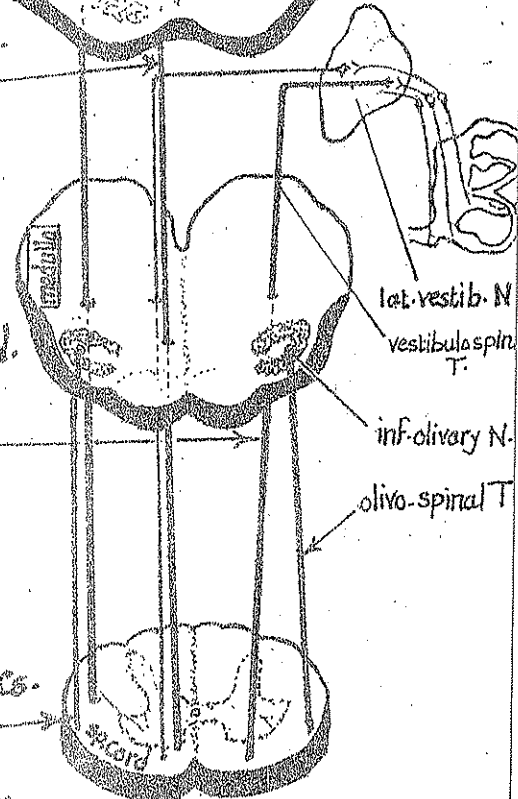
### (2) Tecto-Spinal tract:

- \* arises from the sup. colliculus of midbrain.
- \* Crosses to the opposite side.
- \* descends in the ant. column of the spinal cord.
- \* function: relays visual reflexes to the A.H-Cs of sp. cord.



### (3) Vestibulo-spinal tract

- \* arises from the lat. vestibular nucleus in the pons (the majority of its fibres are uncrossed).
- \* descends in the ant. column of the spinal cord.
- \* Function: convey impulses of equilibrium to the A.H-Cs.

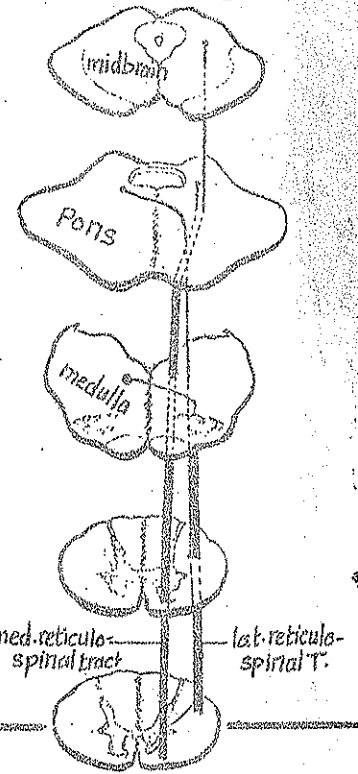


### (4) Olivo-spinal tract:

- \* arises from the inf. olivary nucleus in the medulla.
- \* descends on the same side (uncrossed) in the lat. column of the spinal cord
- \* function: probably it is an intermediate pathway in the strio-olivo-spinal connections.

(5) Lateral reticulo-spinal tract :

- \* arises from the nuclei of the reticular formation of the brain-stem (mainly medulla) & crosses to the opposite side.
- \* descends in the lat. column of the spinal cord deep to the rubrospinal & lat. cortico spinal tracts.
- \* ends on the ant. horn cells of the spinal cord.



(6) Medial reticulo-spinal tract :

- \* arises from the nuclei of reticular formation of the brain stem (mainly pons).
- \* descends uncrossed in the ant. column of the spinal cord.
- \* ends on the A.H.Cs.

Connection of the Cerebellum with the extrapyramidal centres

The cerebellum affects the function of the extra-pyramidal system through its connections with the following extrapyramidal centres :

(1) The premotor area (area 6) of the cerebral cortex :

the cerebellum receives afferent impulses from the premotor area 6 via the corticopontocerebellar pathway

(2) the red nucleus in the midbrain :

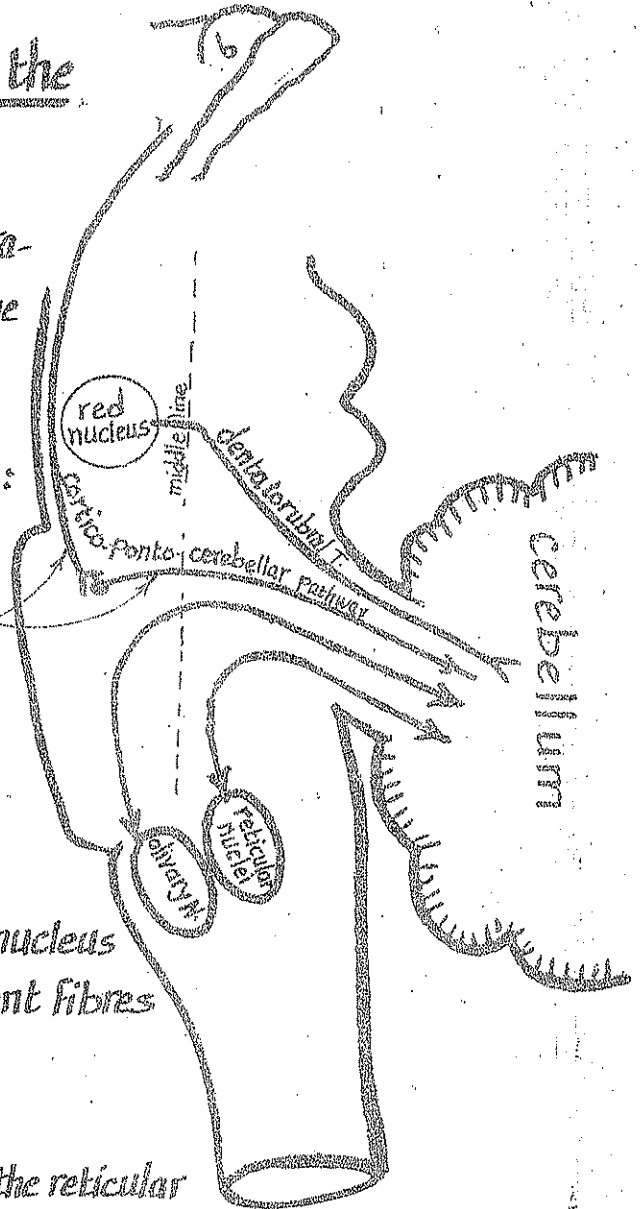
receives afferent impulses from the cerebellum via the dentato-rubral tract.

(3) the inf. olivary nucleus in the medulla :

the cerebellum is connected to the inf. olivary nucleus via afferent fibres (olivo-cerebellar) & efferent fibres (cerebello-olivary).

(4) Reticular formation of the brain stem :

the cerebellum is connected with the nuclei of the reticular formation of the brain stem through cerebello-reticular & reticulo cerebellar fibres.



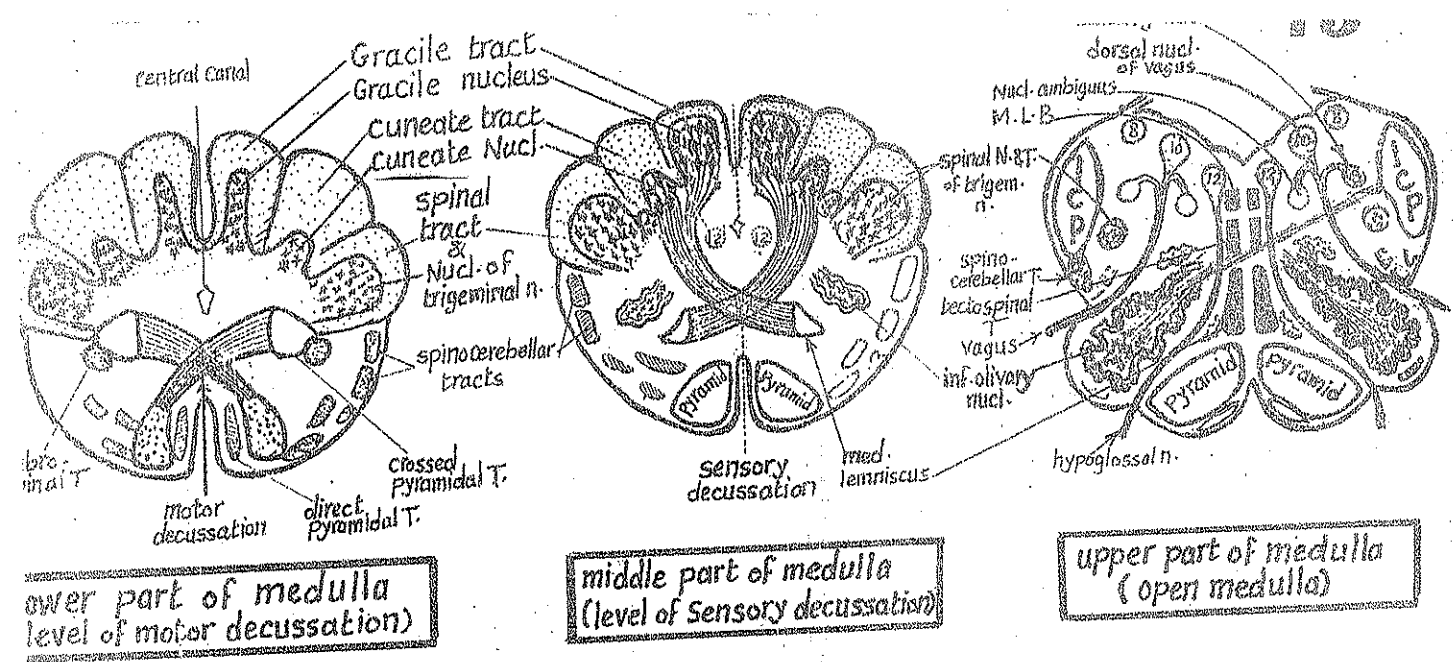
# 2-Internal Structure of Medulla

72

## I Main Nuclei

Nucleus	site	Afferent fibres entering	Efferent fibres emerging
1-Gracile N. (proprioceptive)	most post. part of closed medulla close to middle line.	fibres of gracile T. carrying proprioceptive & fine touch sens. from lower 1/2 of the body.	eff. fibres of the 2 nuclei cross to the opposite side in the form of arches called internal arcuate.
2-Cuneate N. (proprioceptive)	post. part of the closed medulla, lateral to the gracile nucleus.	fibres of the cuneate T. carrying proprioceptive & fine touch sens. from the upper 1/2 of the body.	fibres decussating with its fellows of the opposite side forming the sensory decussation then ascend as the med. lemniscus → thalamus
3-Accessory Cuneate N. (proprioceptive)	lat. to the cuneate nucleus in the upper part of the closed medulla.	the most lat. fibres of the Cuneate T. carrying proprioceptive sensation from the upper limb.	its efferents constitute the post. ext. arcuate fibres which pass in inf. cerebellar peduncle of the same side → cerebellum
4-Inf. olivary N. (extrapyramidal)	lat. aspect of the open medulla.	(1) spino-olivary tract. (2) descending fibres from the Corpus striatum & red nucleus.	(1) olivo-spinal T.: descends in the lat. column of the spinal cord. (2) olivo-cerebellar T.: crosses to the opposite side & enters cerebellum via inf. cerebell. ped.
5-Inf. Salivary N. (parasympath.)	upper most part of medulla in line with the dorsal nucleus of Vagus.	descending fibres from the higher autonomic centres.	eff. fibres run in the glossopharyngeal n. as preganglionic parasymp. fibres which relay in the obic ganglion.
6-Spinal N. of trigeminal n. (general sensory)	in the lat. aspect of the whole medulla & continuous below with S-G-R of spinal cord.	pain & temp. sensations from the face & scalp via the trigeminal n.	eff. fibres cross to the opposite side & ascend as the trigeminal lemniscus → P.L.V.N of thalamus.
7-Solitary N. (taste sens.)	dorso lateral part of the open medulla.	(1) taste sensations carried by Vagus, glossopharynx. & facial nerves. (2) ? visceral sensations through vagus & glossoph. nerves.	eff. fibres cross to the opposite side & ascend to relay in: (1) P.M.V.N of thalamus. (2) hypothalamic nuclei.
8-Nucleus ambiguus (branchiomotor)	lat. part of open medulla, behind the inf. olivary nucleus.	Pyramidal & extra pyramidal.	- its upper part → motor fibres of glossoph. n. - its middle part → motor f. of vagus. - its lower " → motor f. of cr. accessory.
9-Dorsal N. of Vagus n. (parasympath.)	most post. part of open medulla (underlying the vagal trigone).	? visceral aff. sensations via glossoph. & vagus nerves.	its eff. fibres run in the vagus n. as preganglionic secretomotor parasymp. fibres.
10-Hypoglossal N. (motor)	most post. part of open medulla close to the middle line (underlying the hypoglossal trigone).	Pyramidal & extra pyramidal.	its axons form the fibres of the hypoglossal n. which passes forward between both med. lemniscus & the pyramid (medially) & the inf. olivary nucleus (laterally).



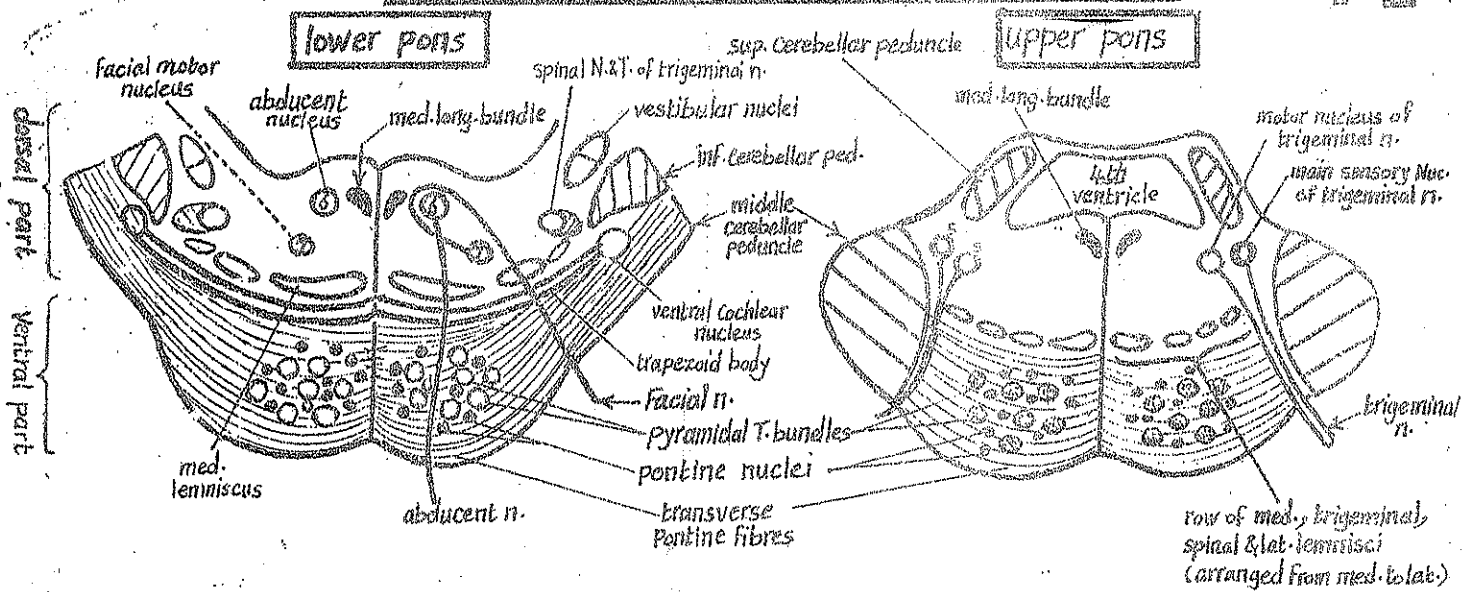


## II- Main tracts of the medulla

- 1) Gracile T. } ascend in the post. part of the lower  $\frac{1}{2}$  of medulla. They gradually
- 2) Cuneate T. } diminish as they relay in their nuclei.
- 3) Internal arcuate fibres & sensory decussation: the axons of the gracile & cuneate nuclei cross to the opposite side in the form of arches called internal arcuate fibres which decussate with their fellows of the opposite side at the sensory decussation in the middle part of the medulla.
- 4) Medial lemniscus: is the upward continuation of the internal arcuate fibres after the decussation. It ascends paramedially in the open medulla.
- 5) Medial longitudinal bundle: it is an association tract present close to the middle line in the open medulla.
- 6) Pyramidal tract & motor decussation:  
 the pyramidal T. descends as a compact bundle lying close to the middle line in the ant. part of the medulla till its lower part where:
  - (a) 75-85% of its fibres cross to the opposite side decussating with their fellows of the opposite side at the motor decussation then continue downwards in the lat. column of spinal cord as the crossed pyramidal T.
  - (b) 15-25% of its fibres descend on the same side forming the direct pyramidal T. which continues downwards in the ant. column of the spinal cord.
- 7) Spinal tract of the trigeminal n.: present in all levels of the medulla close to its nucleus.
- 8) Inferior cerebellar peduncle (I.C.P.): a large bundle of fibres emerging from the posterolat. aspect of upper part of medulla & connecting it with the cerebellum.

# 3-Internal Structure of the Pons

74



**(A) Basilar (Ventral) part:** contains the following structures :

- (1) Pontine nuclei : scattered among the longitudinal & transverse fibres in the basilar portion of the pons. They form an important part of the Cortico-ponto-cerebellar pathway
- (2) Transverse fibres (pontocerebellar) beginning from the pontine nuclei & crossing the middle line to enter the opposite cerebellar hemisphere via the middle cerebellar peduncle.
- (3) Longitudinal fibres which include :
  - (a) Pyramidal (Cortico-spinal & Cortico bulbar) fibres.
  - (b) Cortico pontine fibres : arising from the Cerebral Cortex & ending on the pontine nuclei.

**(B) Tegmental (Dorsal) part:** containing mainly nuclei of the middle 4 cranial nerves & lemnisci

## I- Nuclei of the middle 4 cranial nerves

- (1) Trigeminal nerve : has 2 nuclei in the tegmentum of the upper part of pons :
  - (a) motor nucleus (medial in position) : its axons form the motor root of the trigeminal n. which joins the mandibular n.
  - (b) main sensory nucleus (just lat. to the motor nucleus) : 2nd order neurone :
    - receives afferent touch & pressure sens. from the trigeminal area of the face & scalp.
    - sends efferent fibres which cross to join the opposite trigeminal lemniscus.
- (2) Abducent nerve Nucleus :
  - Site : in the post. aspect of the lower part of the pons near the floor of the 4th ventricle.
  - it is encircled by the fibres of the facial n., raising a bulge called the facial colliculus in the floor of the 4th ventricle.
  - its efferent fibres pass forward & downwards traversing the med. lemniscus & the Pyramidal T. bundles to emerge anteriorly at the junction between pons & medulla.



(3) facial nerve: has 2 nuclei in the pons:

(a) Motor nucleus: lying in the lower part of the pons below the trigeminal motor nucleus

Its efferent fibres encircle the abducent nucleus then pass anterolaterally to emerge at the junction between pons & medulla.

(b) Sup. salivary nucleus (parasymp): in the lower part of the pons just above the inf. salivary nucleus. Its efferent fibres run in the facial n. as preganglionic parasymp. fibres to relay in the sphenopalatine & submandibular ganglia.

(4) Vestibulo cochlear n.: has the following nuclei:

(A) Vestibular nuclei: the sup., med & lat. vestibular nuclei lie in the lower part of the pons medial to the inf. cerebellar peduncle (underlying the vestibular trigone in the floor of the 4th ventricle). These nuclei, together with the inf. vestibular nucleus in the upper part of medulla, receive unconscious proprioceptive sensation (equilibrium) from the internal ear via the vestibular nerve. They send efferents to: cerebellum (vestibulo-cerebellar), spinal cord (vestibulo-spinal) & med. longit. bundle.

(B) Cochlear nuclei: the dorsal & ventral nuclei lying dorsal & ventral to the inferior cerebellar peduncle in the lower part of the pons. They receive hearing impulses from internal ear via the cochlear n. Their efferent fibres form the trapezoid body.

## II-The 4 Lemnisci

\* Definition: they are 4 bands of ascending sensory fibres in the brain stem. Each lemniscus starts from a decussation below & ends in the thalamus above.

I- Lateral Lemniscus (the most lateral of the 4 lemnisci):

\* definition: it is a band of ascending fibres carrying hearing impulses from both ears (mainly from the opposite side).

\* origin: it begins in the pons by the axons of the 3rd order neurones of the auditory pathway which consists of:

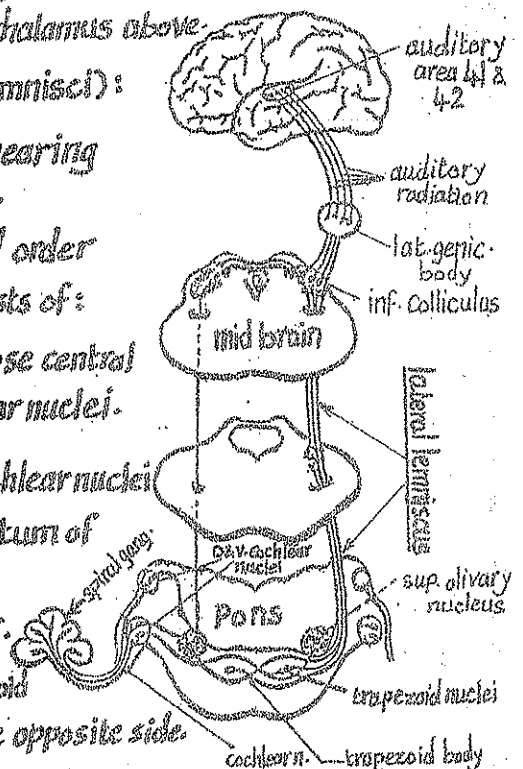
(1) 1st order neurone: the cells of the spiral ganglion whose central processes relay in the ventral & dorsal cochlear nuclei.

(2) 2nd order neurone: the cells of the ventral & dorsal cochlear nuclei

whose axons cross to the opposite side in the tegmentum of the lower part of the pons forming a big decussation called the trapezoid body containing trapezoid nuclei.

The axons of the 2nd order neurones relay in the trapezoid & sup. olivary nuclei of both sides but mainly on the opposite side.

(3) 3rd order neurones: the cells of the trapezoid nuclei & sup. olivary nucleus whose axons ascend forming the Lateral lemniscus.



\* Course & termination: the lat. lemniscus ascends in the upper 1/2 of the pons then midbrain as the most lateral of the 4 lemnisci. Its fibres end as follows:

- (a) few fibres end in the inf. colliculus of midbrain (centre of auditory reflex)
- (b) most of the fibres end in the med. geniculate body whose cells constitute the 4th order neurone that transmit the auditory impulses to the auditory areas 41, 42 in the temporal lobe.

**II Spinal lemniscus:** (just med. to the lat. lemniscus):

\* definition: it is a band of ascending fibres carrying pain, temperature & crude touch from the opposite side of the body, below the head. It represents the axons of the 2nd order neurones of these sensations.

\* Origin: it is formed in the upper part of the medulla by the union of the following 2 tracts:

- (a) Lat. spinothalamic T. (axons of the substantia gelatinosa, carrying pain & temp from opposite side)
- (b) Ventral spinothalamic T. (axons of the nucleus proprius carrying simple touch from the opposite side).

\* Course & termination: the spinal lemniscus ascends in the pons then in the tegmentum of the midbrain, lying between the trigeminal lemniscus (medially) & the lateral lemniscus (laterally). It ends in the P.L.V.N of thalamus.

**III Trigeminal lemniscus:** (Just med. to the spinal lemniscus):

\* definition: it is a band of ascending fibres carrying pain, temp., touch & proprioception from the opposite side of the face & scalp. (it represents the axons of the 2nd order neurones).

\* Origin: it begins in the medulla by the axons of the spinal nucleus of trigeminal n. which cross to the opposite side.

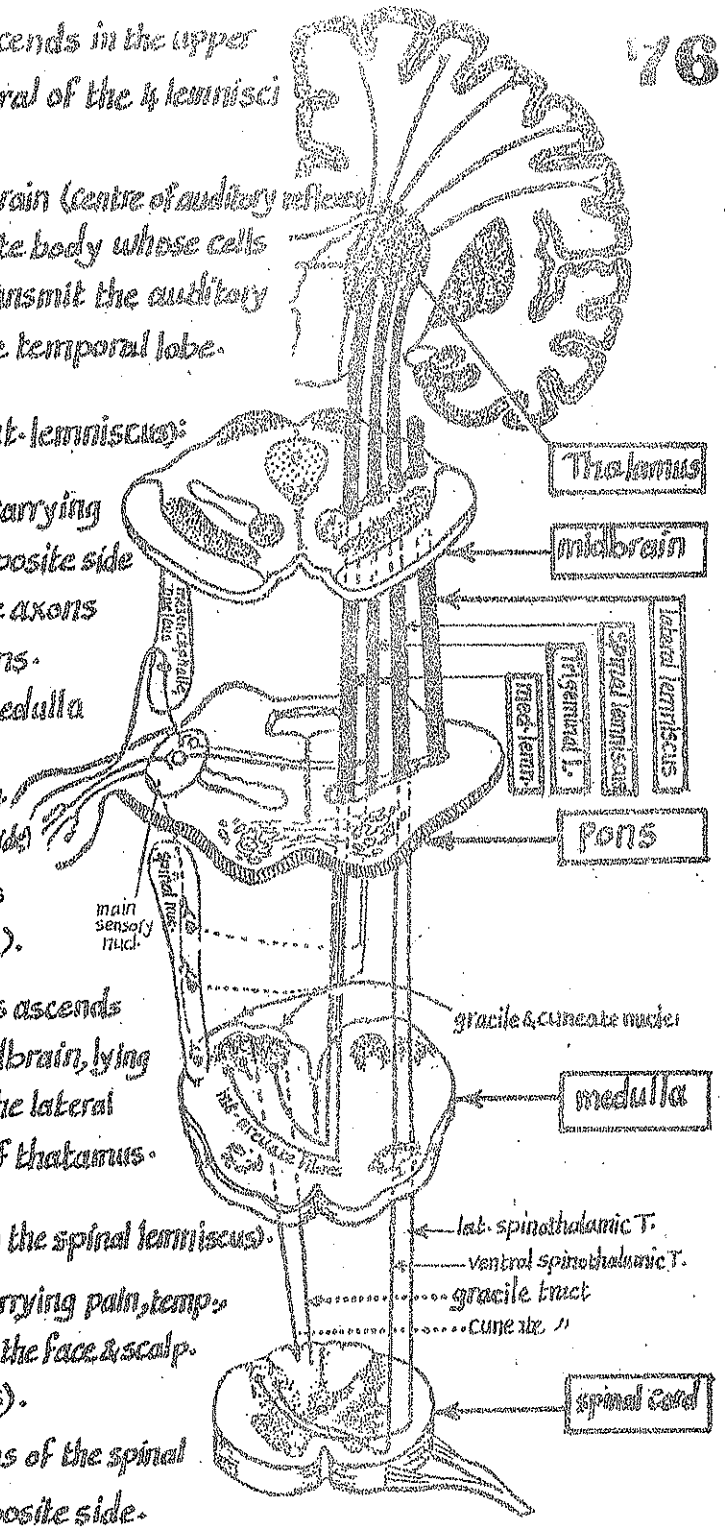
\* Course & termination: it ascends lat. to the med. lemniscus to reach the pons where it gets additional fibres from the main sensory nucleus of trigeminal n. (of the opposite side). Then it continues upwards in the midbrain to end in the posteromedial ventral nucleus of thalamus.

**IV-Medial lemniscus:** ( the most medial of the 4 lemnisci):

\* definition: it is a band of ascending fibres carrying proprioceptive & fine touch sensation from the opposite side of the body below the head. It represents axons of the 2nd order neurones.

\* Origin: it begins in the medulla as a continuation of the axons of the gracile & cuneate nuclei which cross to the opposite side forming the internal arcuate fibres.

\* Course & termination: it ascends close to the middle line in the pons then shifts away from middle line in the midbrain (just dorsal to substantia nigra). It ends in the P.L.V.N. of thalamus.



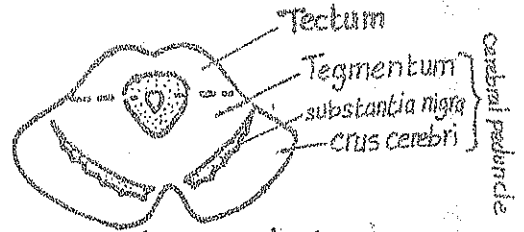
# 4-Internal Structure of Midbrain

\* The cerebral aqueduct traversing the midbrain divides it into 2 main parts:

(I) Tectum: the smaller dorsal part behind the aqueduct

It is composed of 4 rounded swellings (colliculi):

- (a) 2 sup. colliculi: reflex centres of vision.
- (b) 2 inf. colliculi: reflex centres of hearing.



(II) - 2 Cerebral peduncles: the larger ventral part in front of the aqueduct.

It consists of 3 parts, arranged from before backwards as follows:

- (1) crus cerebri: the most ant. part which consists exclusively of pyramidal & cortico pontine fibres.
- (2) substantia nigra: a thick lamina of grey matter formed of deeply pigmented nerve cells lying behind the crus cerebri. It is an extrapyramidal centre.
- (3) Tegmentum: the post. part of the cerebral peduncle. It contains ascending tracts, certain nuclei, decussations & the reticular formation of the midbrain.

## Nuclei of Midbrain

(1) Nucleus of oculomotor n.:

\* site: in the upper part of the midbrain close to the middle line at the level of the sup. colliculus.

\* efferent fibres: pass forwards through the red nucleus & the medial part of the substantia nigra forming the oculomotor n. which emerges at the med. surface of crus cerebri

(2) Nucleus of the trochlear n.:

\* site: in the lower part of midbrain close to the middle line at the level of the inf. colliculus.

\* efferent fibres: pass backwards & medially decussating with its fellows of the opposite side then emerge from the dorsal aspect of the midbrain below the inf. colliculus as trochlear n.

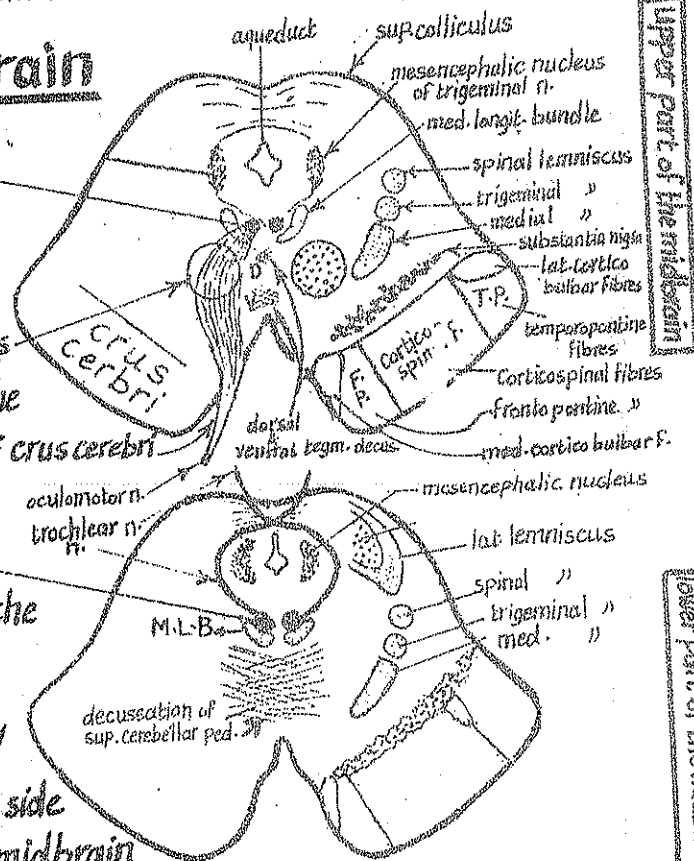
N.B.: trochlear n. differs from other cranial nerves in 2 aspects

- (1) its fibres cross to the opposite side.
- (2) it emerges from the back of midbrain.

(3) Red Nucleus:

\* it is a large mass of grey matter which appears red due to the presence of iron-containing pigment.

\* site: in the tegmentum of the upper part of midbrain close to the middle line.



\* Function: the red nucleus is an important extrapyramidal centre.

\* Connections:

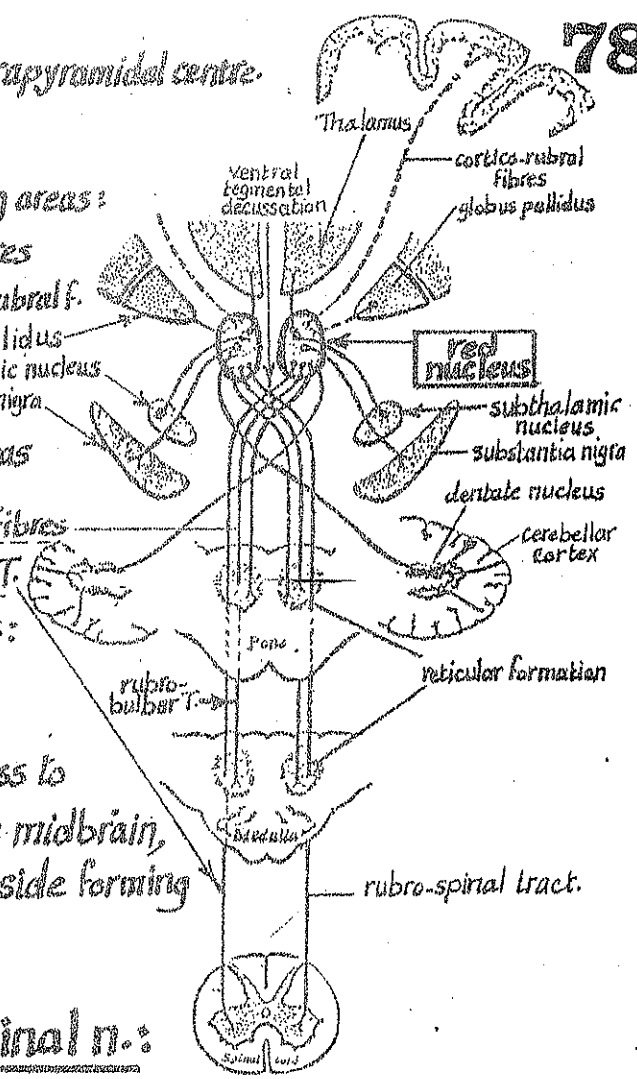
(A) It receives Afferent fibres from the following areas:

- (1) the cerebral cortex through cortico-rubral fibres
- (2) dentate nucleus of the cerebellum through dentato-rubral f.
- (3) other extrapyramidal centres as:
  - (a) globus pallidus
  - (b) subthalamic nucleus
  - (c) substantia nigra

(B) It sends Efferent fibres to the following areas

- (1) nuclei of the brain stem: through rubrobulbar fibres
- (2) A.H.Cs of the spinal cord: through rubrospinal T.
- (3) the intermediate ventral nucleus of thalamus: through rubrothalamic fibres.

N.B: the rubrobulbar & rubrospinal fibres cross to the opposite side in the tegmentum of the midbrain, decussating with the fibres of the other side forming the ventral tegmental decussation.



(4) Mesencephalic nucleus of trigeminal n.:

\* site: in the tegmentum of the lower part of the midbrain at the level of the inf. colliculus, lat. to the aqueduct. It extends downwards into the pons.

\* function: it receives proprioceptive impulses from the masticatory & ocular muscles. - It sends efferent fibres to the main sensory nucleus of trigeminal n. (in pons).

(5) Inferior Colliculus:

\* site: a mass of laminated grey matter in the lower part of the tectum of midbrain.

\* function: it is a centre of auditory reflexes. Its neurones co-ordinate hearing with the movements of the body.

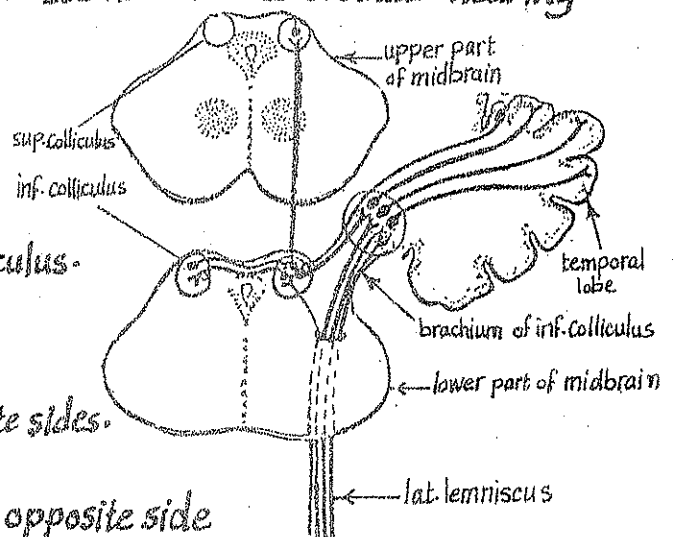
\* Connections:

(1) it receives afferent fibres from:

- (a) lat. lemniscus
- (b) temporal cortex: via brachium of inf. colliculus.

(2) It sends efferent fibres to:

- (a) inf. colliculus of the opposite side.
- (b) med. geniculate body of the same & opposite sides.
- (c) sup. colliculus of the same side.
- (d) tectospinal & tectobulbar tracts of the opposite side



## (6) Superior colliculus:

\* Site: In the upper part of the tectum of midbrain.

\* Function: a centre for visual reflexes.

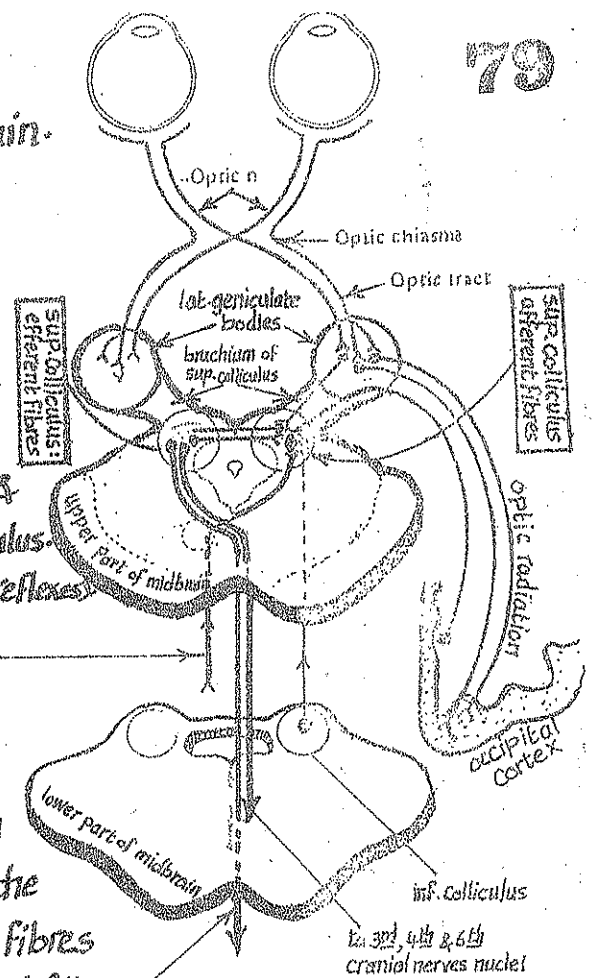
\* Connections:

(A) It receives afferent impulses from:

- (1) the retina: via the brachium of sup. colliculus
- (2) the occipital cortex: via the optic radiation & the brachium of sup. colliculus.
- (3) the inf. colliculus of the same side (for auditory reflexes)
- (4) the spinal cord via the spinotectal tract.

(B) it gives efferent fibres to:

- (1) to the nuclei of the cranial nerves supplying the ocular muscles (3rd, 4th & 6th nerves) & the muscles of the neck (11th nerve) via tectobulbar fibres
  - (2) A.H.Cs of the spinal cord via the tectospinal fibres
- N.B. the tectobulbar & tectospinal fibres cross to the opposite side in the tegmentum of midbrain in the dorsal tegmental decussation.
- (3) to the sup. colliculus of the opposite side.



## (7) Pretecal nucleus:

\* Site: it lies deep to the superolateral part of the sup. colliculus.

\* Function: it is an important part in the pathway of the light & consensual reflexes.

\* Connections:

- (1) it receives afferent light impulses from the retina & occipital cortex.
- (2) it gives efferents to the Edinger-Westphal nuclei of both sides.

## (8) Substantia nigra:

\* Site: it is a thick lamina of deeply pigmented grey matter lying just behind the crus cerebri extending throughout the whole length of the midbrain.

\* Function: it is an extra pyramidal centre having the following connections:

- (1) it receives afferents from the motor cortex (corticonigral fibres).
- (2) it gives efferents to:
  - (1) corpus striatum (nigrostriate fibres).
  - (2) reticular formation of tegmentum of midbrain.



# Tracts of the Midbrain

80

(I) Crus cerebri: contains the following descending fibres (from med. to lat.):

- (1) med. cortico-bulbar fibres of the pyramidal tract
- (2) fronto-pontine fibres (part of the cortico-ponto-cerebellar pathway) } in the med. 1/5.
- (3) cortico-spinal fibres of the pyramidal tract ----- in the intermediate 3/5.
- (4) temporo-pontine fibres (part of the cortico-ponto-cerebellar pathway) } in the lat. 1/5.
- (5) lat-cortico-bulbar fibres of the pyramidal tract.

(II) Tegmentum: contains the following tracts & decussations:

- (1) the 4 lemnisci: ascending from the pons to the midbrain. They are arranged from anteromed. to posterolat. as follows:
  - (a) med. lemniscus
  - (b) trigeminal lemniscus
  - (c) spinal "
  - (d) lateral "

N.B: the lat. lemniscus ends at the level of inf. colliculus.

(2) Superior cerebellar peduncles: enter the back of the midbrain just below the inf. colliculus. The constituent fibres are described with the cerebellum (page 84).

(3) decussation of superior cerebellar peduncles: the fibres of each peduncle cross to the opposite side in the tegmentum of the lower part of the midbrain.

After decussation, the fibres divide into:

- (a) ascending fibres which run upwards to end in
  - red nucleus of midbrain
  - reticular formation of midbrain
  - intermediate ventral nucl. of thalamus.
- (b) descending fibres which run downwards to end in
  - reticular formation of pons & medulla.
  - inferior olivary nucleus.

(4) Tectospinal tract: arises as efferent fibres of the sup. colliculus, crosses to the opposite side in the dorsal tegmental decussation (at the level of sup. colliculus) then descends in the tegmentum of lower part of midbrain.

(5) Rubrospinal tract: arises as efferent fibres of the red nucleus in the upper part of the midbrain, crosses to the opposite side (at the level of sup. colliculus) in the ventral tegmental decussation then descends in the tegmentum of lower part of midbrain.

(6) Central tegmental tract: it is an extrapyramidal T. connecting the corpus striatum with the inf. olivary nucleus of medulla. It descends through the tegmentum of midbrain dorsal to the red nucleus then continues down through the pons & medulla.

(7) Dorsal longitudinal fasciculus: it is a bundle descending & ascending autonomic fibres connecting the hypothalamus with the visceral nuclei in the brain stem. It is in the central grey matter of the midbrain.

(8) Medial Longitudinal bundle: see next page.

# Medial Longitudinal Bundle

\* Definition: it is an important associative coordinating bundle found in all levels of the brain stem.

\* Extent: it extends in the brain stem from the floor of the 3rd ventricle above to the lower end of medulla below.

\* Beginning: it begins just above the midbrain (below the floor of the 3rd ventricle) by receiving afferent fibres from 2 nuclei:  
(1) interstitial nucleus of Cajal (2) nucleus of post-Commissure.

\* Course: it runs in the post-part of the brain stem close to the middle line & ventral to the somatic motor nuclei of the cranial nerves 3, 4, 6, 7 & 12.

\* Termination: it ends in the lower part of the medulla by becoming continuous with the ant-intersegmental tract of the spinal cord.

\* Structure: it is formed of short ascending & descending fibres (mainly vestibular & cochlear) derived from the following nuclei:

- (1) all vestibular nuclei of both sides.
- (2) nucleus of lateral lemniscus (Cochlear).
- (3) nucleus of trapezoid body (Cochlear).

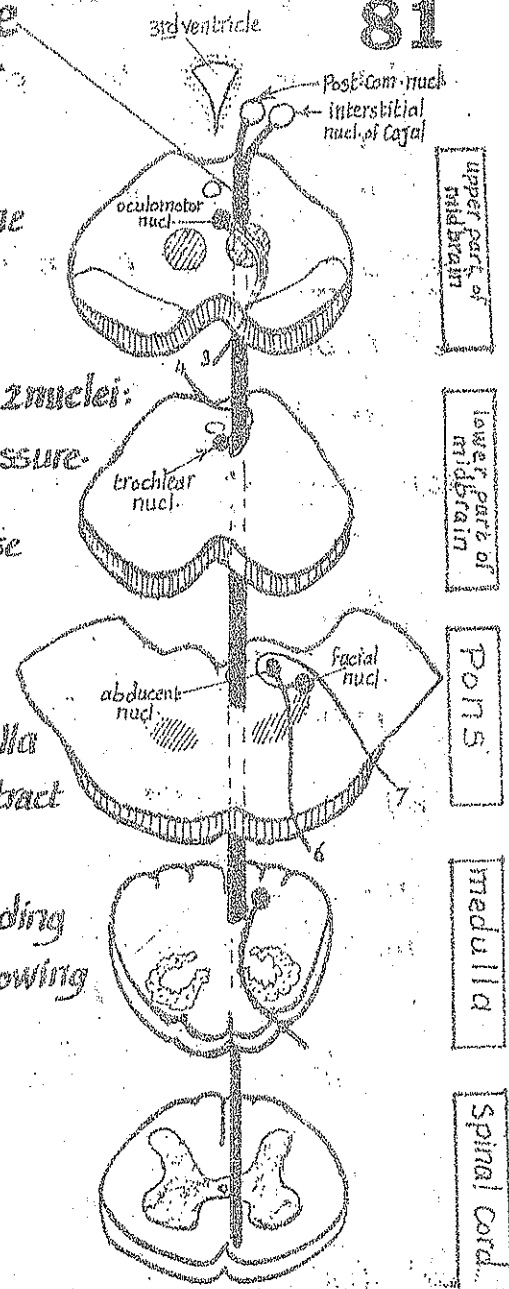
\* Connections & functions of the M-L-B:

(1) Vestibular reflex functions:

- (a) the M.L.B receives efferent fibres from the vestibular nuclei (equilibrium) & sends them up to the nuclei of the cranial nerves 3, 4 & 6 which control the eye movements. In this way the eyes move in relation to the movements of the head.
- (b) It also receives efferent fibres from the vestibular nuclei & sends them down to the A.H.Cs of the spinal cord. In this way the neck & trunk can move in relation to the movements of the head.

(2) Auditory reflex functions:

- (a) the M.L.B. receives efferent fibres from the sup. olive & from the lat. lemniscus (carrying hearing impulses) & sends them up to the nuclei of the cranial nerves 3, 4 & 6 allowing movements of the eye in response to sound.





(b) it also sends auditory impulses down to the A.H-Cs of the spinal cord allowing the movements of the neck & trunk in response to sound.

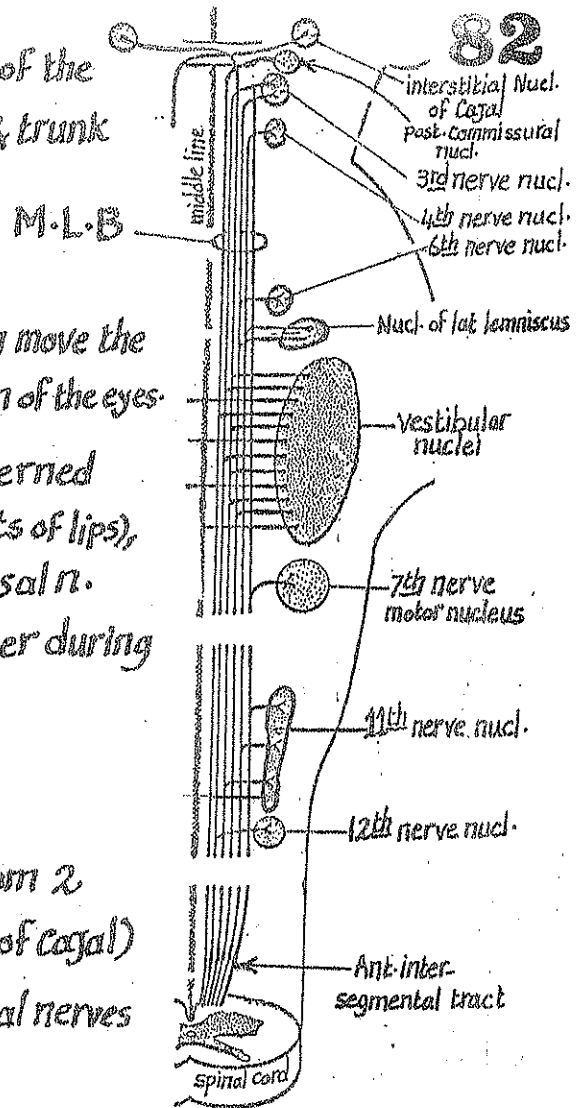
### (3) Associative internuclear function:

(a) It connects the nuclei of the cranial nerves which move the eye (3, 4 & 6) together allowing conjugate deviation of the eyes.

(b) it connects the nuclei of the cranial nerves concerned in the process of speech i.e : facial n. (movements of lips), cranial accessory (laryngeal muscles) & hypoglossal n. (tongue muscles) allowing them to work together during speech.

### (4) Extra-pyramidal function:

the M.L.B receives extrapyramidal fibres from 2 nuclei (post-commissural nucl. & interstitial nucl. of Cajal) & sends them to the motor nuclei of the cranial nerves & the A.H-Cs of the spinal cord



## Reticular formation of Brain stem

\* Definition: it is a diffuse system of a network of fine fibres intermingled with numerous poorly defined nuclei.

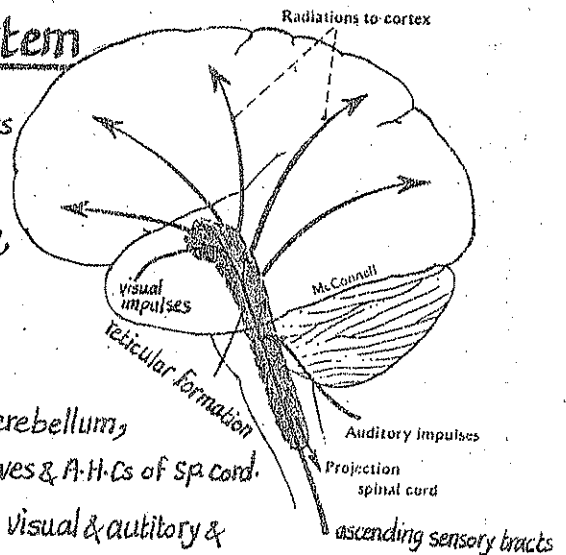
\* Location: it is placed in the dorsal part of the brain stem, having a diffuse distribution & ill-defined boundaries.

\* Connections: the reticular formation is connected to:

- (1) the motor neurones of the cerebral cortex, basal ganglia, cerebellum, extrapyramidal nuclei, nuclei of cranial nerves & A.H-Cs of Sp. cord.
- (2) the sensory neurones of cerebral cortex, thalamus, spinal cord, visual & auditory & equilibrium pathways through collaterals from the sensory pathways.
- (3) the autonomic neurones of the hypothalamus, limbic system & general visceral efferent columns.

\* Functions:

- (1) inhibition or facilitation of motor areas of voluntary & reflex activities of the body.
- (2) it is responsible for maintaining the state of wakefulness & alertness.
- (3) through its autonomic connections, it can influence respiratory & vasomotor activities by stimulation or inhibition (according to the needs).



## 5-Internal Structure of Cerebellum

83

\* The cerebellum consists of :

(A) outer layer of grey matter on the surface

forming the cerebellar cortex which contains nerve cells arranged into 3 layers as follows :

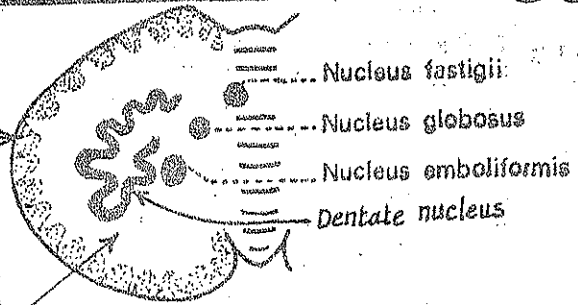
- (1) outer molecular layer
- (2) intermediate layer of Purkinji cells
- (3) inner granular layer

(B) Inner core of white matter

(C) Subcortical collection of grey matter nuclei within the white matter core.

These nuclei include :

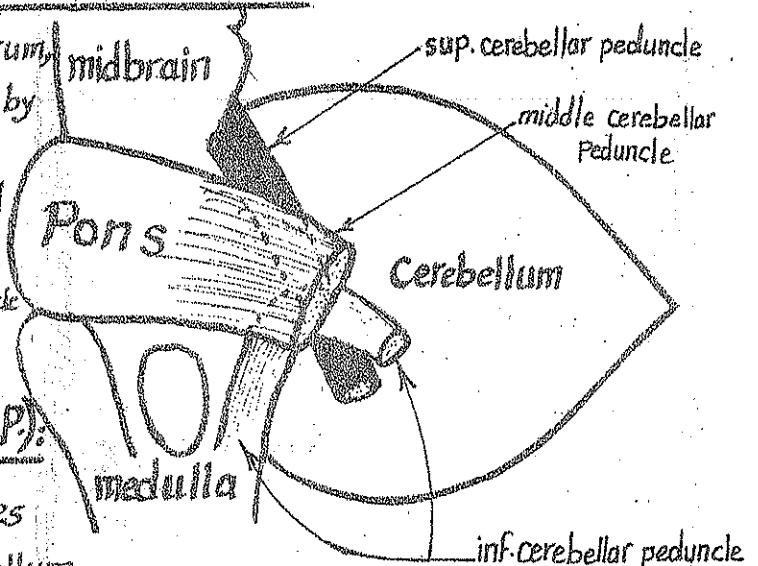
- (1) dentate nucleus (the largest nucleus) : it is a folded mass of grey matter situated at the centre of the white matter. It has a hilum from which most of the fibres of the sup. cerebellar peduncle emerge. Functionally, it belongs to the neocerebellum.
- (2) Emboliform nucleus : lies just medial to the dentate nucleus. It belongs to paleocerebellum.
- (3) Globose nucleus : lies just medial to the emboliform nucleus. " " " "
- (4) Fastigial nucleus : is the most med. nucleus. It belongs to the archicerebellum & receives direct vestibular fibres.



## Cerebellar Connections (Peduncles)

\* The cerebellum is connected with the cerebrum, the nuclei of the brain stem & the spinal cord by numerous afferent & efferent tracts.

\* these afferent & efferent tracts are collected into 3 great bundles on each side, called the cerebellar peduncles



### I- Inferior cerebellar peduncle (I.C.P.)

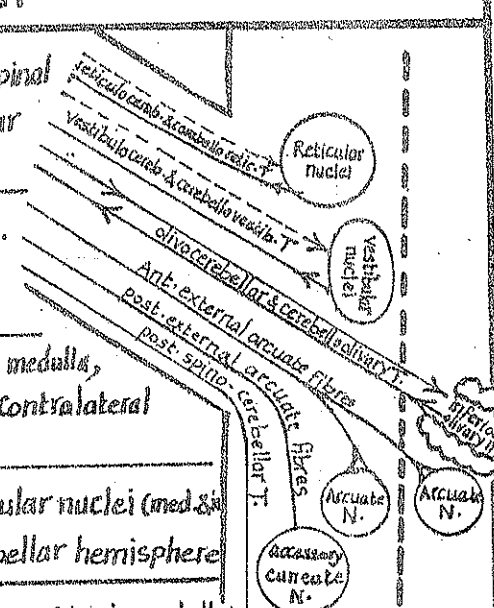
\* there are Rt. & Lt. inf. cerebellar peduncles which connect the medulla with the cerebellum.

\* each I.C.P. begins from the dorsolateral aspect of the upper  $\frac{1}{2}$  of medulla.

\* It ascends upwards & laterally along the lat. side of the 4<sup>th</sup> ventricle to reach the lower border of the pons where it bends sharply backwards at the ant-cerebellar notch to enter the corresponding cerebellar hemisphere between the M.C.P. (laterally) & the S.C.P. (medially).

# \*Types of fibres in the I.C.P.:

	Tract & its function	Origin & termination
Afferent fibres	(1) <u>Post-spino cerebellar T.</u> Carrying proprioceptive sensation from the lower 1/2 of the body.	arises from Clark's nucleus of the spinal cord & ends in the ipsilateral cerebellar hemisphere.
	(2) <u>Post-external arcuate</u> fibres: carrying proprioceptive sensation from the U.L.	arise from the accessory cuneate N. of medulla & end in the ipsilateral cerebellar hemisphere.
	(3) <u>Olivocerebellar tract</u> (extrapyramidal)	arises from the inf. olivary nucleus in medulla, cross to the opposite side to reach the contralateral cerebellar hemisphere.
	(4) <u>Vestibulo-cerebellar T.</u> Carrying equilibrium impulses.	arises from the vestibular n. & vestibular nuclei (med. & lat.) & passes directly to the ipsilateral cerebellar hemisphere.
	(5) <u>Reticulo cerebellar T.</u>	arises from the nuclei of reticular formation in medulla & passes to the ipsilateral cerebellar hemisphere.
Efferent fibres	(1) <u>Cerebello-olivary tract</u> (extrapyramidal)	arises from the dentate N. & passes to the contralateral inf. olivary N.
	(2) <u>Cerebello-reticular T.</u>	arises from the Fastigial nuclei of both cerebellar hemispheres & ends in the nuclei of the reticular formation in the pons & medulla.
	(3) <u>Cerebello vestibular T.</u>	arises from the flocculo-nodular lobe & ends in all vestibular nuclei.

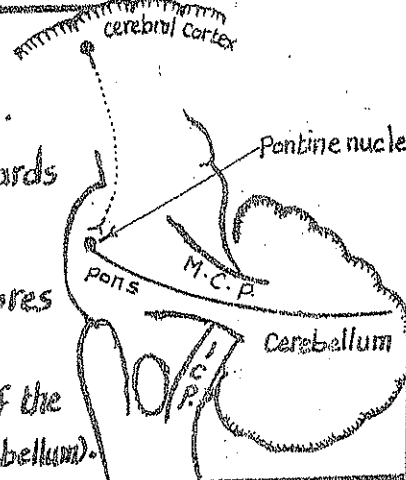


## II- Middle Cerebellar Peduncle (M.C.P.) Rt. & Lt.

\* Morphology: It is the thickest of the 3 peduncles:

- It is formed by the collection of the transverse pontine fibres.
- It emerges from the lat. aspect of the pons then curves backwards to enter the corresponding cerebellar hemisphere lat. to the I.C.P.

\* Types of fibres in the M.C.P.: It contains afferent fibres only (ponto cerebellar fibres) which arise from the pontine nuclei of the opposite side. These fibres constitute a part of the Cortico-ponto-cerebellar pathway (from the cerebral cortex to cerebellum).



## III- Superior cerebellar peduncle (S.C.P.) Rt. & Lt.

\* Morphology: It is the smallest & most medial of the 3 peduncles:

- It is a flattened band that emerges from the back of the midbrain below the inf. colliculus.
- It runs downwards & laterally along the side of the upper part of the 4th ventricle.

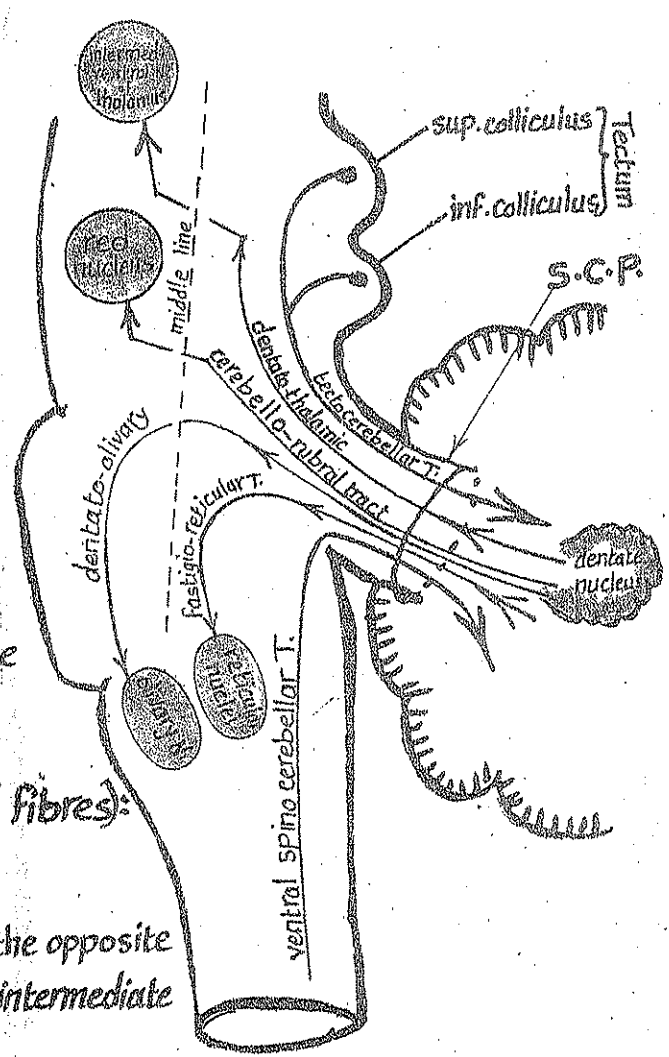
- It enters the corresponding cerebellar hemisphere med. to the I.C.P.
- the RT. & Lt. S.C. peduncles are connected together by the sup. medullary velum.

\* Types of fibres in the S.C.P.:

(A) Afferent fibres: only 2 tracts:

(1) Anterior spinocerebellar T.  
 - origin & course: see page 61  
 - it carries proprioceptive impulses from the lower limb to the cerebellum.

(2) Tecto-cerebellar T.  
 - arises from the sup. & inf. colliculi of the tectum of midbrain.  
 - it carries auditory & visual impulses to the cerebellum.



(B) Efferent fibres: (form the majority of fibres):

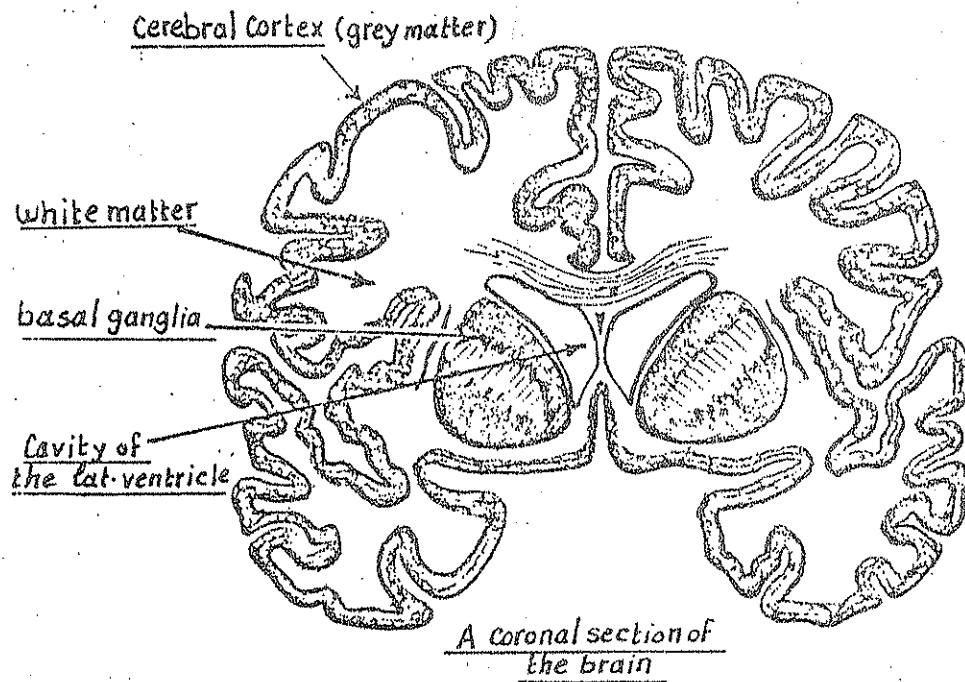
(1) Dentato thalamic T.:  
 arises from the dentate nucleus, crosses to the opposite side in the midbrain then ascends to end in the intermediate ventral nucleus of thalamus.

(2) Cerebello-rubral T.:  
 arises from the globose & emboliform nuclei, crosses to the opposite side in the midbrain then ascends to end in the red nucleus.

(3) Dentato-olivary T.:  
 arises from the dentate nucleus, crosses to the opposite side in the midbrain then descends to the inf. olivary nucleus in the medulla.

(4) Fastigio-reticular:  
 arises from the Fastigial nucleus & descends uncrossed to the reticular formation of the pons & medulla.

## 6 - Internal Structure of Cerebral hemisphere 86



Each Cerebral hemisphere consists of :

- (1) An outer layer of grey matter (Cerebral Cortex) on the surface .
- (2) White matter forming the Core of the hemisphere .
- (3) Basal ganglia (a collection of grey matter) embedded in the white matter Core .
- (4) Lateral ventricle (the cavity of the cerebral hemisphere) .

### The White matter of the Cerebral hemisphere

\* Consists of myelinated nerve fibres which are devoid of neurilemmal sheaths .

\* There are 3 types of fibres in the white matter :

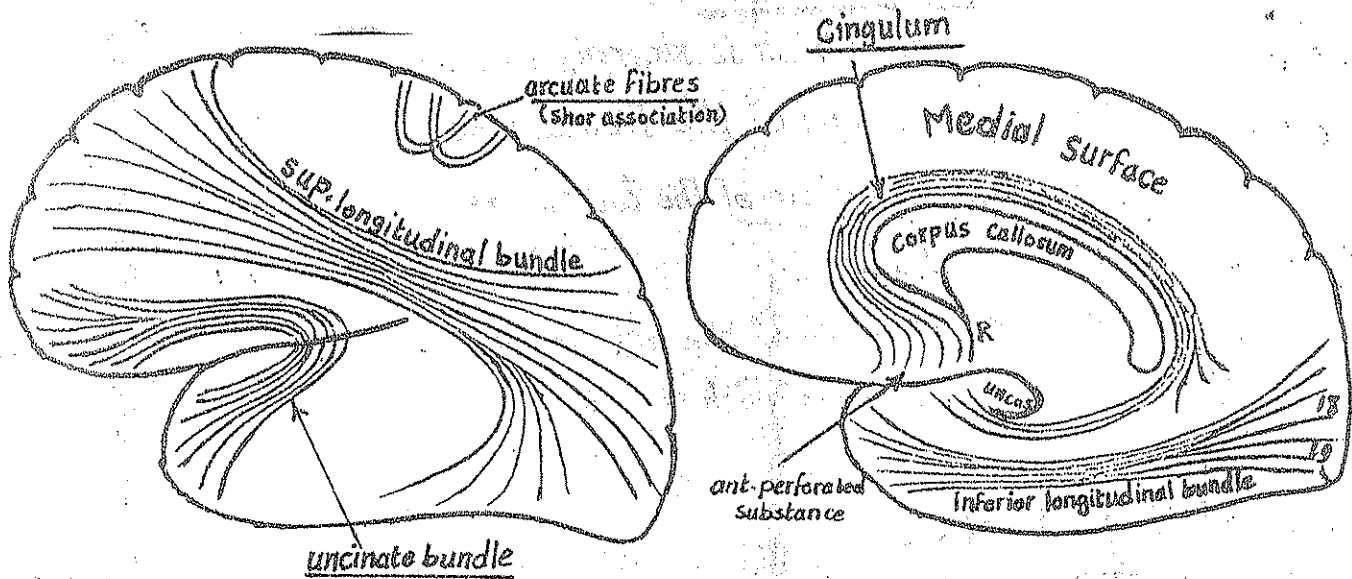
- (1) association fibres .
- (2) Commissural fibres .
- (3) projection fibres .

#### 1- Association fibres

\* Definition : they are fibres which connect the different cortical areas in the same hemisphere .

\* Function : they interrelate the functions of the different areas of the cortex & integrate the activities of cortex as a whole .

\* Types: there are 2 types of association fibres: Short & Long 87



### (A) Short association fibres:

- \* They consist of U-shaped bands called arcuate fibres lying just deep to the cerebral cortex.
- \* They connect adjacent gyri with one another.
- \* They are present in all parts of the hemisphere.

### (B) Long association fibres:

- \* They include 4 bundles of long fibres which connect the different lobes of the hemisphere together.
- \* These 4 bundles include:
  - (1) the sup. longitudinal bundle.
  - (2) the inf. longitudinal bundle.
  - (3) the Cingulum.
  - (4) the Uncinate bundle.

#### (1) The Superior longitudinal bundle:

- \* It is the largest association bundle.
- \* It begins in the ant. part of the frontal lobe.
- \* Course: it passes backward above the insula (deep to the lat. surface of the cerebral hemisphere) then divides into 2 bands:
  - (a) sup. band: enters the occipital lobe.
  - (b) inf. band: turns downwards to enter the temporal lobe.
- \* Function: it connects the frontal, occipital & temporal cortical areas together.

## (2) The Uncinate bundle:

88

- \* it is a U-shaped band which is sharply bent over itself.
- \* it begins at the orbital gyri of the frontal lobe.
- \* Course: it arches over the stem of the lat. sulcus to end in the ant. part of the temporal lobe.
- \* function: it connects the gyri of the orbital surface of the frontal lobe & the Broca's speech area with the cortex of the ant. part of the temporal lobe.

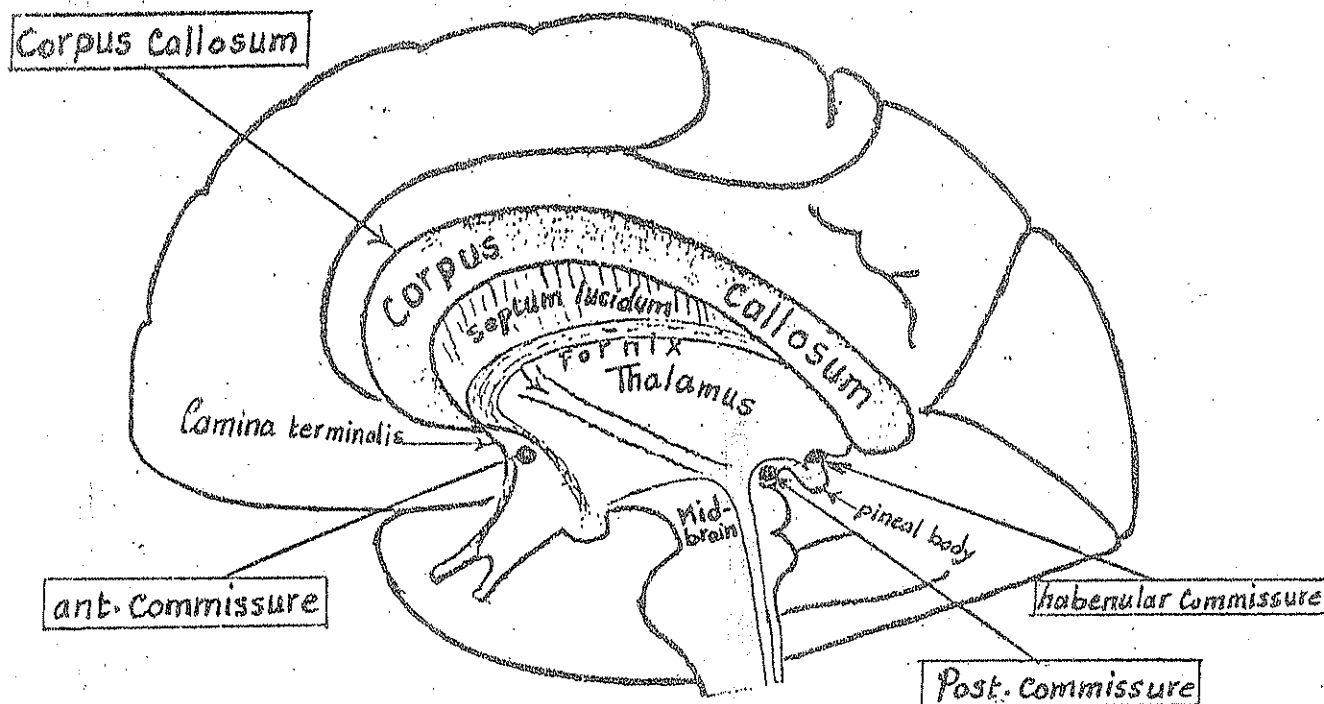
## (3) The Cingulum:

- \* It is a long curved bundle of association fibres lying in the medial aspect of the cerebral hemisphere forming an incomplete circle around the corpus callosum.
- \* it begins: below the rostrum of corpus callosum in the region of the ant. perforated substance.
- \* Course: it extends backwards in the cingulate gyrus then curves downwards in the Isthmus then passes forwards in the hippocampal gyrus to end in the uncus.
- \* function: throughout its course it gives off fibres to, & receive additions from the different cortical areas on the med. surface associating them.

## (4) The Inferior longitudinal bundle:

- \* it is a bundle of association fibres running horizontally close to the tentorial surface of the C. hemisphere.
- \* it begins: near the occipital pole (its fibres are derived mainly from areas 18 & 19)
- \* Course: the fibres sweep forwards close to the inf. surface of the temporal lobe to end at the temporal pole.
- \* function: connects the different cortical areas of the tentorial surface together.





\* A Commissure : is a band of white matter (nerve fibres) connecting a part of the C.N.S on one side with the same part on the opposite side.

\* Function : Co-ordination of the activities of the Rt. & Lt. Cerebral hemispheres.

\* the Commissural fibres are collected in the following bundles:

- |  |   |   |
|--|---|---|
| <ul style="list-style-type: none"> <li>(1) The Corpus Callosum</li> <li>(2) The ant. Commissure</li> <li>(3) The hippocampal commissure</li> </ul> | } | Connect the <u>2 Cerebral hemispheres</u> . |
|--|---|---|

(4) The post. Commissure: between the 2 sides of the Midbrain.

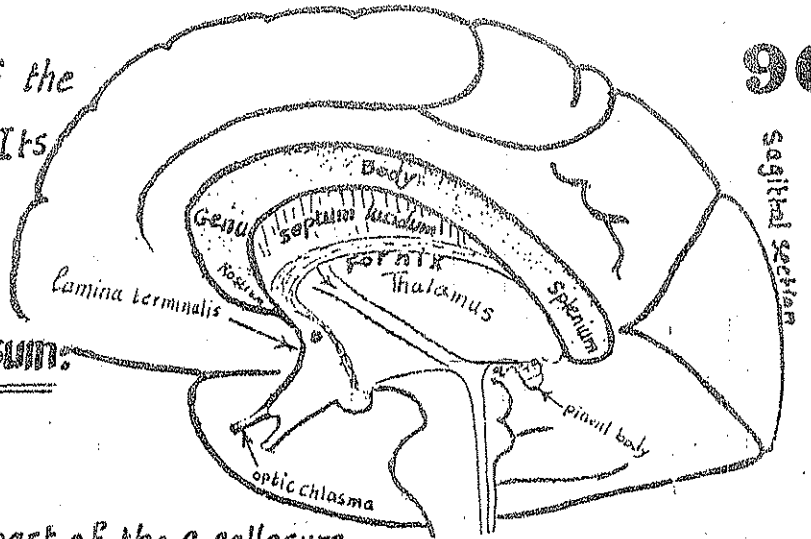
(5) The Habenular Commissure: between the Rt. & Lt. habenular nuclei of the Epithalamus.

### 1- The Corpus Callosum

\* It is the largest & the main Commissure of the brain.

\* Its fibres connect nearly all the symmetrical areas of the 2 hemispheres (with the exception of the olfactory bulbs & the temporal poles of both sides).

\* Site: it lies at the bottom of the median longitudinal fissure. Its inf. surface is attached to the Fornix by the Septum pellucidum.



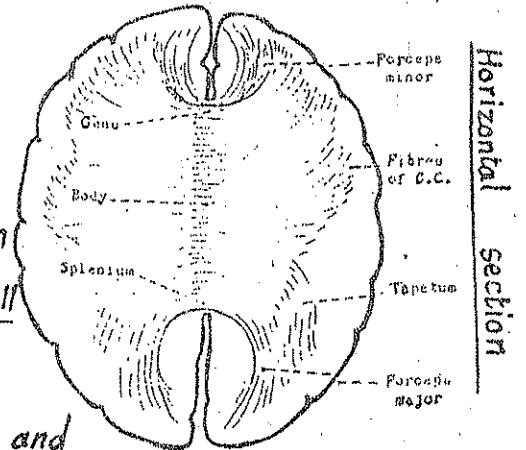
\* Parts of the Corpus Callosum:

### (1) Rostrum:

- it is the downward tapering part of the C. callosum
- it is connected to the optic chiasma by a thin sheet of grey matter (the lamina terminalis)
- it forms the floor of the ant. horn of the lat. ventricle
- the fibres of the rostrum connect the orbital surfaces of the 2 frontal lobes.

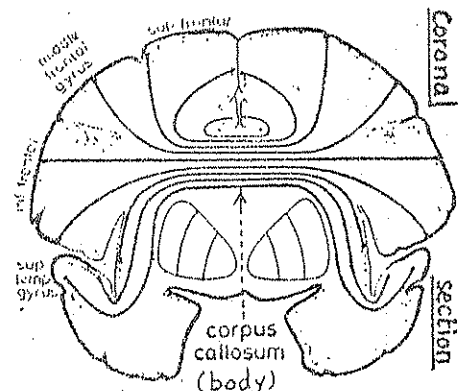
### (2) Genu:

- it is the most ant. part of the Corpus Callosum.
- its post. surface is connected to the septum pellucidum in the median plane & on each side it forms the ant. wall of the ant. horn of lat. ventricle.
- the fibres passing through the genu curve forwards and medially on each side to form an arch called the Forcep minor which connects the ant. parts of the 2 frontal lobes together.



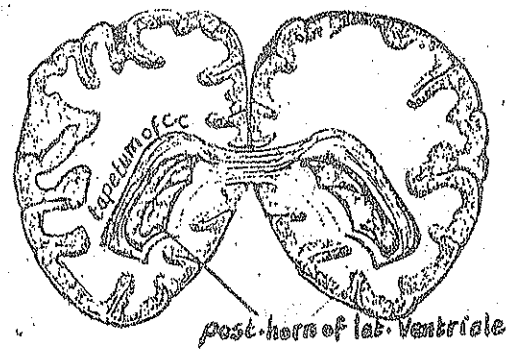
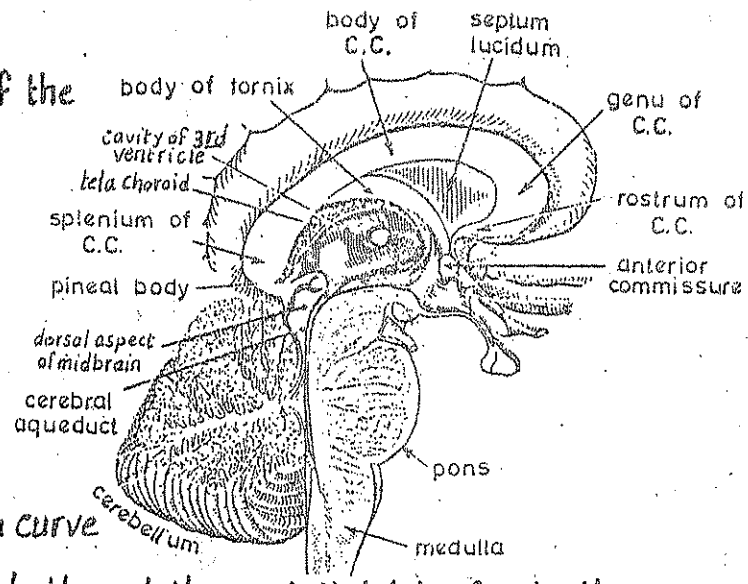
### (3) Body (trunk):

- it is the main part of the corpus Callosum
- its lower surface is attached in the median plane to the septum pellucidum (anteriorly) & to the body of the Fornix (posteriorly)
- on each side of the median plane, the lower surface of the body of C. Callosum forms the roof of the ant. horn & central part of each lateral ventricle.
- the fibres of the body pass transversely, but after crossing the middle line they diverge upwards, laterally & downwards in each hemisphere to connect the different areas of the parietal lobe & post part of frontal lobe of both sides together.



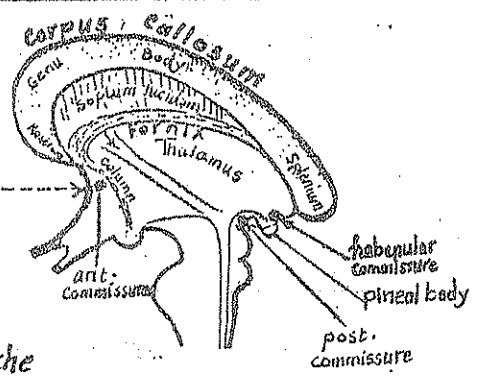
**(4) Splenium:**

- \* It is the rounded post-end of the corpus callosum.
- \* it overlies the pineal body & the dorsal aspect of midbrain & is separated from the roof of the 3rd ventricle by a thin sheet of pia matter called tela choroidea.
- \* Most of the fibres of the splenium curve backwards & medially on each side through the occipital lobe forming the forceps major.
- \* some of the fibres of the splenium & the post-part of the body of C. Callosum pass laterally & downwards forming the roof & lat-wall of the post-horn of the lat. ventricle. These fibres constitute the tapetum of Corpus Callosum.



**2- The Ant. Commissure**

- \* It is a small rounded bundle which crosses the median plane behind the lamina terminalis & in front of the columns of the fornix forming a part of the ant-wall of the 3rd ventricle.
- \* Its fibres connect the olfactory bulbs & the ant-part of the temporal lobes.



**3- The Habenular Commissure**

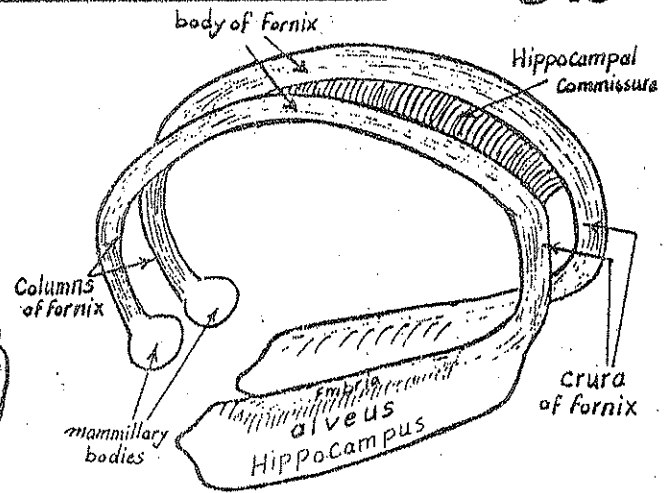
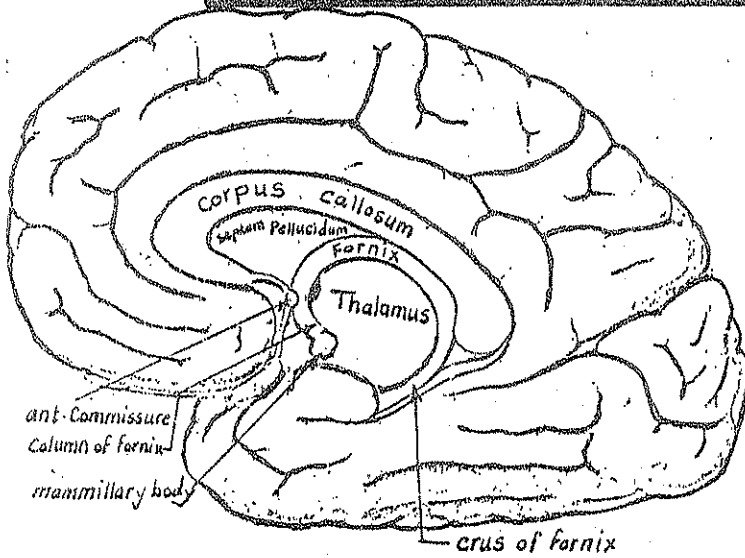
- \* It is a bundle of commissural fibres which cross the median plane above the roof of the pineal body.
- \* It connects the habenular nuclei of the 2 sides of the epithalamus together.

**4- The Posterior Commissure**

- \* It is a rounded bundle of commissural fibres that cross the median plane behind the upper end of the aqueduct of midbrain.
- \* it connects the sup. colliculus, the pretectal nucleus & the med. longitudinal bundle of both sides of the midbrain together.

**[The Hippocampal Commissure]** : see the Fornix page 92

# The Fornix & the Hippocampal Commissure



\* **The Fornix** : is an arched structure formed by the axons of the cells of the hippocampus.

These axons are projection fibres which will finally end in the mammillary body.

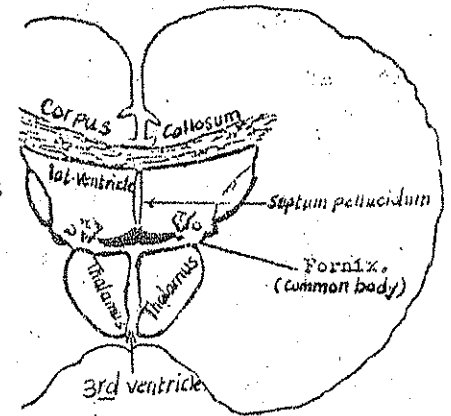
\* **Structure** : Each fornix is formed of the following parts : crus  
body  
column

(1) **Crus (post. column)** : posteriorly :

- the axons of the hippocampal cells spread to form the alveus.
- the fibres of the alveus collect to form a band of fibres med. to the alveus called the Fimbria
- the fibres of the fimbria curve upwards to form the crus of the fornix which turns round the post. end of the thalamus.

(2) **Body of the fornix** :

- the Rt. & Lt. crura pass upwards & medially approaching each other beneath the splenium of C. Callosum, then each crus proceeds as the body of the fornix.
- the bodies of the 2 fornices are connected together by the hippocampal commissure forming a common triangular body (narrow in front & wide behind).
- the upper surface of the common body is attached to the under surface of the C. Callosum by a membrane called septum pellucidum. On each side of this septum the body of the fornix lies in the floor of the central part of the lat. ventricle.
- the lower surface of the common body rests on the upper surface of the 2 thalami & the ependymal roof of the 3rd ventricle.



(3) **Column (ant. column)** : is the downward continuation of each body which descends in front of the interventricular f. & behind the ant. commissure to end in the mammillary body of the hypothalamus.

\* Definition: they are the afferent & efferent fibres of the cerebral cortex which pass through the internal capsule & connect the cerebral cortex with lower centres.

\* Types: the projection fibres are either:

- (a) Ascending (afferent) to the cerebral cortex from the thalamus.
- (b) Descending (efferent) from the cerebral cortex to lower centres.

## (A) Ascending fibres (thalamic radiations)

\* They are the fibres which radiate from the thalamus & metathalamus to the cerebral cortex:

(1) Ant-thalamic radiation: ascends from the ant. & med. nuclei of the thalamus to the frontal lobe.

(2) Superior thalamic (sensory) radiation: ascends from the posterior ventral nucleus of thalamus to the postcentral gyrus.

(3) Posterior thalamic radiation which consists of

(a) optic radiation: the fibres which arise from the lat. geniculate body & pass to the visual sensory area of the occipital lobe.

(b) auditory radiation: the fibres which arise from the med. geniculate body & pass to the auditory sensory area of the temporal lobe.

## (B) Descending fibres (mainly pyramidal & extrapyramidal)

\* they include:

(1) Corticospinal fibres: arise from the motor area in the precentral gyrus & descend to the A.H-Cs of the spinal cord.

(2) Cortico-bulbar fibres: arise from the precentral gyrus & descend to the motor nuclei of the cranial nerves in the brain stem.

(3) Cortico pontine fibres: which constitute a part of the pontocerebellar pathway

- & include
- (a) Fronto-pontine fibres.
  - (b) parieto-pontine "
  - (c) occipito-pontine fibres.
  - (d) temporo-pontine "

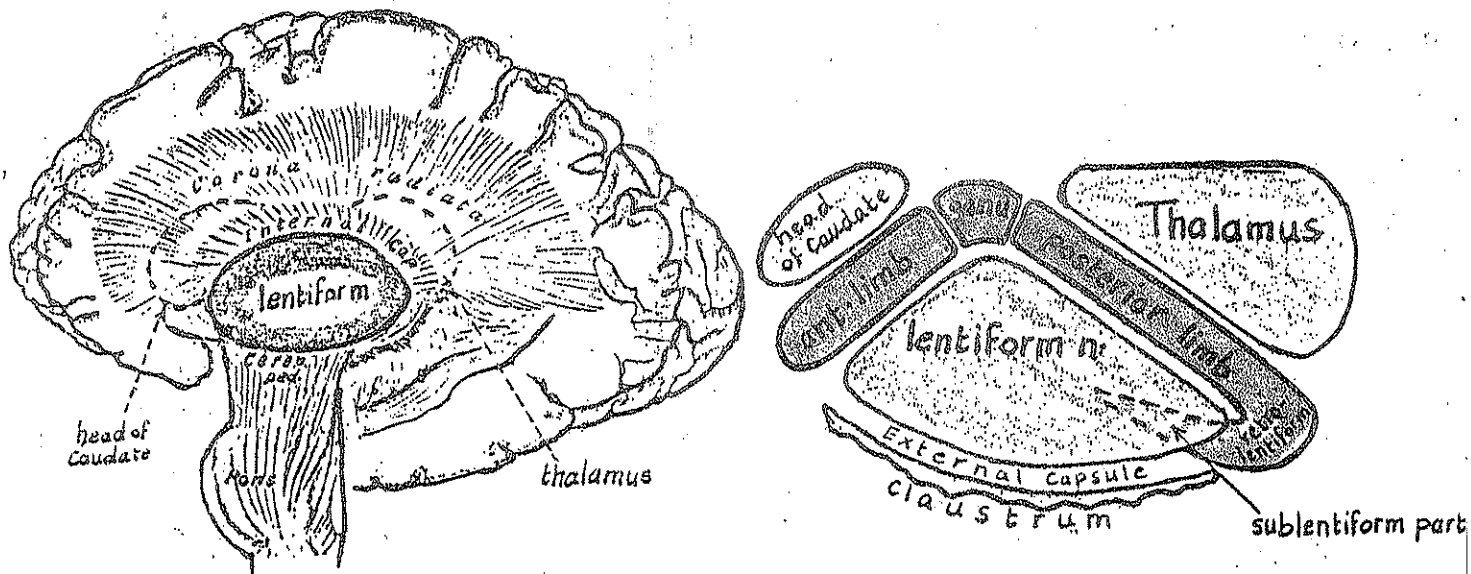
(4) Cortico-rubral fibres: descending from the frontal lobe to the red nucleus in the midbrain.

(5) Cortico-striate fibres: descending from the cerebral cortex to the corpus striatum.

N.B: all the above-mentioned projection fibres collect in the Internal Capsule (p. 95).

# The Internal Capsule

94



\* Definition: it is a broad lamina of white matter made up of projection fibres which pass to & from the cerebral cortex. It is so called because it forms an internal (inner) Capsule to the lentiform nucleus.

\* Continuity: it is continuous above with the Corona radiata & is continuous below with the cerebral peduncle of the midbrain.

\* Site: it lies medial to the lentiform nucleus & lat. to the head of caudate nucleus & the thalamus.

\* Shape: it is a folded lamina which is V-shaped in transverse section with its concavity directed laterally.

\* Parts & relations : it has the following parts:

- (1) A short anterior limb : lies between the head of caudate (medially) & the lentiform nucleus (laterally).
- (2) A long posterior limb : lies between the thalamus (medially) & the lentiform nucleus (laterally).
- (3) Genu (apex) : it is the angular junction between the ant. & the post. limbs it lies between the head of caudate (anteriorly) & the thalamus (posteriorly).
- (4) Retrolentiform part : lies behind the lentiform nucleus.
- (5) Sublentiform part : lies below the lentiform nucleus.

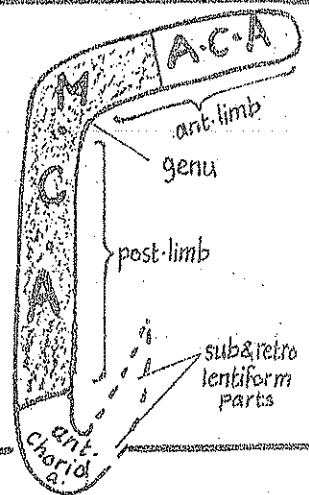


# \* Types of projection fibres passing through the int. capsule: 95

	Descending tracts	Ascending tracts
Anterior limb	Frontopontine fibres: from the <u>frontal lobe</u> to the <u>pontine nuclei</u>	Anterior thalamic radiation: From the <u>ant. &amp; med. thalamic nuclei</u> to the <u>frontal lobe</u> .
Genu	Cortico-bulbar fibres of the pyramidal tract: from the <u>precentral gyrus</u> to the <u>motor nuclei</u> of the cranial nerves	
Posterior limb	(1) Corticospinal part of the pyramidal T. (in the <u>ant. 1/2</u> of the <u>post. limb</u> ). (2) <u>Fronto-pontine fibres</u> (3) <u>Cortico-rubral fibres</u>	Sup. thalamic (sensory) radiation from the <u>P.L.V.N. &amp; P.M.V.N.</u> of thalamus to the <u>sensory area</u> in the <u>post central gyrus</u> . This sensory radiation passes in the <u>post. 1/2</u> of the <u>post. limb</u> .
Retro-lentiform	<u>parieto-pontine &amp; occipito-pontine fibres</u> descending to the <u>pontine nuclei</u>	<u>optic radiation</u> : from the <u>L.G.B.</u> to the <u>visual sensory area</u> in <u>occipital lobe</u> .
Sub-lentiform	<u>temporo pontine fibres</u> from the <u>temporal lobe</u> to the <u>pontine nuclei</u>	<u>Auditory radiation</u> : from the <u>M.G.B</u> to the <u>auditory sensory area</u> in the <u>temporal lobe</u> .

## \* Blood Supply of the internal Capsule:

- (1) the ant. part of ant. limb: supplied by the ant. cerebral a.
- (2) the post. part of ant. limb + genu + post. limb: supplied by the middle cerebral artery.
- (3) the retro & sublentiform parts: supplied by the ant-choroidal a. (branch of int. carotid a.)



## The Corona Radiata

- \* It is a fan-shaped "radiating" sheet of projection fibres.
- \* Its fibres converge inferiorly to form the internal capsule.
- \* its fibres diverge superiorly in a fan-like fashion, both antero-posteriorly & transversely, to reach the cerebral cortex of all lobes of the hemisphere.

# 7- Internal Structure of the basal ganglia (Nuclei)

\* The basal ganglia include :

- (1) Corpus striatum
  - Caudate nucleus
  - lentiform nucl.
    - ← putamen & globus pallidus
- (2) Amygdaloid nucleus
- (3) Clastrum.

## (1) Corpus Striatum

\* It is an important extrapyramidal centre.  
 \* the caudate nucl. & putamen represent the receptor nuclei which receive most afferent fibres

\* the globus pallidus represents the effector part giving rise to most efferent fibres.

\* Connections of Corpus striatum :

- A- Afferent fibres : derived From :

- (1) Cerebral cortex (via Cortico striate Fibres).
- (2) thalamus (via thalamo striate Fibres).
- (3) Substantia nigra (via nigro striate Fibres).

- B- Efferent fibres : emerge from the globus pallidus in the form of bundles which pass to other extrapyramidal centres as follows :

- (1) Ansa lenticularis
  - (2) fasciculus lenticularis
  - (3) subthalamic fasciculus
- } to the subthalamus

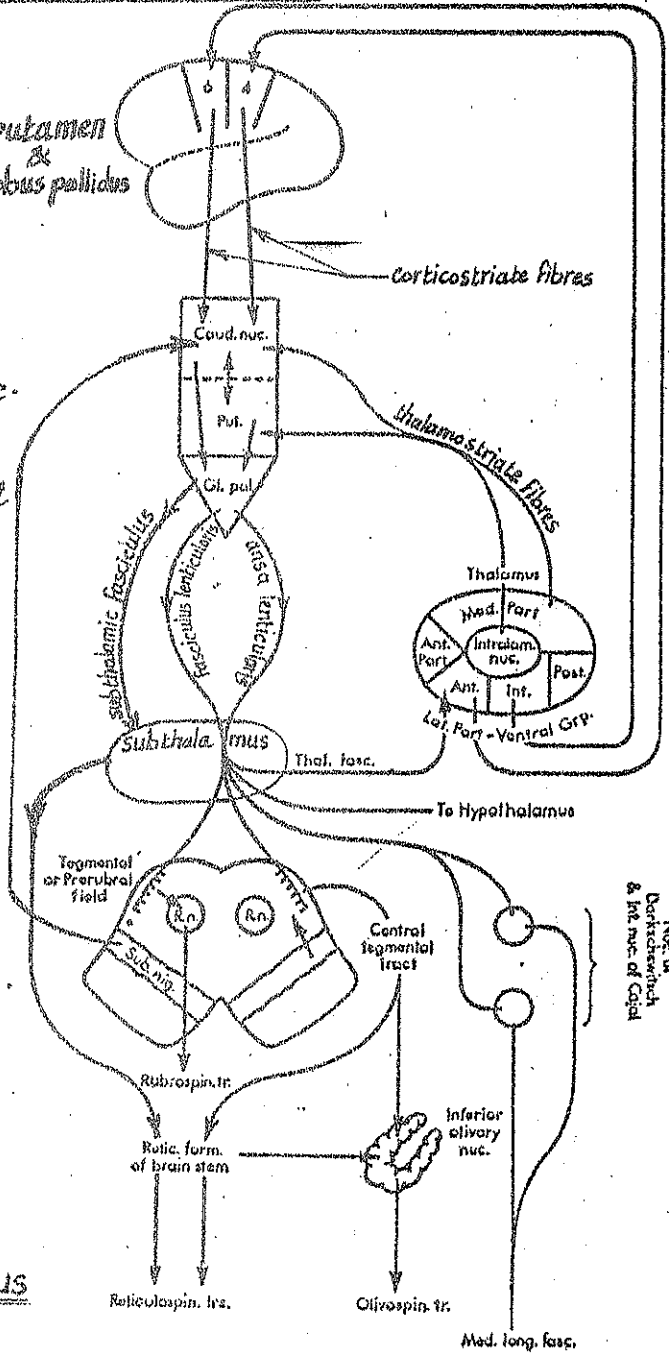
the fibres then proceed from the subthalamus as follows :

- 80% of the fibres descend to the tegmentum of midbrain, substantia nigra, red nucleus, inf. olivary nucleus & reticular formation of the midbrain.
- 15% form the thalamic fasciculus to the ant-ventral nucleus of the thalamus.
- 5% form the hypothalamic fasciculus which passes to the hypothalamus.

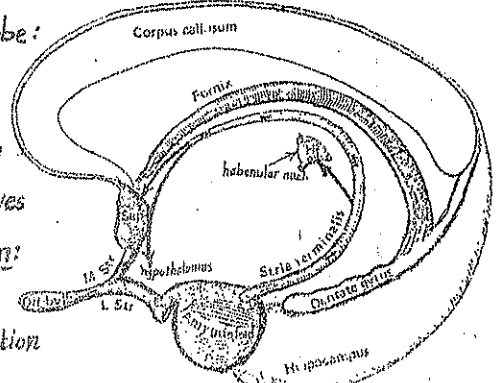
## (2) Amygdaloid nucleus (body) : part of the limbic lobe :

\* Afferents : it receives afferent fibres from the olfactory tract.

\* Efferents : its efferent fibres constitute the stria terminalis which passes first backwards in the roof of the inf-horn of lat-ventricle then curves forwards in the floor of the central part of the lat-ventricle. The fibres end in :  
 (1) septal nuclei in the septum lucidum (2) ant-nuclei of hypothalamus  
 (3) habenular nuclei. The stria terminalis serves as a pathway for association of olfactory & visceral functions.



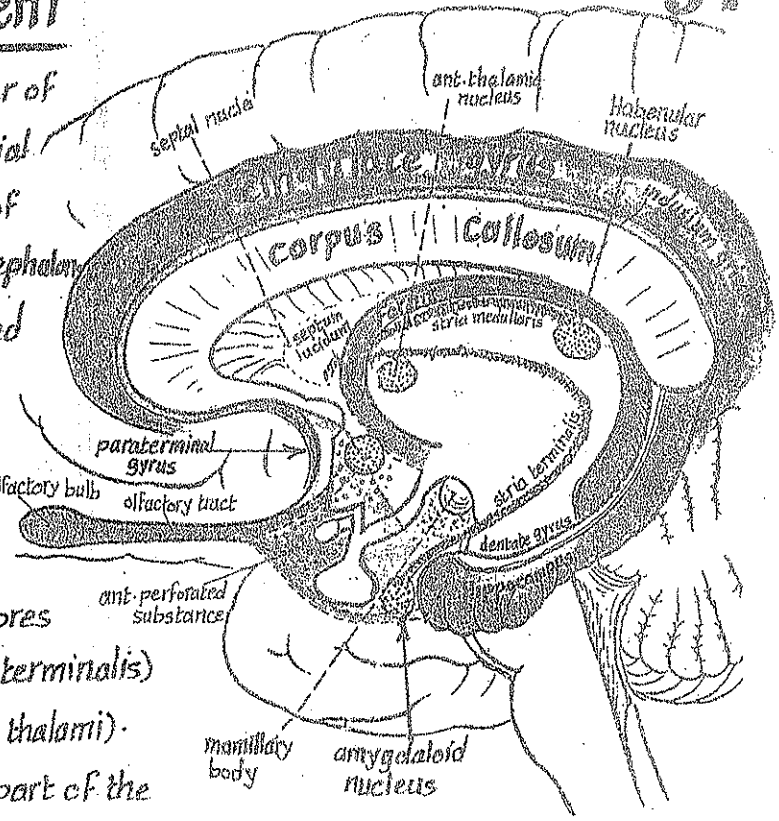
Nuc. of Dorsomedial & Inf. nuc. of Caud.



# Limbic System

\* Definition: it is the name applied to number of cortical & subcortical structures lying on the medial surface of the cerebral hemisphere in the form of an arch (limbus). It was formerly named rhinecephalon.

\* Structure: it consists of several olfactory and non-olfactory components:



A-olfactory components include:

(1) Olfactory bulb & tract which reach the following parts of the limbic system:

- (a) the ant. perforated substance from which fibres proceed to the amygdaloid nucleus (via stria terminalis) & to habenular nucleus (via stria medullaris thalami).
- (b) the piriform area including the uncus & ant. part of the hippocampal gyrus.

(2) Hippocampal formation which includes: hippocampus, dentate gyrus, indusium griseum (thin sheet of grey matter covering the upper surface of corpus callosum) & med. longitudinal striae (2 fibre bands on the upper surface of corpus callosum extending from the dentate gyrus to the paraterminal gyrus).

(3) Paraterminal gyrus: a narrow vertical gyrus lying below the rostrum of corpus callosum. It is continuous above with indusium griseum & below with the medial olfactory stria.

(4) Septum pellucidum: lying in the median plane just below the corpus callosum & formed of nerve fibres in addition to collection of septal nuclei which constitute part of the limbic system.

(5) The Fornix (page 92): it is the efferent pathway of the hippocampus which reaches the mamillary body (from which fibres are projected to the ant. nucleus of thalamus then to the cingulate gyrus).

B) Non-olfactory components include: (1) cingulate gyrus. (2) parahippocampal gyrus.

\* Connections of the limbic system: it is interconnected with the following centres:  
(1) cerebral cortex (2) thalamus (3) hypothalamus (4) epithalamus.

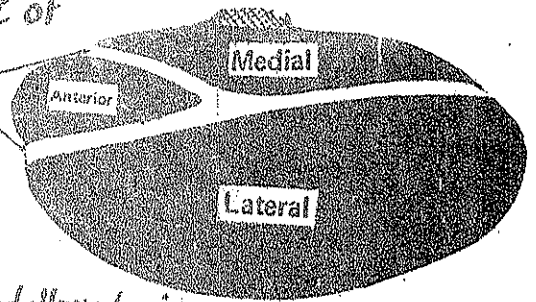
\* Functions of the limbic system:

- (1) reception of olfactory stimuli.
- (2) integration of olfactory, visceral & somatosensory sensations.
- (3) influencing the behaviour, emotional reactions & memory of the individual.

# 8-Internal Structure of the diencephalon

## (A) Thalamus

\* The thalamus is divided by a Y-shaped sheet of white matter called internal medullary lamina into 3 main parts:



(1) anterior part: between the 2 anterior limbs of the internal medullary lamina.

(2) medial part: lying med. to the post-limb of the medullary lamina.

(3) lateral part: lying lat. to the post. limb of the medullary lamina.

## Thalamic Nuclei

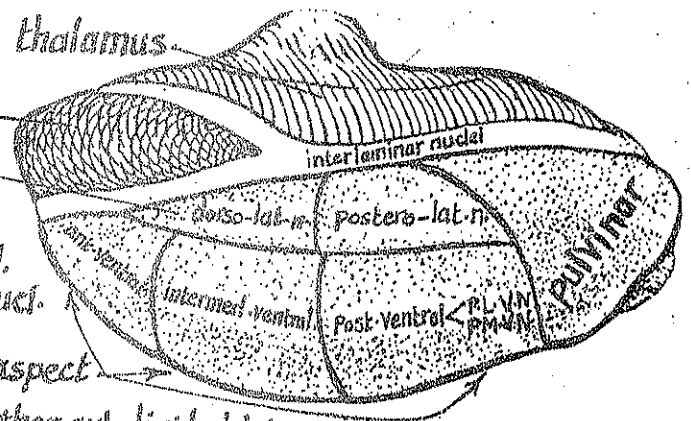
\* The 3 parts of the thalamus consist of a number of nuclear groups, each of which has its specific function (sensory, extra-pyramidal or non specific).

\* The nuclear groups of the thalamus are classified as follows:

(1) Medial group: in the medial part of the thalamus.

(2) Ant-group: in the ant-part of the thalamus.

(3) Lat-group: in the dorsolateral aspect of the lat-part of the thalamus & is subdivided into 2 nuclei



(4) Ventral group: lying in the ventromedial aspect of the lat. part of of the thalamus & is further subdivided into 3 nuclei:

(a) anterior ventral nucleus.

(b) intermediate ventral nucleus.

(c) posterior ventral nucleus which is further subdivided into

Postero-lat. ventral nucl. (PL.V.N).  
postero-med. ventral nucl. (PM.V.N).

(5) Non-specific nuclei which include

intra-laminar n. (in the internal medullary lamina).  
reticular n. (on the lat. surface).  
middle line n. (on the med. surface close to the 3rd ventricle).

## Functions of the thalamus

(1) Sensory function: the thalamus is the great sensory relay station on the pathway of all sensations (except smell) to the cerebral cortex. It acts like "Secretary" for the cerebral cortex (integrating the sensory impulses then projecting them to the cortical & subcortical areas).  
NB: The thalamus is capable of appreciating painful & thermal stimuli.

(2) Consciousness: through its connections with the reticular activating system, the thalamus participates in maintenance of the state of alertness & wakefulness.

(3) Emotional function: through its connections with the frontal lobe & hypothalamus, the thalamus appears to be concerned with the emotional content & subjective feelings.

# Connections of the thalamic nuclei

Nucleus	Afferents	Efferents	Function	
Anterior N.	mamillothalamic tract from mamillary body.	to the Cingulate gyrus (part of the limbic lobe)	relay station for hippocampal impulses.	
Medial N.	(1) prefrontal cortex of the frontal lobe (2) Corpus striatum (3) hypothalamus (4) other thalamic nuclei	to the same parts from which afferents are received.	relay station for visceral impulses.	
Lateral N.	(1) precuneus & superior parietal lobule (2) other thalamic nuclei	to precuneus & sup. parietal lobule.		
Anterior Ventral N.	(1) subthalamic fasciculus from globus pallidus (2) from reticular formation of the brain stem.	to areas 6 & 8 of the frontal cortex	relay station for extrapyramidal impulses	
Inter-mediate Ventral N.	(1) dentatothalamic fibres from the opposite cerebellar hemisphere (2) rubrothalamic fibres from the red nucleus	to the motor & premotor areas of the frontal cortex (areas 4 & 6).	relay station for cerebellar impulses concerned with integration of muscle tone.	
Postero-lateral Ventral N.	(1) spinal lemniscus (2) medial lemniscus	to the post-central gyrus of parietal lobe (areas 3, 1, 2)	relay station for exteroceptive impulses & proprioceptive impulses from the opposite side of the body below the head.	
Postero-medial ventral N.	Trigeminal lemniscus	to the post central gyrus (areas 3, 1, 2).	relay station for exteroceptive & proprioceptive impulses from opposite side of head.	
interlaminar midline & reticular nuclei	From the reticular formation of the brain stem.	to all parts of the cerebral cortex.	participate in the arousal reactions of the brain.	



# B- Internal Structure of the hypothalamus

## \* Parts & nuclei:

(1) Optic part: grey matter immediately related to optic chiasma. It contains 2 nuclei:

- (a) supra optic N.: just above optic chiasma.
- (b) paraventricular N.: just above the supraoptic N.

(2) Tuberal part: tuber cinereum & infundibulum: it contains 3 nuclei:

- (a) Ventromedial nucleus.
- (b) dorsomedial nucleus.
- (c) tuberal nucleus.

(3) Mamillary part: the mamillary bodies - it contains 2 nuclei:

- (a) posterior nucleus (b) lateral nucleus.

(4) posterior perforated substance.

## \* Connections of hypothalamus:

### (A) Afferent fibres:

(1) From the brain stem & spinal cord: aff. fibres carrying visceral sensations reach the hypothalamus mainly via the dorsal longitudinal bundle

(2) From the limbic system:

- (a) From the hippocampus (via the fornix).
- (b) From the amygdaloid body (via Stria terminalis).

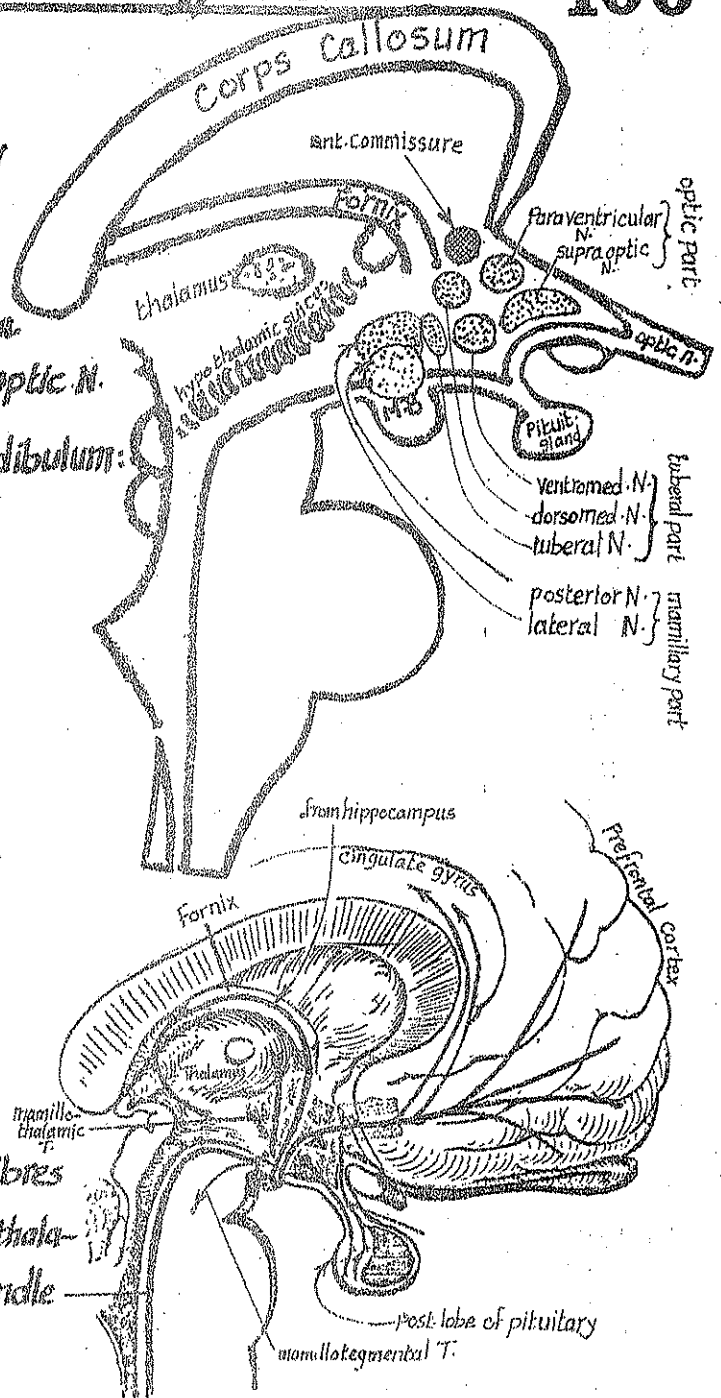
(3) From the prefrontal cortex: either directly or indirectly (through the med. nucleus of thalamus).

### (B) Efferent fibres

(1) to the brain stem & spinal cord:   
 → mamillo tegmental tract to the tegmentum of midbrain   
 → dorsal longitudinal bundle to the reticular formation of brain stem.   
 From the tegmentum of midbrain, & the reticular formation of the brain stem, descending autonomic fibres descend in the lat. column of the spinal cord to reach the lat. horn cells.

(2) to the limbic system: via the mamillo thalamic tract & the mamillo cortical fibres to the cingulate gyrus.

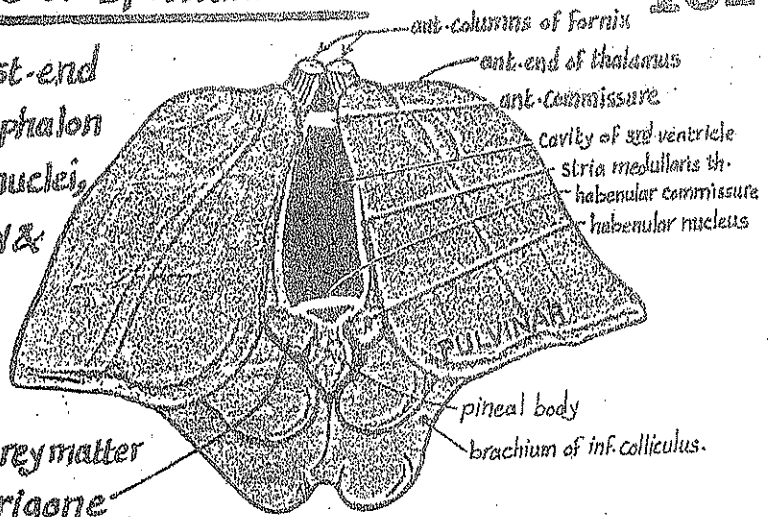
(3) to the pituitary gland: axons of the supraoptic & paraventricular nuclei terminate in the post. lobe of the pituitary.





# C- Internal Structure of Epithalamus

\* The epithalamus occupies the post-end of the upper surface of the diencephalon & consists of Rt. & Lt. habenular nuclei, habenular commissure, pineal body & post. commissure.



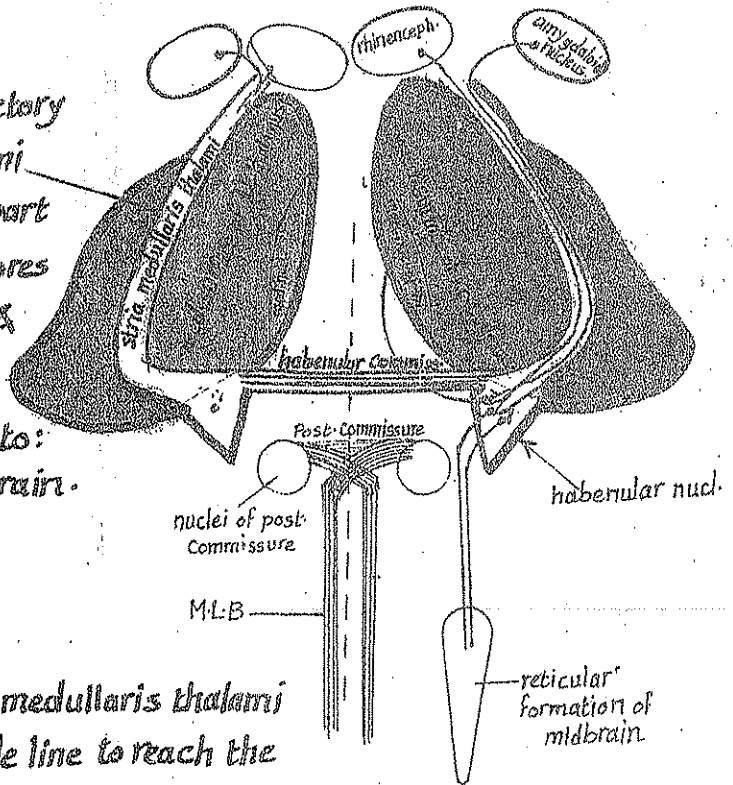
## (1) Habenular nucleus:

\* Site: each nucleus is a mass of grey matter which underlies the habenular trigone on the med. surface of the pulvinar just above the sup. colliculus.

\* Function: it constitutes a part of the olfactory reflex pathway.

### \* Connections:

(A) Afferent: it receives afferent olfactory fibres via the stria medullaris thalami (a band of fibres arching on the upper part of the med. surface of thalamus). Its fibres are derived from the rhinencephalon & the amygdaloid nucleus.



(B) Efferent: it gives efferent fibres to:  
 (1) reticular formation of the midbrain.  
 (2) medial nucleus of the thalamus.

## (2) Habenular Commissure:

it consists of fibres from the stria medullaris thalami (of both sides) which cross the middle line to reach the opposite habenular nucleus. This commissure runs in the upper root of the stalk of the pineal body.

## (3) Posterior Commissure:

\* it is formed of transverse decussating fibres which cross the middle line in the lower stalk of the lower root of the stalk of the pineal body.

\* Its constituent fibres are derived from the following nuclei of both sides:

- (1) post. Commissural nucl. (2) interstitial nucl. of Cajal (3) Darkschewitsch nucleus.

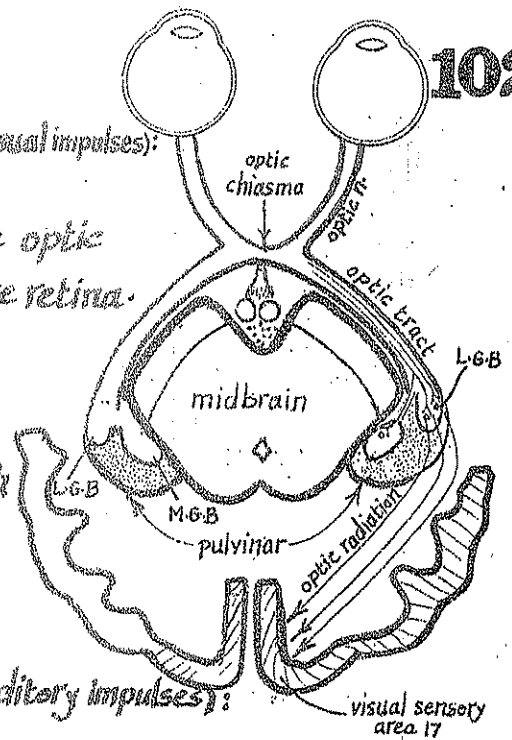
(4) Pineal body: it is composed of pinealocytes & neuroglial cells with rich network of blood vessels. Its function is probably enhancing the development of the gonads by influencing the output of gonadotrophins through the hypothalamus.

## D-The Metathalamus

(A) Lateral geniculate body (relay nucleus for visual impulses):

\* Afferents: it receives most of the fibres of the optic tract carrying visual impulses from the retina.

\* Efferents: its efferent fibres pass through the retrolentiform part of the internal capsule & form the optic radiation which ends in the visual sensory area 17 in the occipital c. rtex.

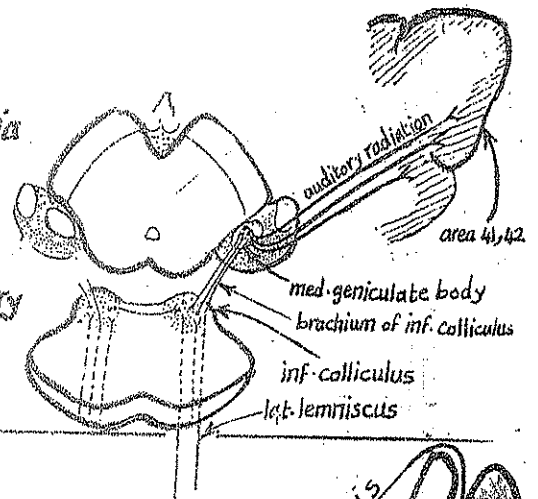


(B) Medial geniculate body (relay nucleus for auditory impulses):

\* Afferents: it receive auditory fibres:

- directly: from the lat. lemniscus
- indirectly: from the inf. colliculus of the midbrain via the brachium of inf. colliculus.

\* Efferents: it sends efferent fibres via the sublenticular part of the internal capsule to the auditory sensory area 41, 42 in the sup. temporal gyrus.



## E-The Subthalamus

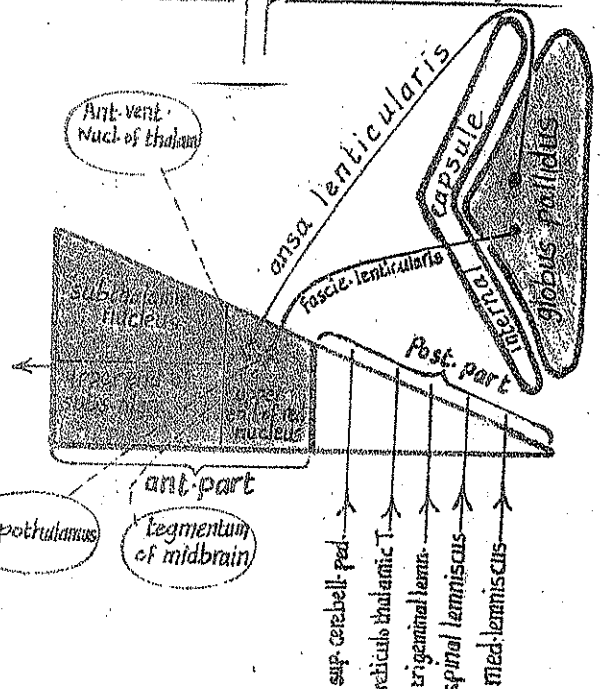
\* It consists of 2 parts:

(A) Post. smaller part: containing 5 bundles:

- (1) medial lemniscus
- (2) spinal lemniscus
- (3) trigeminal lemniscus
- (4) reticulo thalamic T.
- (5) sup. cerebellar peduncle.

(B) Ant. larger part: containing 5 structures:

- 3 nuclei:
  - upper end of the red nucleus.
  - upper end of the substantia nigra (hypothalamus)
  - the subthalamic nucleus.
- 2 descending bundles:
  - ansa lenticularis.
  - fasciculus lenticularis.



\* The ansa lenticularis: arises from the globus pallidus, makes a "loop" around the ant. border of the internal capsule then enters the upper end of the red nucleus.

\* The Fasciculus lenticularis: arises from the globus pallidus, pierces the post. limb of the int. capsule to reach the upper end of the red nucleus.

N.B: after reaching the red nucleus, the fibres of the ansa & fasciculus lenticularis pass to: (1) tegmentum of midbrain (Ant. vent. nucl. of thalamus (thalamic fasciculus) (2) to the hypothalamus (hypothalamic fasciculus).

## \* Oculomotor nerve (3rd cranial n.)

- Site of nucleus: it lies in the tegmentum of Midbrain ventral to the aqueduct of the midbrain at the level of the superior colliculus.

- Structure: the nucleus is formed of 3 main parts:

(1) the Edinger-Westphal nucleus: (parasympathetic) which supplies 2 intra-ocular muscles

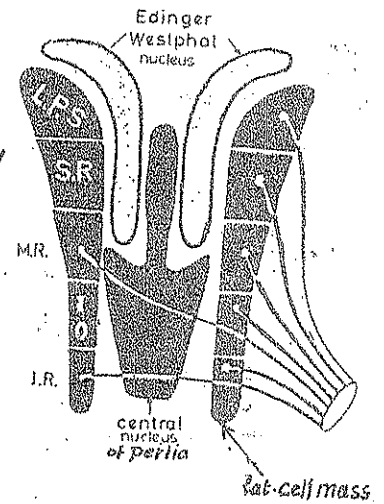
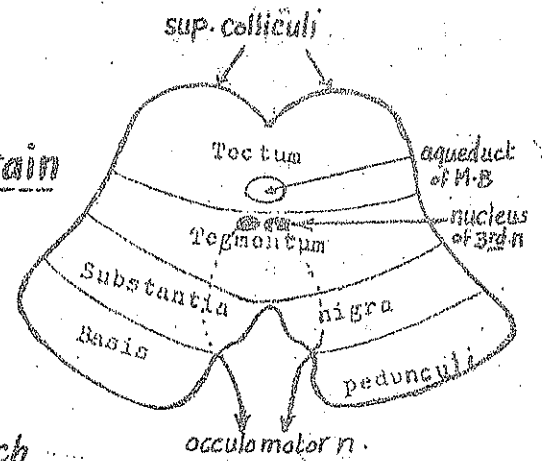
- (1) the constrictor pupillae m.
- (2) the ciliary muscle.

(2) the Lat-Cell mass: which is divided into 5 parts which supply

5 extra ocular muscles which are (from above downwards):

L.P.S, S.R, M.R, I.O & Inf. rectus.

(3) the Central nucleus of Perlia: supplies the 2 med-recti muscles of the 2 eyes allowing them to contract together when both eyes converge to look to a near object.

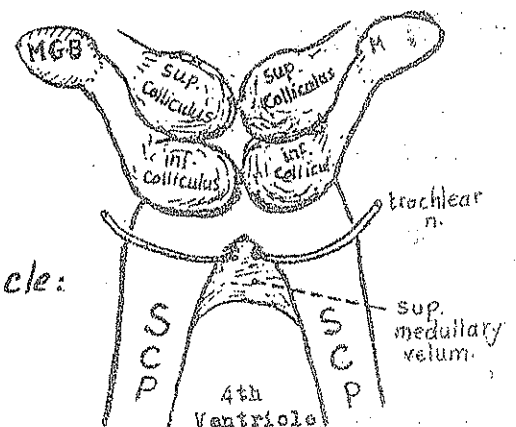
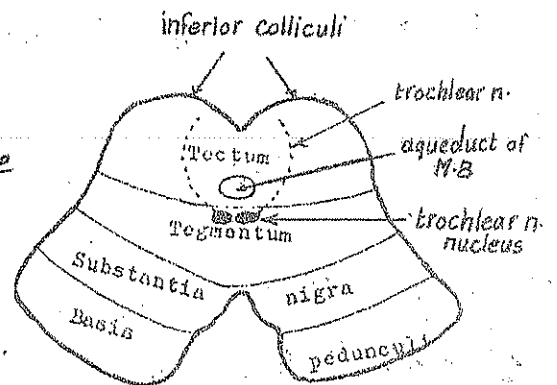


## \* Trochlear nerve (4th cranial n.)

- Site of the nucleus: it lies in the tegmentum of the Midbrain ventral to the aqueduct of M.B, at the level of the inferior colliculus.

- Type: it is a motor nucleus, its fibres constitute the trochlear n. which passes backwards around the aqueduct to emerge from the post. surface of the M.B below the inf. Colliculus & pierces the sup. medullary velum.

I.B: the trochlear n. supplies one extraocular muscle: the superior oblique m.



## \* Trigeminal nerve (5<sup>th</sup> cranial n.) :

104

It has 4 nuclei ; 3 sensory & 1 motor :

(1) Main Sensory Nucleus : lies in the middle part of the pons . It receives touch sensation from the face & head via the branches of the trigeminal n.

(2) Spinal nucleus : lies in the medulla & extends upwards to the pons & downwards to the spinal cord . It replaces the substantia gelatinosa of Rolandi of the spinal cord .

It receives pain & temperature sensations from the skin of the face & scalp .

(3) Mesencephalic nucleus : lies in the tegmentum of the midbrain at the level of the sup. & inf. colliculi .

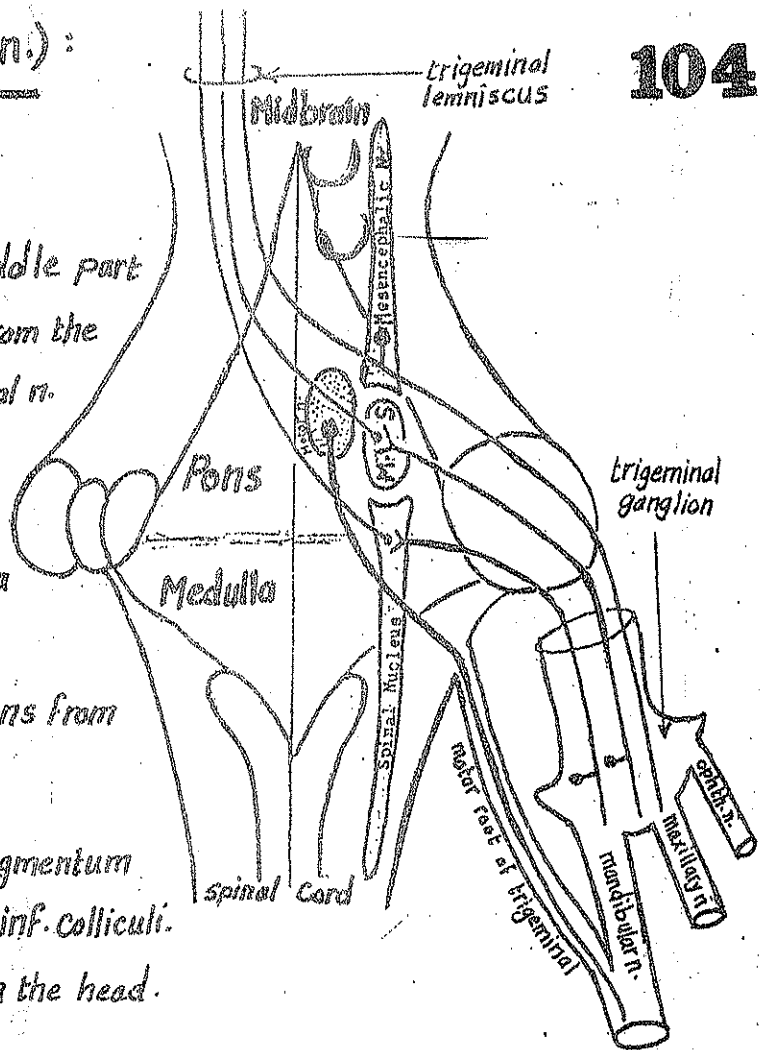
It receives proprioception sensation from the head .

(4) Motor nucleus of trigeminal n. : lies in the middle of the pons . It gives motor fibres

which forms the motor root of trigeminal n. that joins the mandibular n. to supply :

(a) the 4 muscles of mastication (b) 4 other mm. : mylohyoid, ant. belly of digastric, tensor palati & tensor tympani .

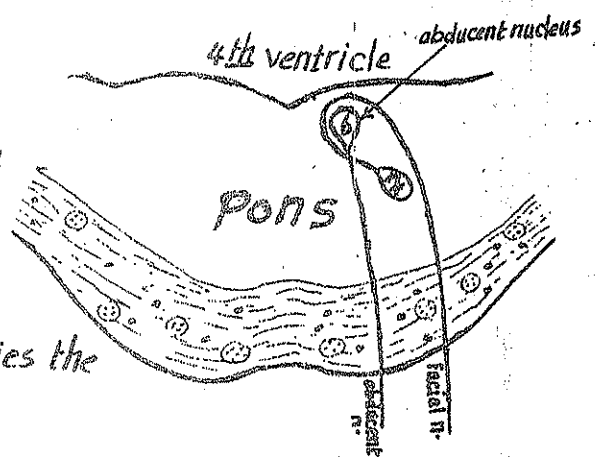
N.B : the 1<sup>st</sup> neurone for touch, pain & temperature is found in the trigeminal ganglion while the 1<sup>st</sup> neurone for proprioception is found in the mesencephalic nucleus .



## \* Abducent nerve (6<sup>th</sup> cranial n.) :

- its nucleus lies in the lower part of the pons close to the middle line & encircled by the facial nerve producing a swelling in the floor of 4<sup>th</sup> ventricle called the facial colliculus .

- the nucleus gives the abducent n. which supplies the lat. rectus m.



\* Facial nerve (7<sup>th</sup> cranial n.) :

It has 3 nuclei : 2 motor & 1 sensory :

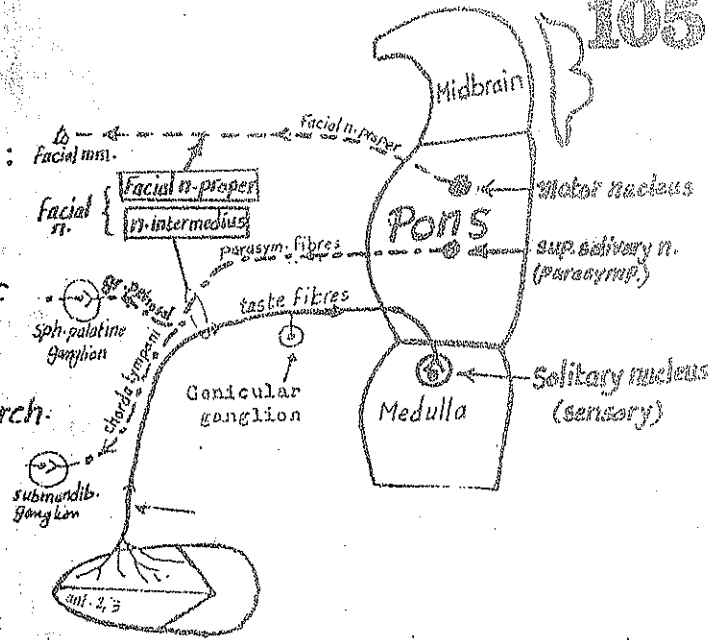
(1) facial motor nucleus : lies in the lower part of pons & gives rise to the fibres of the facial n. proper which supplies all muscles derived from the 2<sup>nd</sup> pharyngeal arch.

(2) Sup. salivary nucleus : lies in the pons & gives rise to secretomotor parasympathetic fibres which pass in the following branches :

(a) greater s. petrosal n. → relay in the sphenopalatine ganglion → postganglionic fibre supply the mucous glands of the palate, nose & nasopharynx.

(b) chorda tympani n. → relay in the submandib. ganglion → postganglionic fibres supply submandib. salivary gland & sublingual & G

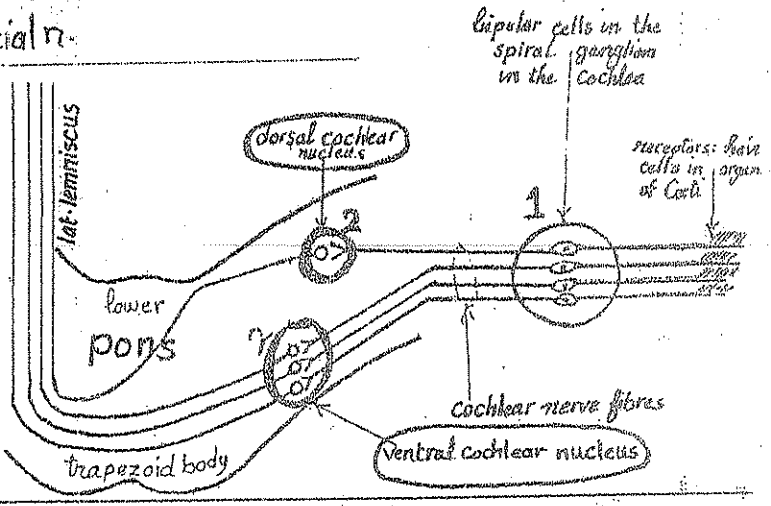
(3) Solitary nucleus : lies in the medulla. It receives taste sensations from the ant. 2/3 of tongue via the central processes of the cells of the geniculate ganglion of facial n.



N.B. fibres from the sup. salivary nucleus & solitary nucleus constitute the nervus intermedius component of the facial n.

\* Cochlear part of the 8<sup>th</sup> nerve :

- ends in 2 Cochlear nuclei : ventral & dorsal lying in the lower part of the pons & receive hearing impulses. (see Page 75)

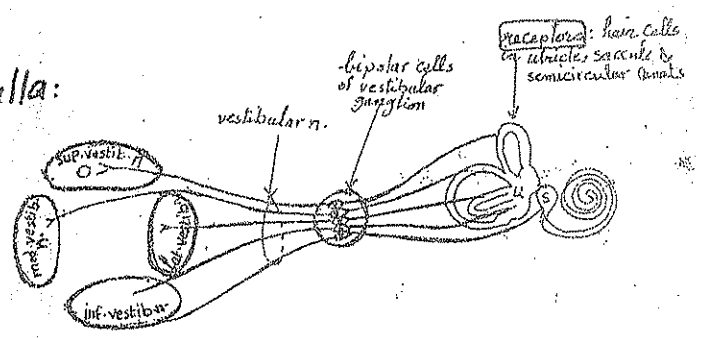


\* Vestibular part of the 8<sup>th</sup> nerve :

its fibres carry equilibrium impulses

& end in 4 nuclei lying in the pons & medulla :

- (1) sup. vestibular nucleus
  - (2) inf. " nucleus
  - (3) lat. " "
  - (4) med. " "
- see page 75



# \* The Glossopharyngeal nerve (9th n.):

It has 3 nuclei: 2 motor & 1 sensory

(1) The upper part of nucleus ambiguus (in the medulla):

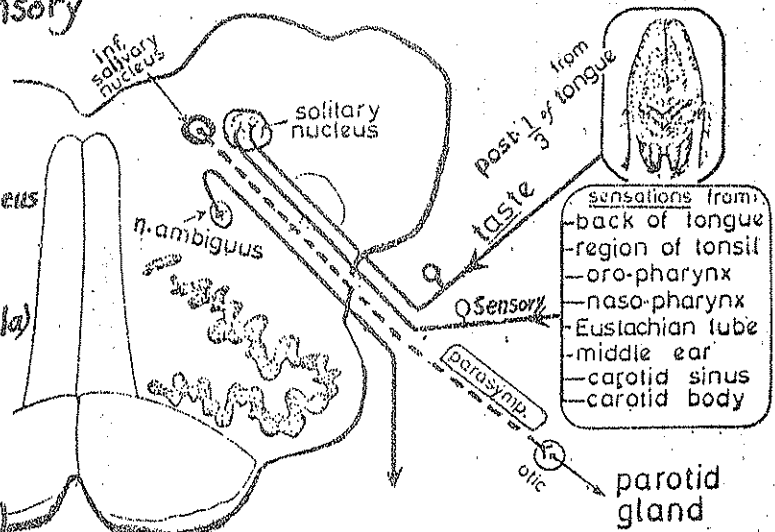
gives motor fibres to the stylopharyngeus muscle.

(2) The inf. salivary nucleus (in medulla)

gives parasympathetic fibres to the parotid gland.

(3) The Solitary nucleus (in medulla)

- receives taste sensation from post. 1/3 of tongue.
- receives general sensations from post. 1/3 of tongue, pharynx, tonsils, Eust. tube, Carotid sinus & body.



# \* The Vagus nerve (10th nerve)

Has 3 nuclei 2 motor & 1 sensory:

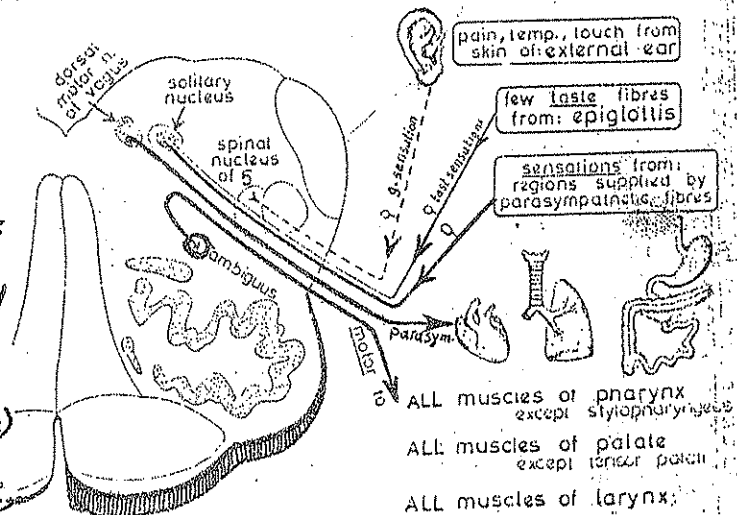
(1) Dorsal motor nucleus of Vagus in medulla:

gives parasympathetic fibres to the respiratory tract, digestive tract & the heart.

(2) main part of nucleus ambiguus (in medulla)

gives motor fibres to the muscles of the larynx, pharynx & palate.

(3) solitary nucleus: receives taste sensation from the epiglottis & general sensations from the areas supplied by the parasympathetic fibres.



# \* The Accessory nerve (11th nerve)

- its cranial part arises from the lower most part of the nucleus ambiguus. It contains motor fibres which join the vagus n. & distributed through its branches to the palate, larynx & pharynx.

- Its spinal part: arises from the A.H.Cs of the upper 5 or 6 cervical segments. Its fibres supply the sternomastoid & trapezius muscles.

\* The Hypoglossal nerve (12th: nerve): arises from the hypoglossal nucleus in the medulla (in the floor of the 4th ventricle). Its fibres are motor to all muscles of the tongue except palatoglossus.

